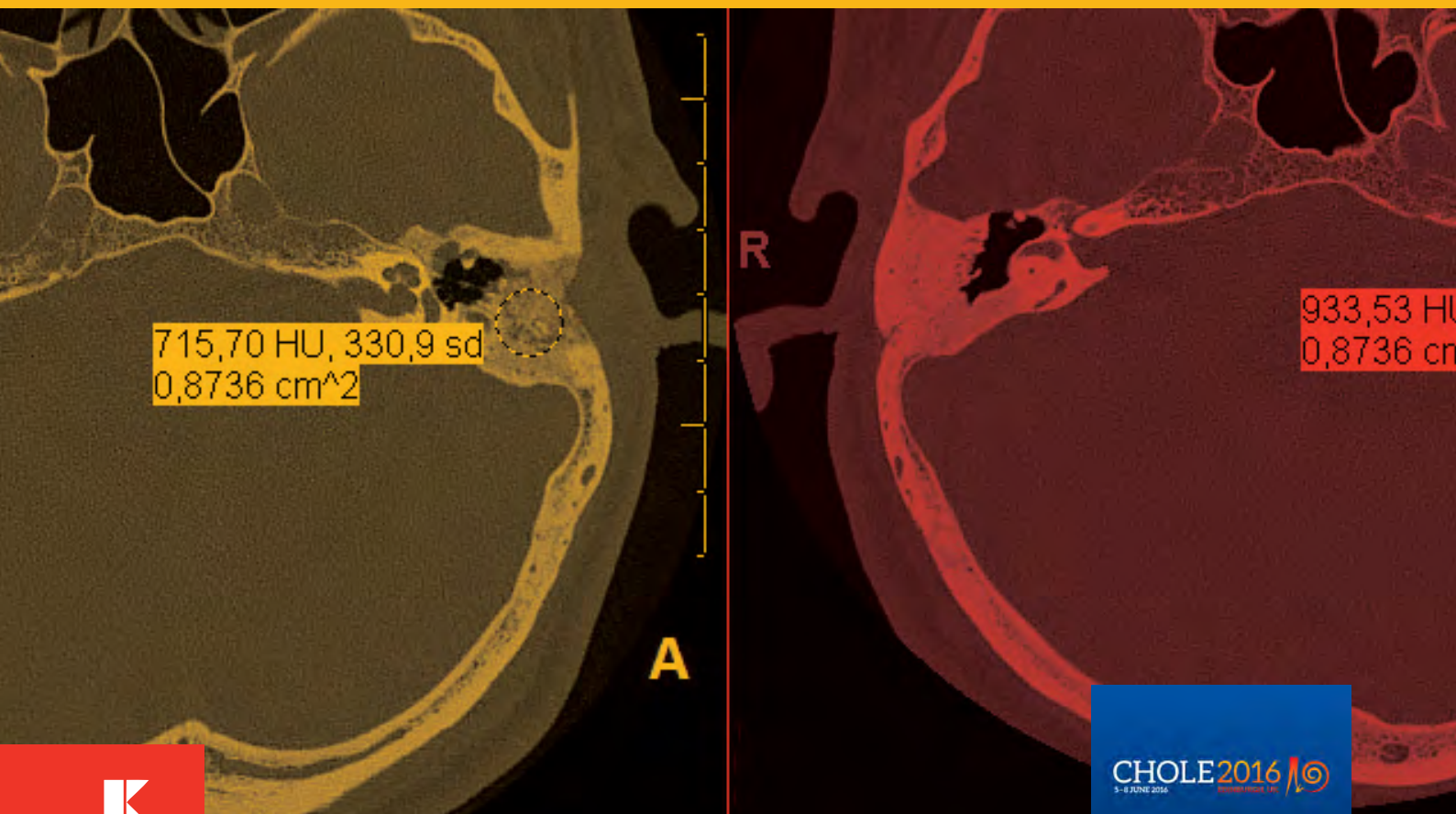


# Cholesteatoma and Ear Surgery

CHOLE2016

Edited by  
Matthew Yung



CHOLE2016  
5-8 JUNE 2016  
Hemel Hempstead, UK

## CHOLESTEATOMA AND EAR SURGERY – AN UPDATE 2017



# **CHOLESTEATOMA AND EAR SURGERY – AN UPDATE 2017**

edited by

Matthew Yung

Proceedings of the 10th International Conference  
on Cholesteatoma and Ear Surgery  
5-8 June 2016, Edinburgh, UK



**Kugler Publications/Amsterdam/The Netherlands**



ISBN 13: 978-90-6299-267-6

Distributors:

For the USA and Canada:

Princeton Selling Group

175 Strafford Ave.

Wayne, PA 19087-3318

U.S.A.

email: [psg@firstclassweb.com](mailto:psg@firstclassweb.com)

For all other countries:

Kugler Publications

P.O. Box 20538

1001 NM Amsterdam, The Netherlands

[info@kuglerpublications.com](mailto:info@kuglerpublications.com)

website: [www.kuglerpublications.com](http://www.kuglerpublications.com)

© 2017 Kugler Publications, Amsterdam, The Netherlands

All rights reserved. No part of this book may be translated or reproduced in any form by print, photoprint, microfilm, or any other means without prior written permission of the publisher. Kugler Publications is an imprint of SPB Academic Publishing bv, P.O. Box 20538, 1001 NM Amsterdam, The Netherlands

# TABLE OF CONTENTS

## **Preface**

*Matthew Yung* xi

## **The variable clinical presentation of tuberculosis otitis media and the importance of early detection**

*Generoso T. Abes, Franco Louie LB. Abes, Joselito C. Jamir* 1

## **Hearing loss and retraction pockets**

*Roberto Albera, Andrea Canale, Andrea Albera* 3

## **Dura involvement and lateral skull base reconstruction in cholesteatoma surgery: a retrospective study**

*A. Anagiotos, D. Schwarz, S. Shabli, A.O. Gostian, K.B. Hüttenbrink* 7

## **The role of the transotic approach in cases of petrous bone cholesteatoma**

*Miguel Aristegui, Ignacio Aristegui* 9

## **Subtotal petrosectomy for cochlear implantation in cases of chronic otitis media**

*Miguel Aristegui, Ignacio Aristegui, Gracia Aranguez* 13

## **Skull-base cholesteatoma management options: then and now**

*Mathieu Forgues, Moisés A. Arriaga* 17

## **Long-term management of cholesteatoma with labyrinthine destruction, skull base involvement, and intracranial extension**

*Christina C. Cobb, P. Cody Buchanan, Uresh Patel, Douglas D. Backous* 21

## **Endoscopic ear surgery: tips**

*M. Demir Bajin* 25

## **TB prototype : a perfect complement to traditional teaching of mastoidectomy**

*D. Bakhos, C. Dorbeau, C. Aussedat* 27

## **Definitions of disease in eustachian tuboplasty**

*Mahmood F. Bhutta* 31

## **Genetics of cholesteatoma**

*Mahmood F. Bhutta, Peter Prinsley, Carl Philpott, Barbara Jennings* 33

## **Mastoidectomy reconstruction with titanium sheeting**

*Bruce Black* 35

## **Keyhole cochlear implant surgery: adaptation for Med El Soundbridge and Bonebridge devices**

*Bruce Black* 39

<b>Prognostic factors in paediatric cochlear implantation: definition, location, evaluation</b> <i>Jane Black, Bruce Black</i>	43
<b>Integrating endoscopy into everyday otology practice</b> <i>Jose Carlos Casqueiro</i>	47
<b>Bone conduction implants in pediatric cholesteatoma management</b> <i>Stephen P. Cass, Gregory C. Allen, Kenny H. Chan</i>	51
<b>Managing cholesteatoma: Something old, something new, and something borrowed</b> <i>Sujana S. Chandrasekhar</i>	55
<b>Bone cements for mastoid/posterior canal wall reconstruction</b> <i>Sujana S. Chandrasekhar</i>	59
<b>Surfactant and Eustachian tube dysfunction/otitis media</b> <i>Sujana S. Chandrasekhar, Alan J. Mautone</i>	63
<b>Middle ear pressure maintenance: (1) A concert played by many instruments; (2) Pathology as compensation</b> <i>Udi Cinamon</i>	67
<b>Studies by nature of Eustachian tube dysfunction: a preliminary report</b> <i>Udi Cinamon, Hussein Amer, Avraham Lazary, Dov Albukrek, Tal Marom</i>	69
<b>Facial paralysis in chronic otitis media</b> <i>Vincent C. Cousins</i>	71
<b>Middle ear gas exchange problems in otitis media with effusion and acquired cholesteatoma</b> <i>Zsuzsanna Csakanyi, Gabor Katona</i>	75
<b>Current trends in managing complications of chronic otitis media with cholesteatoma</b> <i>Jyoti P. Dabholkar, Jaini Lodha, Nitish Virmani</i>	79
<b>The surgical management of temporal bone cholesteatoma involving the jugular foramen</b> <i>Chunfu Dai</i>	83
<b>Past, present and future treatment of biofilms in otitis media</b> <i>Mat Daniel</i>	87
<b>Hydroxyapatite cement for hearing reconstruction</b> <i>Stefan Delrue, Joost van Dinther, Andrzej Zarowski, Thomas Somers, Erwin Offeciers</i>	89
<b>3D-CT analysis of the FMT angle to the RW/OW after VSB surgery</b> <i>Katsumi Doi, Takeshi Fujita, Kazuya Saito, Kumi Kohama, Daisuke Nagatomi</i>	93

<b>Hacettepe cartilage slicer: a novel cartilage slicer and its performance tests</b> <i>Onur Ergun, Munir Demir Bajin, Mustafa Fevzi Sargon, Levent Sennaroglu</i>	95
<b>Mastoid obliteration with homologous bone graft</b> <i>Anna Carolina de Oliveira Fonseca, José Celso Rodrigues de Souza, Eloisa Maria Mello Santiago Gebrim, Luiz Augusto Ubirajara Santos, Ricardo Ferreira Bento</i>	99
<b>Cadaver dissection as a teaching tool in ear surgery</b> <i>V. Franco-Vidal</i>	103
<b>Ten-year outcomes with the shape memory Nitinol stapes prosthesis</b> <i>Rebecca L. Heywood, Mark E. Quick, Marcus D. Atlas</i>	105
<b>Removal of cholesteatoma matrix from inner ear fistula</b> <i>Harukazu Hiraumi</i>	109
<b>Which device – when and why?</b> <b>The controversial role of bone conduction hearing devices in the rehabilitation of unilateral sensorineural hearing loss</b> <i>W. Hodgetts, D.P. Morris, J. Ray, M.K.S. Hol</i>	113
<b>Turner syndrome: Translational research concerning ear and hearing. A summery from recent years</b> <i>Malou Hultcrantz</i>	121
<b>Predictive factors for recurrent cholesteatoma in children</b> <i>Adrian James</i>	127
<b>Tympanoplasty using medio-lateral graft for anterior or subtotal tympanic membrane perforation</b> <i>Timothy T. K. Jung</i>	133
<b>Overview of biofilms and otitis</b> <i>Romain Kania</i>	137
<b>Hearing reconstruction: how I do it. A step-by-step ossicular chain reconstruction</b> <i>Romain Kania, Benjamin Verillaud, Philippe Herman</i>	139
<b>Regulation of osteoclasts is required to maintain morphology and function of ossicles in middle ear; clinical implication of cholestatoma</b> <i>Sho Kanzaki, Kaoru Ogawa, Koichi Matsuo</i>	143
<b>Where is it safe to leave residual vestibular schwannoma during surgery?</b> <i>Anand V. Kasbekar, Guleed H Adan, Alaina Beacall, Ahmed M. Youssef, Catherine E. Gilkes, Tristram H. Lesser</i>	147
<b>Bony obliteration technique (BOT) surgery in paediatric cholesteatoma cases</b> <i>Gabor Katona</i>	151

<b>Endoscopic management of cholesteatoma with Khan's Endoholder</b> <i>Department Of Otorhinolaryngology, M.I.M.E.R. Medical College, Pune, India</i>	153
<b>Current trends of cholesteatoma surgery in Japan: results from the Japan Otological Society Registry using 2015 JOS Staging and Classification System</b> <i>Manabu Komori, Tetsuya Tono, Masafumi Sakagami, Hiromi Kojima, Naohito Hato, Yutaka Yamamoto, Keiji Matsuda, Yuka Morita, Sho Hashimoto</i>	157
<b>Mastoid obliteration six-years follow-up results. European trend, local peculiarities</b> <i>Sergey Kosyakov, Ekaterina Pchelenok</i>	159
<b>Management of the facial nerve in cholesteatoma surgery: multidisciplinary approach in a Facial Paralysis Unit</b> <i>Luis Lassaletta, Julio Peñarrocha, Teresa González, Susana Moraleda, Javier Gavilán</i>	163
<b>The keratinocyte in health and disease</b> <i>Irene Leigh</i>	167
<b>Introducing the 'ChOLE' Classification</b> <i>Thomas E Linder, Shankar Shah, Christof Röösl, Alex M Huber, Nue Milici</i>	171
<b>DWI imaging in extensive petrous bone cholesteatoma</b> <i>Simon K.W. Lloyd, Hannah North, Andrew T. King, Scott Rutherford, Charlotte Hammerbeck-Ward, Simon Freeman</i>	177
<b>Encephalocele and brain herniation from previous mastoid surgery</b> <i>Simon K.W. Lloyd, Hannah North, Andrew T. King, Scott Rutherford, Charlotte Hammerbeck-Ward, Simon Freeman</i>	179
<b>Practicality analysis of JOS staging system for congenital cholesteatoma: Japan Multicenter study (2009-2010)</b> <i>Yuka Morita, Tetsuya Tono, Yutaka Yamamoto, Hiromi Kojima, Masafumi Sakagami, Yasuo Mishiro, Taeko Okuno, Yasuyuki Hinohira, Keiji Matsuda, Sho Hashimoto</i>	181
<b>Surgery of cholesteatoma in pediatric age: assessment of combined micro-endoscope approach</b> <i>N. Nassif, T. Sorrentino, S. Zorzi, L.O. Redaelli De Zinis</i>	183
<b>Cochlear implantation in chronic otitis media</b> <i>Abdullah Dalgic, Tolgahan Catli, Deniz T. Edizer, Gorkem Atsal, Levent Olgun</i>	187
<b>Approach to petrous bone cholesteatoma</b> <i>Tolgahan Catli, Deniz Tuna Edizer, Abdullah Dalgic, Cagri Celik, Levent Olgun</i>	191
<b>Active middle ear implants in chronic otitis media</b> <i>Levent Olgun, Deniz T. Edizer, Abdullah Dalgic, Tolgahan Catli, Cagri Celik</i>	193
<b>Adhesive otitis media and ossiculoplasty</b> <i>Kadir Serkan Orhan, Beldan Polat, Mehmet Çelik, Hakan Avcı, İbrahim Yağcı, Yahya Güldiken</i>	197

<b>The COMQ-12 and COMBI questionnaires for the assessment of cholesteatoma surgery outcome</b> <i>John S. Phillips</i>	201
<b>Diagnosis, classification and surgical management of petrous bone cholesteatomas: Review of 200 consecutive patients</b> <i>Sampath Chandra Prasad, Gianluca Piras, Enrico Piccirillo, Mario Sanna</i>	205
<b>Subtotal petrosectomy – Surgical technique, indications, outcomes and comprehensive review of literature</b> <i>Sampath Chandra Prasad, Valeria Roustan, Enrico Piccirillo, Mario Sanna</i>	209
<b>Beyond middle ear</b> <i>Livio Presutti, Marco Bonali</i>	215
<b>Retraction pocketS – endoscopic approach</b> <i>Livio Presutti, Marco Bonali</i>	219
<b>The genetics of cholesteatoma project</b> <i>Peter Prinsley, Carl Philpott, Barbara Jennings, Mahmood Bhutta</i>	223
<b>Surgical technique for BONEBRIDGE implantation in young children with previous mastoidectomy due to chronic suppurative otitis media</b> <i>Ángel Ramos-Macias, Daniel Perez-Plasencia, Elena Muñoz Pascual, Marta Bastarrica Martí, Angel Osorio Acosta</i>	227
<b>Canal-wall-down mastoidectomy with and without autologous bone obliteration: A comparison of results in adults</b> <i>Luca O. Redaelli de Zinis, Francesco Mancini, Tommaso Sorrentino, Daniela Tonni</i>	233
<b>First experience with the ChOLE classification in combination with a QoL questionnaire</b> <i>Christof Rösli, David Bächinger, Thomas E Linder, Alex M Huber</i>	237
<b>Pathogenesis of cholesteatoma: Changing concepts</b> <i>Letícia P.S. Rosito, M.N.L. Silva, I. Canali, F.A. Selaimen, S.S. Costa</i>	241
<b>Cholesteatoma in children – the profile of paediatric and adult cholesteatoma presenting in a secondary and tertiary care setting</b> <i>Robert Nash, Shakeel R. Saeed</i>	245
<b>Assessment of vestibular function in patients with chronic middle ear dysfunction using vhit and vemp testing</b> <i>J.S. Sandhu, M. Yung, J. Parker-George, B. Kearney, J. Ray</i>	251
<b>CT vs CT-MRI Fusion imaging in preoperative mastoid assessment for cholesteatoma: Implications for endoscopic ear surgery</b> <i>Alexander J. Saxby, Laughlin Dawes, Christina Cheng, Samantha Wills, Nicholas Jufas, Jonathan Kong, Nirmal Patel, Simon Greenberg</i>	255

<b>Primary obliteration of the mastoid cavity in cholesteatoma surgery</b> <i>Lars P. Schousboe</i>	261
<b>Cholesteatoma in the developing world, what do we know, and what can we do?</b> <i>Michael C.F. Smith</i>	265
<b>MRI evaluation of endolymphatic hydrops for middle ear surgery</b> <i>Michihiko Sone, Tadao Yoshida, Satofumi Sugimoto</i>	271
<b>Alterations of MYC locus in cholesteatoma as an analogy to neoplastic transformation</b> <i>Krzysztof Szyfter, Małgorzata Jarmuż-Szymczak, Wojciech Gawęcki, Magdalena Kostrzevska-Poczekaj, Witold Szyfter</i>	273
<b>Open mastoidectomy and soft-wall reconstruction</b> <i>Haruo Takahashi</i>	277
<b>Clinical implication of the middle-ear pressure-regulation functions</b> <i>Haruo Takahashi</i>	281
<b>Clinical incidence and management of otitis media with effusion in Vietnamese children</b> <i>Tran Le Thuy, Huynh Ba Tan</i>	285
<b>Introduction of the Japan Otological Society work on classification and staging of cholesteatoma: the Nationwide Survey of cholesteatoma surgical cases in Japan</b> <i>Tetsuya Tono, Masafumi Sakagami, Hiromi Kojima, Yutaka Yamamoto, Keiji Matsuda, Manabu Komori, Naohito Hato, Yuka Morita, Sho Hashimoto; The Committee on Nomenclature of the Japan Otological Society</i>	293
<b>Poverty and ethnicity in the aetiology of cholesteatoma; Preliminary data from New Zealand's North Central Region</b> <i>S.C. Toynton, D. Schreiber</i>	297
<b>Epidemiology of pediatric otitis media in Taiwan</b> <i>Mao-Che Wang</i>	301
<b>Practicality analysis of JOS staging system for cholesteatoma secondary to a pars tensa perforation: Japan Multicenter Study (2009-2010)</b> <i>Yutaka Yamamoto, Tustuya Tono, Hiromi Kojima, Yuka Morita, Masafumi Sakagami, Yasuo Mishiro, Taeko Okuno, Yasuyuki Hinohira, Keiji Matsuda, Sho Hashimoto</i>	305
<b>Inflammatory, invasive and neoplastic features of primary and secondary cholesteatomas: Immunohistochemical and histological findings</b> <i>Nadir Yildirim, Ayşe Nur Deger, Onur Erdogan, Semra Külekci</i>	307
<b>Simple underlay myringoplasty</b> <i>Yu Yuasa</i>	315

## PREFACE

It was a great privilege and honour for me and my deputy chairman Professor Chris Raine to host the 10<sup>th</sup> International Conference on Cholesteatoma and Ear Surgery (Chole2016) in Edinburgh, Scotland. The Council of the British Society of Otolaryngology has helped me tremendously in the preparation of this conference. Over 1000 delegates from 54 countries attended Chole2016 on 5-8 June 2016.

The scientific programme included 12 keynote lectures on the basic science of chronic ear diseases; 23 national symposium; 41 round tables; two live temporal bone dissections; 14 video instructional sessions; 18 free paper sessions and poster presentations. I sincerely thank all the faculties who contributed to the scientific programs and also the delegates who provided a lively discussion during the scientific sessions. It was the exchange of knowledge between the speakers and the delegates that makes the conference so worthwhile to me.



The aim of Chole2016 was to:

1. Bring basic science on chronic ear diseases to the clinicians.
2. Achieve consensus in definitions, classification and staging of cholesteatoma.

The first aim was fulfilled by a scientific programme that focused keynotes sessions on basic sciences. These proved delegates with a fascinating insight into the cellular biology, the role of chronic inflammation, genetic advances, middle ear mechanics/physiology, bacteriology, stem cell research and novel imaging technologies in the context of cholesteatoma. At Chole2016, the joint EAONO/JOS consensus document was presented to the international scientific community for the first time. It led to a lively and productive discussion. A consensus document on classification and staging of cholesteatoma has since been produced.

The Proceedings of Chole2016 is available in paper book as well as a PDF (enhanced PDF with links) and EPUB (optimized for tablets). The electronic versions are freely downloadable for all. If you want a copy (paper book) Kugler Publications can also provide POD (Publishing on Demand) copies for a reasonable price.

Finally, I am very much looking forward to seeing all of you at the 11<sup>th</sup> Conference in Shanghai in 2020!

Matthew Yung





# THE VARIABLE CLINICAL PRESENTATION OF TUBERCULOSIS OTITIS MEDIA AND THE IMPORTANCE OF EARLY DETECTION<sup>1</sup>

Generoso T. Abes<sup>1,2,3</sup>, Franco Louie LB. Abes<sup>1,2,3</sup>, Joselito C. Jamir<sup>1</sup>

<sup>1</sup>Philippine National Ear Institute-National Institutes of Health –University of the Philippines-Manila;

<sup>2</sup>Department of Otorhinolaryngology - Manila Doctors Hospital; <sup>3</sup>Department of Otorhinolaryngology – University of Santo Tomas Faculty of Medicine and Surgery

Tuberculosis otitis media (TBOM) is a rare cause of otitis media caused by the bacteria *Mycobacterium tuberculosis*.<sup>1</sup> Among developed countries, sporadic cases of TBOM have been seen among migrant populations and among immunocompromised hosts.<sup>2</sup> The advent of new diagnostic tests, such as the polymerase chain reaction (PCR) test for tuberculosis (TB),<sup>3</sup> may be able to enhance the detection of disease among otitis media cases.

Among our cases found in the Philippines, which is a developing country in the western pacific region, we have noted that TBOM detection is dependent on the detection of the TB bacilli and a high index of suspicion for TB.<sup>4</sup> In our review of cases from 2004-2009, we were able to diagnose 13 cases of TBOM among 12 patients (six males:six females). There was one patient with bilateral ear involvement and four of the 12 patients were health care institution workers. Hearing loss (11/12) and otorrhea (5/12) were the most common associated symptoms among the TBOM patients. Three patients had previously undergone medical treatment for pulmonary tuberculosis although none of the TBOM patients were clinically diagnosed with the human immunodeficiency virus (HIV). The thirteen TBOM ears presented with different otoscopic findings wherein eight had intact tympanic membranes and five showed different degrees of tympanic membrane perforation. Among the eight ears with intact tympanic

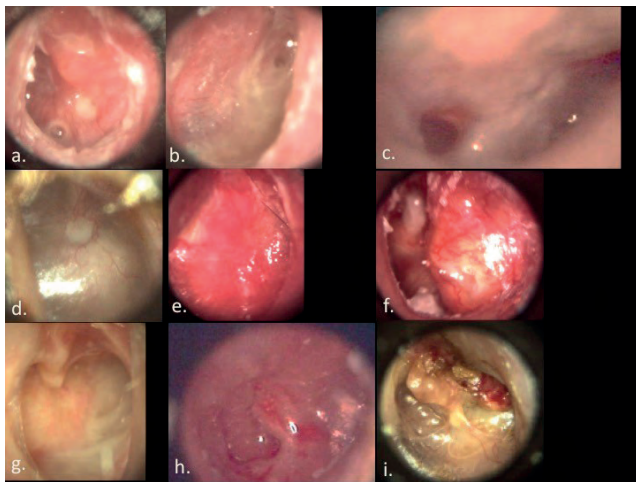


Fig. 1. The various otoscopic presentations seen among ears diagnosed with TBOM: (a) Acute suppurative otitis media-like with multiple perforations; (b) Acute suppurative otitis media-like with a single perforation; (c) Chronic otitis media-like with multiple perforations; (d) Intact tympanic membrane with middle ear effusion; (e) Intact thickened tympanic membrane; (f) Intact tympanic membrane with middle ear mass; (g) Chronic otitis media-like with single perforation and otorrhea; (h) Chronic otitis media-like with granulation; (i) Chronic otitis media-like with cholesteatoma. (Pictures from authors' personal files.)

membranes, four had middle ear effusions and another four presented with a mass-like lesion on the middle ear. On the other hand, of the five TBOM ears with perforated tympanic membranes, one presented with multiple perforations, two had single perforations with granulomas in the middle ear, and another two had single perforations that did not have middle granulomas (Fig. 1). Among the 13 ears with TBOM, 12 were diagnosed by means of acquiring middle ear specimens while one was diagnosed via specimen acquired from the nasopharynx. The majority of the specimens showed positive results when they were subjected to the PCR test for TB and/or when they were analyzed for biopsy. It was interesting to note that the majority of the patients showed positive results on purified protein derivative skin test, while half of the patients revealed undiscovered chest findings on X-ray. On temporal bone CT-scan, it was noted that the majority of TBOM ears had soft tissue densities occupying the middle ear and mastoid cavity, but had preserved mastoid architecture and did not have any scutum blunting as well.

We noted that among the diagnostic tests for TBOM, the

Correspondence: c/o Franco Louie LB. Abes MD, Department of Otorhinolaryngology – Manila Doctors Hospital – 667 United Nations Avenue Manila 1000, Philippines.  
E-mail: franco.abes@uclmail.net

*Cholesteatoma and Ear Surgery – An Update 2017, pp. 1 -2*

*Edited by Matthew Yung*

*2017 © Kugler Publications, Amsterdam, The Netherlands*

use of the PCR test and the analysis of biopsy results were the most useful in diagnosing TBOM. After surgical management, all of the patients diagnosed with TBOM underwent anti-Koch's medical therapy. Most of the TBOM patients went took a four-drug regimen using isoniazid, rifampicin, pyrazinamide and ethambutol for the first two months, which was then followed by a three-drug regimen using isoniazid, rifampicin and pyrazinamide for the next seven months.

All of the patients who underwent treatment and diagnosis had either partial or complete resolution of the densities found in their middle ear and/or mastoid cavity. Significant hearing improvements among the TBOM patients were noted after treatment. The varied clinical findings found in TBOM make it difficult to distinguish from non-tuberculous otitis media cases.

## References

1. Ramages LJ, Gertler R. Aural tuberculosis: a series of 25 patients. *J Laryngol Otol* 1985;99(11):1073-1080.
2. Pitchenik AE, Cole C, Russell BW, et al. Tuberculosis, atypical mycobacteriosis, and the acquired immunodeficiency syndrome among Haitian and non-Haitian patients in south Florida. *Ann Intern Med* 1984;101(5):641-645.
3. Brisson-Noel A, Aznar C, Chureau C, et al. Diagnosis of tuberculosis by DNA amplification in clinical practice evaluation. *Lancet* 1991;338(8763):364-366.
4. Abes GT, Abes FL, Jamir JC. The variable clinical presentation of tuberculosis otitis media and the importance of early detection. *Otol Neurotol* 2011;32:539-543.

# HEARING LOSS AND RETRACTION POCKETS

Roberto Albera, Andrea Canale, Andrea Albera

*Surgical Science Department, University of Turin, Italy*

## Introduction

The air-bone gap (ABG) in patients affected by retraction pocket (RP) can be related both to drum abnormalities and to ossicular chain suffering, frequently found in this pathology.<sup>1</sup> However, it is widely known that the adhesion between retracted drum and ossicular chain often allows an adequate sound transmission, replacing the damaged ossicles; therefore pure-tone audiometry (PTA) does not always show the real state of the middle-ear transmission system.<sup>2</sup> Moreover, these patients can also show signs of inner ear damage with sensorineural hearing loss<sup>3</sup> and imaging is often inadequate to define ossicle condition. However, knowing the functional status of the affected ear could be crucial to plan surgery.

The aim of this study was to describe the ossicular chain defects in chronic otitis with RP and to correlate them and their influence on hearing function.

## Materials and Methods

The study group was composed of 68 patients affected by RP without cholesteatoma and submitted to surgery in the period 2004-2014. Subjects who had already been operated on before at the same ear were excluded by the study.

Indication to surgery was done on the basis of:

- High risk of cholesteatoma (evolution of the RP);
- Relevant ABG, whatever the condition of the ossicular chain.

Age ranged from six to 76 years (mean age 32); 38 (56%) were males and 30 (44%) females. The ear evaluated was the right in 28 cases (41%) and the left in 40 cases (59%).

In order to gain a uniform evaluation of data we have admitted only subjects operated on by the same surgeon (RA).

The day before surgery, each subject underwent an otologic evaluation based on otoscopy, micro-otoscopy and pure-tone audiometry (PTA) carried out in a sound proof chamber at the frequency range 0.25-8 kHz. Data are expressed as mean threshold at 0.5-1-2-4 kHz. In each case, a CT scan was requested at the diagnosis.

During surgery we carefully evaluated the drum abnormalities and the ossicular chain status.

The statistical evaluation of data was carried out by means of SPSS software and a p-level of 0.05 was considered to be the limit of significance.

Correspondence: Roberto Albera, Professore Ordinario in Otorinolaringoiatria Dipartimento di Scienze Chirurgiche Università degli Studi di Torino v. Genova, 3, 10126 Torino, Italia.  
E-mail: roberto.albera@unito.it

*Cholesteatoma and Ear Surgery – An Update 2017, pp. 3 -6*  
*Edited by Matthew Yung*  
*2017 © Kugler Publications, Amsterdam, The Netherlands*

## Results

The site of the RP was at the posterior quadrants of the drum in 49 cases (72%) and at the pars flaccida in 11 cases (16%); in eight cases (12%) the drum was atelectasic.

In the overall sample mean air conduction (AC) PTA threshold was 42 dB (standard deviation 16), mean bone conduction (BC) 18 dB (11) and mean ABG 25 dB (12).

Ossicular chain defects were evidenced in 32 patients (47%). In Table 1, the distribution of chain defects is reported. The incus was the more-frequently involved ossicle (34 cases – 89%), while other kinds of ossicular chain lesions were only occasionally found.

*Table 1.* Distribution of ossicle modifications found in the 32 cases in which the the chain was found lesioned by the RP.

<b>Bone</b>	<b>No. of cases</b>	<b>%</b>
Incus	26	38
Stapes	2	3
Malleus + Incus	1	2
Malleus + Incus + Stapes	3	4
Incus + stapes	4	6

The relationship between drum modification and ossicular chain abnormalities is reported in Table 2. There is no difference of ossicular chain suffering in relationship to the site of the RP.

*Table 2.* Relationship between the site of retraction and ossicular chain status. Differences are not significant at the chi-square test ( $p > 0.05$ ).

	<b>Normal</b>	<b>Incus</b>	<b>All the other conditions</b>
Atelectasic (8 cases)	62%	25%	13%
Pars flaccida (11 cases)	64%	18%	18%
Posterior quadrants (49 cases)	47%	38%	12%

The relation between the ABG and the ossicular chain status is reported in Table 3. In case of ossicular chain atrophy, hearing loss is significantly worse ( $p < 0.005$ ); however, in absence of chain defect the mean ABG is 21 dB, *i.e.*, two thirds of the entire mean ABG of the sample.

The site of the RP is not related with the degree of the ABG (Table 4).

Hearing loss was not related to age ( $p > 0.05$  at the Pearson's test).

*Table 3.* Mean AB gap in relationship to the ossicular chain condition. ABG is significantly higher in presence of ossicular lesion ( $p < 0.05$ ).

<b>Ossicular chain condition</b>	<b>AB Gap</b>
Normal (36 cases)	21 (15)
Ossicular chain atrophy (32 cases)	28 (9)

*Table 4.* AB gap in relationship with the site of RP. Differences are not significant at the Student's t test ( $p > 0.05$ ).

	<b>AB Gap</b>
Atelectasic (8 cases)	26 (9)
Pars flaccida (11 cases)	25 (13)
Posterior quadrants (49 cases)	24 (12)

## Discussion

Ossicular chain suffering is frequently found in cases of otitis media, above all in presence of cholesteatoma. In RP, the cause of bone resorption is principally a modification of blood support secondary to skin adhesion.<sup>4</sup>

The ABG in patients affected by RP is principally consequent to tympanic abnormalities and ossicular chain lesions. In our sample, chain defects were found in about 50% of cases; this value is between the 78% found in cholesteatoma<sup>5</sup> and 7% found in simply tympanic perforations,<sup>6</sup> suggesting a less necrotizing effect in RP than in cholesteatoma.

The kind of ossicular lesion is similar in all pathologies and the more frequent site of lesion is the long process of the incus;<sup>5,6</sup> this pattern of lesion has been found even in our sample limited to RP cases. The presence and the kind of ossicular chain defect does not seem to be related with the site of the RP.

In presence of ossicular chain atrophy, the hearing loss in our sample is significantly greater than in absence of chain interruption, therefore a larger ABG could preoperatively suggest a chain necrosis. However, even in absence of ossicular lesions hearing loss is relevant in RP, representing about two thirds of the entire ABG; this suggests that, even if an ossicular damage causes a greater ABG, the principal cause of conductive deficit is the drum abnormality.

This retrospective evaluation is based on a casuistry composed by patients submitted to surgery only, therefore it is representative of the chain lesions found in worst cases and cannot be considered as the expression of the effect of RP in all cases. In the majority of cases of RP, above all in cases with slight hearing loss or without risk of cholesteatoma, we suggest a follow-up and it is presumable that in these cases the incidence of chain suffering should be less.<sup>7</sup>

## References

1. Tos M. Pathology of the ossicular chain in various chronic middle ear diseases. *J Laryngol* 1979;93:769-780.
2. Carrillo RJ, Yang NW, Abes GT. Probabilities of ossicular discontinuity in chronic suppurative otitis media using pure-tone audiometry. *Otol Neurotol* 2007;28:103-107.
3. Cureoglu S, Schachern PA, Paparella MM, Lindgren BR. Cochlear changes in chronic otitis media. *Laryngoscope* 2004;114(4):622-626.
4. Juhn SK, Jung MK, Hoffman MD, et al. The role of inflammatory mediators in the pathogenesis of otitis media and sequelae. *Clin Exp Otorhinolaryngol* 2008;1(3):117-138.
5. Albera R, Canale A, Piumetto E, Lacilla M, Dagna F. Ossicular chain lesions in cholesteatoma. *Acta Otorhinol Ital* 2012;32:309-313.
6. Albera R, Dagna F, Filippini C, Albera A, Canale A. Ossicular chain lesions in tympanic perforations and chronic otitis media without cholesteatoma. *J Int Adv Otol* 2015;11:143-146.
7. Jeng FC, Tsai MH, Brown CJ. Relationship of preoperative findings and ossicular discontinuity in chronic otitis media. *Otol Neurotol* 2003;24:29-32.



# DURA INVOLVEMENT AND LATERAL SKULL BASE RECONSTRUCTION IN CHOLESTEATOMA SURGERY: A RETROSPECTIVE STUDY

A. Anagiotos<sup>1,2</sup>, D. Schwarz<sup>1</sup>, S. Shabli<sup>1</sup>, A.O. Gostian<sup>1</sup>, K.B. Hüttenbrink<sup>1</sup>

<sup>1</sup>Department of Otorhinolaryngology, Head and Neck Surgery, University of Cologne, Germany; <sup>2</sup>ENT Department, Nicosia General Hospital & Larnaca General Hospital, Cyprus

## Introduction

Due to its anatomical proximity to the tympanic cavity and the mastoid cells, the dura of the middle cranial fossa is occasionally involved in middle ear and mastoid surgery. Cholesteatoma of the middle ear may cause multiple complications because of its destructive properties. This study investigates the frequency of complications that involve the dura during cholesteatoma surgery in children and adult population.

## Methods

A retrospective chart review of cholesteatoma surgeries over a twelve-year period (January 2004-December 2015) at an academic tertiary care center was performed. Any kind of dura involvement, as well as the reconstruction techniques and long-term complications were documented.

## Results

From 1291 cholesteatoma surgeries performed in the examined time period, a total of 84 patients (6.5%) were identified with any kind of dura involvement intraoperatively (mean age 47.2 years | range 5-86 years, gender distribution 63% male and 37% female). In the majority of the cases (79.8%, 67 of 84) the bone to the middle cranial fossa was missing and the otherwise intact dura was exposed. In six cases (7.1%, 6 of 84) the dura was additionally damaged due to the cholesteatoma with detectable CSF leakage intraoperatively. Meningoceles were present in another six cases (7.1%, 6 of 84). In five patients (5.9%, 5 of 84) an iatrogenic exposure of the dura without CSF leakage during cholesteatoma surgery was reported. Reconstruction of the bone defect was performed using conchal cartilage (25.0%, 21 of 84), polydioxanone (PDS)-foil (ETHICON, Somerville, USA, 11.9%, 10 of 84) and bone pâté (9.5%, 8 of 84). In 15 cases (17.9%, 15 of 84) a combination of different materials – such as bone pâté, fibrin glue (ETHICON, Somerville, USA) and cartilage – was used. Regarding the bone defects with an exposed dura found during cholesteatoma surgery, the size was often smaller than approximately 1 cm<sup>2</sup> with no signs of herniation so that the surgeon could forgo to close the bone defect in 30 cases (35.7%, 30 of 84). In one case of petrous apex cholesteatoma with erosion of the cochlea and inner ear canal revision surgery was required due to persistent CSF leakage. In a follow-up time period of 19.3 months no patient suffers from long-term complications relevant to the dura involvement.

Correspondence: Andreas Anagiotos, MD, Nicosia General Hospital, Nicosia-Limassol Old Road, 2029, Nicosia, Cyprus  
E-mail: andreas.anagiotos@gmail.com

*Cholesteatoma and Ear Surgery – An Update 2017, pp. 7-8*  
*Edited by Matthew Yung*  
2017 © Kugler Publications, Amsterdam, The Netherlands



## Conclusions

Defects of the lateral skull base during cholesteatoma surgery are mostly characterized by an uncomplicated exposure of the intact dura. Severe complications with defects of the dura and consecutive CSF leakage or meningocele are rare but require meticulous surgical treatment. Skull base reconstruction is performed preferably with cartilage that allows for safe and stable reconstruction.

# THE ROLE OF THE TRANSOTIC APPROACH IN CASES OF PETROUS BONE CHOLESTEATOMA

Miguel Aristegui<sup>1</sup>, Ignacio Aristegui<sup>2</sup>

<sup>1</sup>ENT Department, Hospital General Universitario Gregorio Marañón, Madrid, Spain; <sup>2</sup>ENT Department, Hospital Universitario de Móstoles, Madrid, Spain

## 1. Introduction

Petrous bone cholesteatoma is a life-threatening condition which requires prompt intervention. Hearing preservation or restoration, in those cases in which is still present, is difficult to achieve. More than half of these patients will have preoperative facial nerve paralysis. The transotic approach, a translabyrinthine approach which leaves the facial nerve in place, provides an excellent option for facial nerve preservation in cases of petrous bone cholesteatoma with anatomically connected facial nerve.

## 2. Materials and Methods

A retrospective review of the cases of petrous bone cholesteatoma operated by the senior author is included. Demographic data, classification according to a Modified Sanna System<sup>1</sup> (Table 1), preoperative hearing and facial nerve function and complications are shown.

Table 1. Modified Sanna Classification system for petrous bone cholesteatoma.

Type	Extension
Supralabyrinthine	Apex
Infralabyrinthine	Clivus
Retrolabyrinthine	Sphenoid sinus
Massive Labyrinthine	Neck
Infralabyrinthine Apical	Parapharyngeal
Apical	Intradural

## 3. Results

Sixty-nine cases from 67 patients were managed with 72 surgeries.

Sex distribution showed 40 males and 27 females. Age ranged from six to 73 years with a mean of 45 years. Thirty-nine cases were right and 30 cases left. Two cases were bilateral. Follow-up ranged from three months to 20 years with a mean follow-up of more than ten years.

The distribution of cases according to a modified Sanna Classification is shown in Table 2. The most common type was the supralabyrinthine. Extensions of the disease to the apical compartment, to the clivus, to the neck or to the intradural space were present.

Correspondence: Miguel Aristegui, Avenida de Burgos, 9B, 28036 Madrid, Spain.)  
E-mail: miguelaristegui@gmail.com

*Cholesteatoma and Ear Surgery – An Update 2017, pp. 9-12*  
*Edited by Matthew Yung*  
2017 © Kugler Publications, Amsterdam, The Netherlands

Table 2. Distribution of the 69 cases of the series according to the Modified Sanna Classification.

Type	n	Extension	n
Supralabyrinthine	26	Apex	7
Infralabyrinthine	7	Clivus	3
Retrolabyrinthine	7	Sphenoid sinus	0
Massive Labyrinthine	14	Neck	2
Infralabyrinthine Apical	10	Parapharyngeal	0
Apical	5	Intradural	1

Table 3. Preoperative and postoperative hearing function.

HEARING n=69	Preoperative	Postoperative
Normal	3	3
Mixed Hearing Loss	30	17
Severe Mixed HL	16	11
Sensorineural HL	4	1
Anacusis	16	37

Table 4. Preoperative and postoperative facial nerve function.

Facial House&Brackmman	Preoperative	Postoperative
I	34	34
II	4	3
III	12	14
IV	8	4
V	3	1
VI	8	13

Table 5. Approaches used in the series.

N = 72	
Open technique with partial obliteration	9
Open translabyrinthine	6
Subtotal petrosectomy	14
Modified translabyrinthine approach	14
Transotic approach	14
Transcochlear approach	7
Retrolabyrinthine approach	5
Transyugular transcervical	3

Preoperative and postoperative hearing function, are shown in Table 3. Three of the patients of the series were rehabilitated with a cochlear implant with good outcomes. Preoperative and postoperative facial nerve function, are shown in Table 4. The different approaches used in this series are shown in Table 5. There was no mortality or meningitis in the series. One case of CSF leak was solved conservatively. There were two patients with residuals. One of them required two interventions to finally totally remove the disease. One patient had lower cranial nerve and hypoglossal nerve dysfunction due to a transjugular approach required to remove cholesteatoma in the lower clivus. There was one case of wound infection. No other complications were present.

#### 4. Discussion

Petrous bone cholesteatomas include those cases of congenital or acquired type that extend to the petrous portion of the temporal bone and require management of severely involved otic capsule, severe facial nerve involvement, meningeal, vein drainage or carotid involvement or who extend deeply in the petrous portion of the temporal bone.<sup>2</sup>

Hearing restoration is uncommon in patients with petrous bone cholesteatoma. In fact more than 50% of this patients will end up with total hearing loss. Some of them may be rehabilitated if indicated with the use of a cochlear implant (Fig. 1). Hearing loss is in most of the cases unavoidable if total resection is required. We can find patients with cholesteatoma inside the cochlea or the vestibule and with residual hearing. In other cases, posterior or anterior labyrinthectomies are required to gain access to the involved area. The retrolabyrinthine type is among those cases in which hearing preservation is feasible.

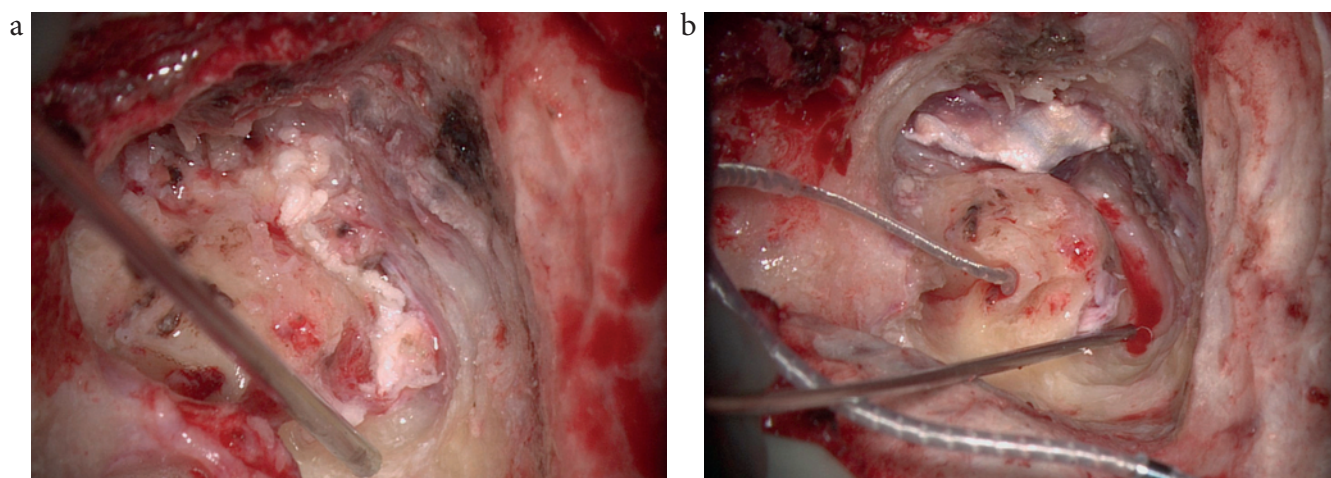


Fig. 1. Cochlear implant (b) after removal of supralabyrinthine petrous bone cholesteatoma with facial nerve interrupted by the lesion (a).

More than one half of the patients presented with facial nerve paralysis. Only in some of these cases facial nerve function may be preserved or improved. The transotic approach provides a good option for these patients.<sup>3</sup>

Out of 72 cases, close to 20% were managed through a transotic approach (Fig. 2). The modified translabyrinthine approach (with associated subtotal petrosectomy), and the subtotal petrosectomy were the other two approaches more commonly used.

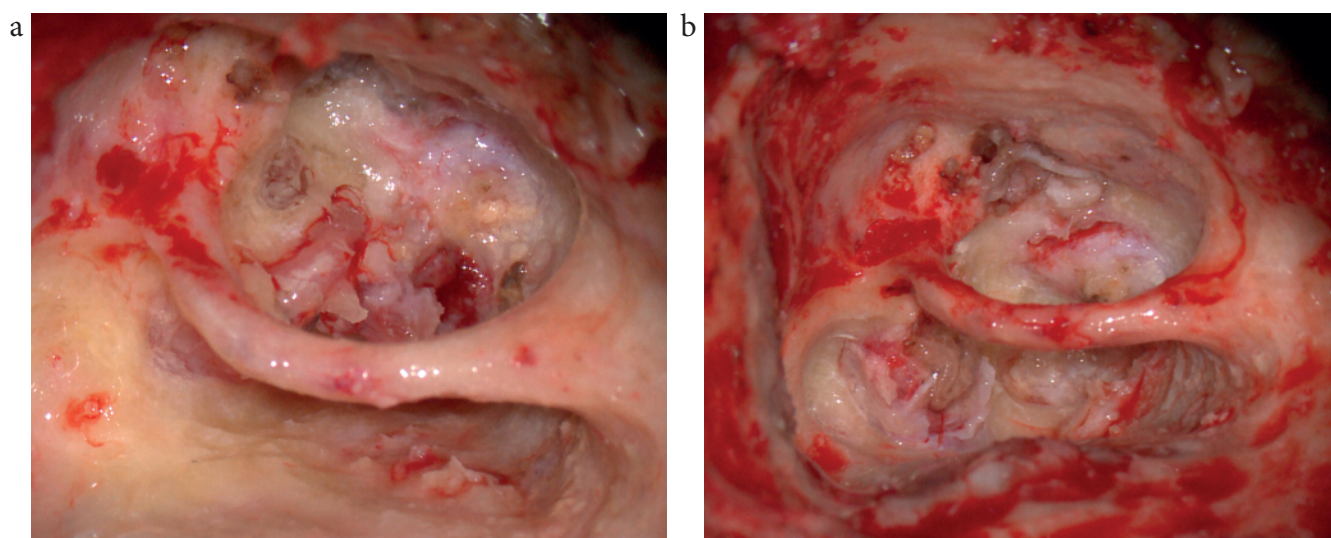


Fig. 2. Transotic approach for an infralabyrinthine petrous bone cholesteatoma. (a) Cochlear involvement; (b) Final view after total resection

Facial nerve function may still be present when facial nerve is critically involved. Supralabyrinthine tumors, the most common in the series, may compromise the labyrinthine portion of the facial nerve, a critical site where the facial nerve may be interrupted if it is previously compromised. Facial reanimation techniques are required to offer the best facial nerve function possible in these cases.

The transotic approach also associates a subtotal petrosectomy. In more than 70% of the cases, the middle ear was eliminated. This approach provides better protection against potential infections via external auditory canal or superior respiratory tract.

The facial nerve may be partially displaced, but avoiding rerouting (anterior or posterior) we will have the best option to preserve or restore facial nerve function when possible. And the transotic approach is the best way to do so. Table 4 shows facial nerve outcomes. Facial nerve function could be maintained if preoperatively normal, but some of the patients may worsen after surgery and require facial nerve rehabilitation procedures. When the transotic approach was used, all the patients maintained their preoperative facial nerve function or improved it.

The transotic approach also provides exposure of the apical compartment although with less control of the apical and clival regions when compared to the transcochlear approach. The transotic approach impedes hearing rehabilitation through a cochlear implant if it may be the case.

## 5. Conclusion

The transotic approach provides good exposure for deeply located petrous bone cholesteatoma offering an excellent protection against infection and a good option for facial nerve function preservation. On the other side it loses any chance of hearing rehabilitation through a cochlear implant.

## References

1. Omran A, De Donato G, Piccirillo E, Leone O, Sanna M. Petrous Bone Cholesteatoma: Management and Outcomes. *Laryngoscope* 2006;116(4):619-626.
2. Sanna, M.; Mazzoni, A.; Landolfi, M.; Aristegui, M.; Tratamiento del Colesteatoma Intrapetroso (CIP). *Acta Esp ORL* 1994;45(3):143-152.
3. Gantz BJ, Fisch U. Modified transotic approach to the cerebellopontine angle. *Arch Otolaryngol* 1983;109(4):252-256

# SUBTOTAL PETROSECTOMY FOR COCHLEAR IMPLANTATION IN CASES OF CHRONIC OTITIS MEDIA

Miguel Aristegui<sup>1</sup>, Ignacio Aristegui<sup>2</sup>, Gracia Aranguez<sup>3</sup>

<sup>1</sup>ENT Department, Hospital General Universitario Gregorio Marañón, Madrid, Spain; <sup>2</sup>ENT Department, Hospital Universitario de Móstoles, Madrid, Spain; <sup>3</sup>ENT Department, Hospital General Universitario Gregorio Marañón, Madrid, Spain

## 1. Introduction

Cochlear implantation in cases of chronic otitis media is a challenging condition. The risk of infection compromising the viability of the implant prone to modified the surgical technique to increase protection of the implant and reduce the chances of middle ear infection. Getting rid of the middle ear through a subtotal petrosectomy<sup>1</sup> provides, in our opinion, the best option to reach both targets.

## 2. Materials and Methods

A retrospective review of patients with chronic otitis media managed through a subtotal petrosectomy approach by the senior author is included. The different conditions related to chronic otitis media that have been managed with this approach are described. A detailed description of the approach is outlined. Minor and major complications are reported.

## 3. Results

Out of 50 cases of subtotal petrosectomy managed with a subtotal petrosectomy approach, 23 were in cases of chronic otitis media. Table 1 shows the distribution by different chronic otitis media conditions in cases of subtotal petrosectomy and cochlear implantation. Table 2 shows complications in this series. All the patients benefit from the cochlear implants and are using it. Only one patient required explantation due to infection related to hematoma provoked by autolytic grasping of the wound in the immediate postoperative period. This was a binaural implant that was managed for more than one year with local and parenteral antibiotics and revision surgeries to try to

Table 1. Different conditions of chronic otitis media and number of cases with cochlear implantation

n=23	
Chronic suppurative otitis media	5
Acute relapsing otitis media	7
Middle ear cholesteatoma	5
Petrous bone cholesteatoma	3
Old radical cavity	3

Correspondence: Miguel Arístegui, Avenida de Burgos, 9B, 28036 Madrid, Spain.  
E-mail: miguelaristegui@gmail.com

*Cholesteatoma and Ear Surgery – An Update 2017, pp. 13 -16*  
*Edited by Matthew Yung*  
2017 © Kugler Publications, Amsterdam, The Netherlands



Table 2. Complications of cochlear implantation in cases of chronic otitis media

<b>COMPLICATIONS n=23</b>	
<b>MINOR</b>	
Vertigo	0
Transient facial nerve palsy	0
Seroma	0
Retroauricular dehiscence	0
Granuloma	0
Repneumatization of the eustachian tube	0
Infection through the EAC	0
<b>MAJOR</b>	
Intracranial infection	0
Infection + extrusion + explantation	1 (4.3%)
Facial Nerve Paralysis	0
Device failure	0
Residual cholesteatoma	0

save the implant. Finally, it required explantation due to uncontrollable disease. There were no differences in performance form different implants, and all types were used (Cochlear, Medel, Advance Bionics and Neurelec). Detailed hearing outcomes are not reported in this paper.

### 3.1. Subtotal Petrossectomy as related to cochlear implantation.

Retroauricular skin incision is larger than for a conventional mastoidectomy to allow retromastoid extension if required. Blind sac closure of the external auditory canal I performed by elevating the skin from de tragal and conchal cartilage. It may be troublesome when there is a previous meatoplasty. Then a larger skin flap obtained from the anterior tragal region is helpful. For the second layer, we use a suture of the tragal cartilage to the soft tissues around the conchal region. This permits to have available the whole retromeatal musculoperiosteal tissue for a tighter closure at the end of the procedure. Mastoidectomy should be extensive with elimination of all mastoid, retrosinusal, peri-labyrinthine and infra-labyrinthine cells to prevent granuloma formation from mucosal entrapment and persistent infection from residual infected mucosa. Sealing of the Eustachian tube is done after extensive drilling and bipolar coagulation of the protympanum. To avoid re-pneumatization autologous materials are preferable. Periosteum, muscle, perichondrium and cartilage are the preferred ones. Obliteration of the cavity is performed with abdominal fat. In this way we believe we will offer the best protection to the cochlear implant

## 4. Discussion

Chronic otitis media is associated with an increase in the probability of potential episodes of middle ear infection. When considering cochlear implantation in patients with chronic otitis media we should bear in mind the technique that offers the minimal risk of infection in the operated ear.

Subtotal petrossectomy by sealing the entrance through the external auditory canal and through the Eustachian tube offers the safest option to prevent future infections.<sup>2</sup> Regardless the condition, either with normal anatomy, sclerotic or contracted mastoid or an open cavity, subtotal petrossectomy provides the best promontorial access for electrode insertion (Fig. 1).

Acute relapsing otitis media, active chronic suppurative otitis media, middle ear cholesteatoma, old radical cavities and petrous bone cholesteatoma may all benefit from the subtotal petrossectomy technique.<sup>3</sup>

Acute relapsing otitis media may continue after cochlear implantation and could compromise the future of the

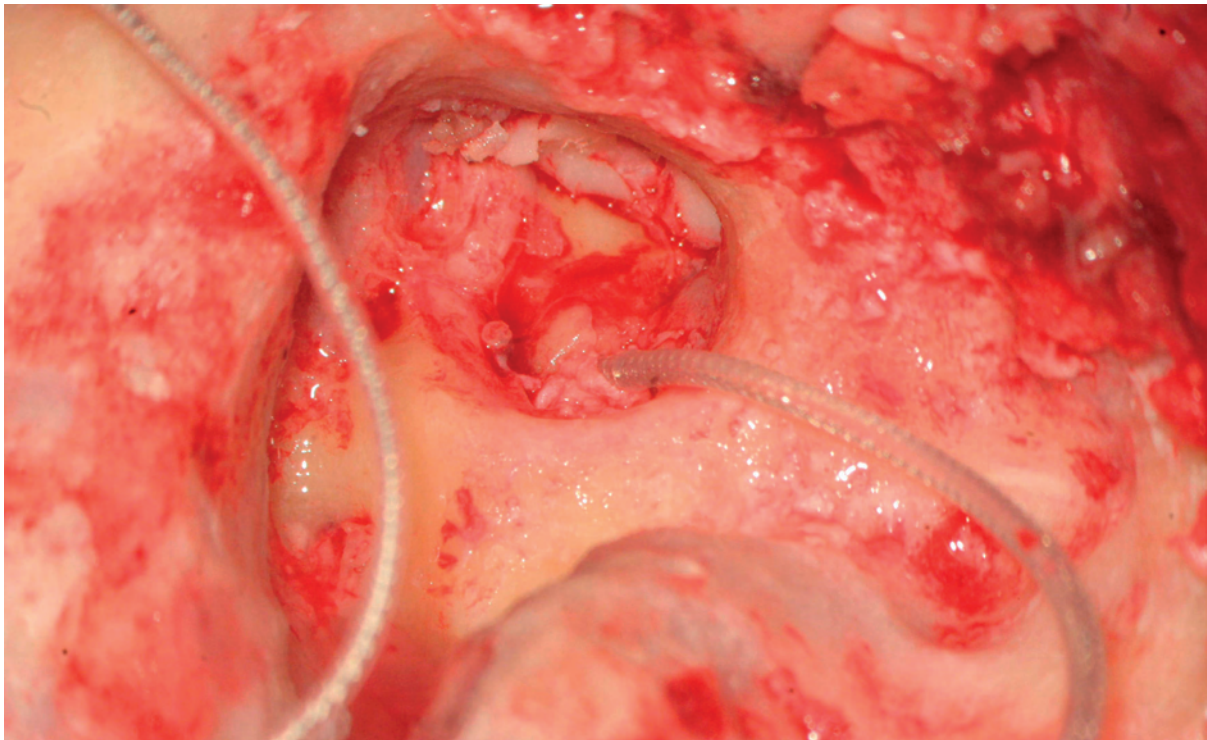


Fig. 1. Cochlear implant after subtotal petrosectomy.

cochlear implant. The same applies to active chronic otitis media with a higher risk of potential infection that could lead to cochlear explantation.

All but one of the cases were done in a single-stage procedure. We only staged one case of tuberculosis that required specific antimicrobial treatment and resolution of infection before considering cochlear implantation that was performed in a second stage.

Conventional obliterative techniques for middle ear cholesteatoma have an intrinsic risk of recurrent or residual disease that may lead to revision surgery that could jeopardize the stability of the implant.

Old radical cavities require obliteration with cartilage if associated with open-cavity techniques in cases with cochlear implantation. Nevertheless, potential extrusion is always present lifelong. Subtotal petrosectomy reduces the chances of extrusion when compared to those techniques.

Petrous bone cholesteatoma requires special advance techniques. Subtotal petrosectomy is commonly associated with them to prevent intracranial complications. Some of these cases may benefit from cochlear implantation when both ears are compromised (Fig. 2). Follow-up of these cases after cochlear implantation with MRI are limited by the shadow effect of the implant itself when following for residual disease. Nevertheless, the interface

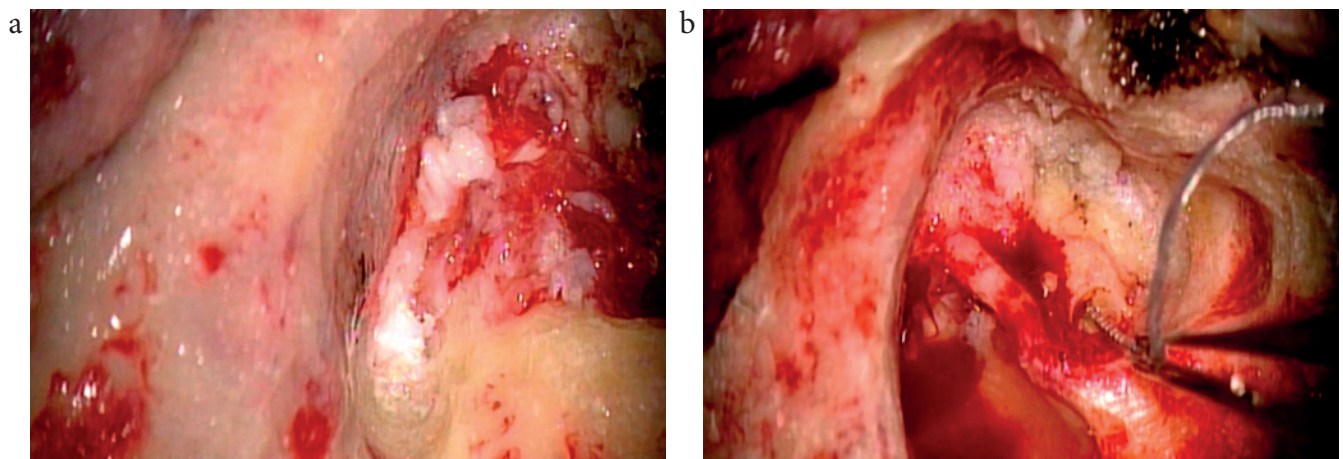


Fig. 2. (a) Supralabyrinthine petrous bone cholesteatoma; (b) Cochlear implant in place after removal of cholesteatoma.



between fat and the surrounding tissues may help in identifying it. And some of the projections allow to detect remnants on MRI.

Finally, removing the external canal wall through the canal wall down mastoidectomy as part of the subtotal petrosectomy approach provides excellent promontorial access and facilitates electrode insertion through the round window, through cochleostomy or through drill-out techniques depending on the case and regardless the condition.

The rate of complications is low compared to other conventional approaches in cases of cochlear implantation for chronic middle ear disease.

## **5. Conclusion**

Subtotal petrosectomy provides the safest approach for cochlear implantation in cases of chronic ear disease. The low rate of complications supports this approach. It also provides excellent promontorial access to facilitate electrode insertion regardless the difficulties encountered intraoperatively.

## **References**

1. Fisch U, Mattox D. Microsurgery of the Skull Base. Stuttgart, Germany: Georg Thieme Verlag 1988.
2. Sanna M, Dispenza F, Flanagan S, De Stefano A, Falcioni M. Management of chronic otitis by middle ear obliteration with blind sac closure of the external auditory canal. *Otol Neurotol* 2007;29:19-22.
3. Polo R, Medina MM, Arístegui M, et al. Subtotal Petrosectomy for cochlear Implantation: lessons learned after 110 cases. *Ann Otol Rhinol Laryngol* 2016;125(6):485-494.

# SKULL-BASE CHOLESTEATOMA MANAGEMENT OPTIONS: THEN AND NOW

Mathieu Forgues, Moisés A. Arriaga

*Department of Otolaryngology, Louisiana State University Health Sciences Center, New Orleans, Louisiana, USA*

## 1. Approaches and technique

Classic approaches to the cerebellopontine angle (CPA) and petrous apex include the transcochlear and transotic approaches. The transcochlear approach, developed by House and Hitselberger in the early 1970s as a modification of the translabyrinthine approach, achieved improved anterior visualization of the CPA and IAC without cerebellar retraction and with preservation of the facial nerve.<sup>1</sup> However, due to facial nerve mobilization, this approach results in incomplete facial recovery postoperatively.<sup>2,3</sup> The transotic approach provides near-equal visualization and achieves a much reduced rate of postoperative facial nerve palsy by leaving the mastoid and tympanic segments of the facial nerve *in situ*. This approach involves obliteration of the surgical cavity and permanent closure of the ear canal and Eustachian tube, resulting in reduced rates of CSF leakage.<sup>4</sup>

Achieving maximal visualization and surgical freedom, minimizing residual disease, preserving hearing and protecting critical neurovascular structures are the goals which must be balanced and prioritized by the surgeon. Some maintain that attempts to reduce morbidity by minimizing exposure will result in a higher rate of recurrence, leading to subsequent, more difficult surgeries and worse long-term outcomes.<sup>5</sup> Others point to the tumor's benign histology and slow, linear growth<sup>6</sup> as evidence that patients are unlikely to suffer a clinically symptomatic recurrence, and argue for a conservative approach that minimizes neurological injury despite leaving adherent tumor.<sup>7</sup>

A recent review by Miller and Cueva found a function preserving approach to achieve adequate resection of tumor without increasing the need for reoperation.<sup>8</sup> Eleven of 18 patients with an epidermoid cyst involving the CPA underwent a retrosigmoid approach and were followed for an average of 71.4 months postoperatively. Follow-up imaging revealed a focal or small tumor residue in the majority, with none requiring reoperation. Their series demonstrated preservation of hearing at or near preoperative level in seven of nine patients who underwent a retrosigmoid approach. They remarked that hearing can potentially improve significantly after tumor removal, which they observed in one patient in their series, and thus encouraged reserving hearing-sacrificing approaches for patients with profound hearing loss. Hearing improvement, and occasionally hearing restoration from deafness, while rare, have been reported in other cases of non-acoustic CPA tumor resections.<sup>9-12</sup> Other reviews have similarly concluded it is reasonable to limit the resection in cases of deep extension or dense adherence to vital structures, without an increase in rate of recurrence.<sup>13</sup> However, others encourage aiming for complete resection in all cases, sacrificing hearing and mobilizing the facial nerve when required.<sup>5</sup>

Our center has adopted a conservative approach with gross total resection only if the cranial nerves and vital structures can be easily separated. These are not malignant lesions, hence brainstem decompression with preservation of vital structures are our surgical objectives. The use of the retrosigmoid approach enhanced with endoscopes is our preferred approach. However, in recurrent lesions or cases with pre-existing hearing loss, vestibulopathy

Correspondence: Moisés A. Arriaga, MD, MBA, FACS, Department of Otolaryngology, Louisiana State University Health Sciences Center, 533 Bolivar St Ste 566, New Orleans, 70112 LA, USA.  
E-mail: maa@neurotologic.com

*Cholesteatoma and Ear Surgery – An Update 2017, pp. 17-20*

*Edited by Matthew Yung*

*2017 © Kugler Publications, Amsterdam, The Netherlands*

or other cranial nerve deficits, transtemporal strategies from retrolabyrinthine to translabyrinthine, transotic and even transcochlear approaches will be selectively utilized, sometimes in combination with middle cranial fossa exposure as part of a combined petrosal approach.

The introduction of the endoscope has helped bridge the divide between conservative surgery and the goal of total resection. The endoscope's primary advantage over the microscope is its dynamic range of vantage points and viewing angles, allowing the surgeon to see around corners and beyond obstacles to sites outside the microscope's line of sight. The ideal use of endoscopes in CPA epidermoid surgery is still debated. Some have reported utilizing it for active removal of tumor as an adjunct to traditional microscopic technique,<sup>7,14,15</sup> while others use it solely to assess completion of microscopic resection.<sup>16</sup> Two reviews of the use of endoscopes to confirm gross-total microscopic resection of CPA epidermoids revealed discovery of occult disease in 69 and 85% of cases.<sup>7,15</sup> Primary endoscopic resection of CPA and middle fossa epidermoids without microscopic dissection has also been reported.<sup>17,18</sup> Our team has found endoscopes a useful adjunct in microscopic removal by identifying remaining areas of matrix and limiting the aggressiveness of bone removal.

Staged resections are recommended by some surgeons for bilateral procedures to allow interval recovery of neurological deficits. Others have endorsed, in cases of supratentorial extension, a retrosigmoid approach followed by a second-stage middle fossa approach.<sup>16</sup> Postoperative MRI has been reported to incompletely show tumor capsule<sup>15</sup> and to have difficulty differentiating residual or recurrent tumor from CSF filling the defect,<sup>16</sup> although use of non-echo planar diffusion-weighted MRI has improved the ability to detect these tumors. The endoscope provides an additional tool to evaluate residual disease intraoperatively and plan the second stage accordingly.

## 2. Encephalocele repair

Through erosion of the skull base, cholesteatoma sometimes causes encephaloceles of the middle fossa floor or posterior fossa wall. Removal of the cholesteatoma and repair of the skull base can be performed simultaneously or in a staged manner, with the initial stage focused on either the encephalocele or the chronic ear disease. Strategically our team prefers to manage the encephalocele first; however, if a simultaneous cholesteatoma and encephalocele repair is pursued, the surgeon must be certain that all of the cholesteatoma has been removed. If the surgeon has any doubt that residual cholesteatoma is present and the encephalocele is limited in scope and symptoms, it is advisable to return at a second stage to confirm the absence of recurrent disease and repair the skull base defect.

Ideally, complete eradication of the cholesteatoma is achieved. If matrix is discovered over a dehiscent labyrinth, the management is individualized according to size, hearing status and contralateral hearing. Cholesteatomas causing large labyrinthine erosions in ears with useful hearing are typically left in place to prevent destruction of hearing. However, extensive invasion into the labyrinth may require removal of the cholesteatoma due to concern for extension into the IAC.<sup>19</sup> Tumor capsule should be peeled from involved dura when possible. When the dura requires resection, it can be repaired primarily or closed with harvested temporalis fascia or other dural substitute sutured to the edges of the defect.<sup>19,20</sup> No differences in outcomes have been found between intradural and extradural approaches for success in encephalocele repair; we recommend an extradural graft repair to limit intradural dissection and prevent damage to brain parenchyma.<sup>21</sup> The extradural strategy is particularly recommended for encephalocele repair in the face of cholesteatomas to minimize the risk of intradural cholesteatoma spread.

We generally advocate initial management of the encephalocele followed by a second-stage surgery to eliminate the chronic ear disease. In cases of a large bone defect, it is advantageous to first isolate the brain and stage the mastoidectomy. This provides primary control of the CSF leak and minimizes the risk of ear-to-brain infection.

Herniated brain contents should be excised. This can be performed with bipolar cautery without risk of neurologic damage.<sup>21</sup> Preserving compromised brain tissue can lead to necrosis and abscess, necessitating removal of all components of the reconstruction.

Repair of the skull base is traditionally achieved with a multilayered reconstruction, which includes both a soft tissue repair of the dura and reconstruction of the bony architecture, using contributions from various tissues.<sup>21</sup> The senior author prefers a 3 layered reconstruction composed of a thick alloderm layer placed on the floor of the middle cranial fossa, covered with a contoured bone flap and another layer of alloderm extending onto the lateral surface of intact temporal lobe dura. Titanium mesh is used to reconstruct the craniotomy defect.

### 3. Conclusion

Cholesteatomas of the skull base present a unique management challenge to the surgeon. Modern neurotologic surgery offers a wealth of approaches to the skull base and allows circumnavigation of the labyrinth, facial nerve, and other critical neurovascular structures. Rapidly evolving technology has improved intra and postoperative reliability and permitted an emphasis on outcomes and decreased morbidity.

### References

1. De la Cruz A, Teufert KB. Transcochlear Approach to Cerebellopontine Angle Lesions. In: Shelton C, Arriaga MA (eds.), *Otologic Surgery* (3rd ed.), pp. 631-640. Philadelphia: W.B. Saunders 2010.
2. Adunka OFB, Craig A. *Otology, Neurotology, and Lateral Skull Base Surgery: An Illustrated Handbook*. Thieme 2011.
3. De la Cruz A, Teufert KB. Transcochlear approach to cerebellopontine angle and clivus lesions: indications, results, and complications. *Otol Neurotol* 2009;30(3):373-380.
4. Fisch U, Chen JM. Transotic Approach. In: Shelton C, Arriaga MA (eds.), *Otologic Surgery* (3rd ed.), pp. 621-630. Philadelphia: W.B. Saunders 2010.
5. Kaylie DM, Warren FM 3rd, Haynes DS, Jackson CG. Neurotologic management of intracranial epidermoid tumors. *Laryngoscope* 2005;115(6):1082-1086.
6. Alvord EC, Jr. Growth rates of epidermoid tumors. *Ann Neurol* 1977;2(5):367-370.
7. Tuchman A, Platt A, Winer J, et al. Endoscopic-assisted resection of intracranial epidermoid tumors. *World Neurosurg* 2014;82(3-4):450-454.
8. Miller ME, Mastrodimos B, Cueva RA. Hearing Preservation in Management of Epidermoids of the Cerebellopontine Angle: CPA Epidermoids and Hearing Preservation. *Otol Neurotol* 2012;33(9):1599-1603.
9. Maurer PK, Okawara SH. Restoration of hearing after removal of cerebellopontine angle meningioma: diagnostic and therapeutic implications. *Neurosurgery* 1988;22(3):573-575.
10. Katsuta T, Inoue T, Uda K, Masuda A. Hearing restoration from deafness after resection of a large cerebellopontine angle meningioma – case report. *Neurologia medico-chirurgica* 2001;41(7):352-355.
11. Mallucci CL, Ward V, Carney AS, O'Donoghue GM, Robertson I. Clinical features and outcomes in patients with non-acoustic cerebellopontine angle tumours. *J Neurol Neurosurg Psychiatry* 1999;66(6):768-771.
12. Vellutini EA, Cruz OL, Velasco OP, Miniti A, Almeida GM. Reversible hearing loss from cerebellopontine angle tumors. *Neurosurgery* 1991;28(2):310-312; discussion 312-313.
13. Schiefer TK, Link MJ. Epidermoids of the cerebellopontine angle: a 20-year experience. *Surg Neurol* 2008;70(6):584-590; discussion 590.
14. Schroeder HW, Oertel J, Gaab MR. Endoscope-assisted microsurgical resection of epidermoid tumors of the cerebellopontine angle. *J Neurosurg* 2004;101(2):227-232.
15. Abolfotoh M, Bi WL, Hong CK, et al. The combined microscopic-endoscopic technique for radical resection of cerebellopontine angle tumors. *J Neurosurg* 2015;123(5):1301-1311.
16. Safavi-Abbasi S, Di Rocco F, Bambakidis N, et al. Has management of epidermoid tumors of the cerebellopontine angle improved? A surgical synopsis of the past and present. *Skull Base* 2008;18(2):85-98.

17. Trivelato FP, Giannetti AV. Endoscope-controlled microneurosurgery to treat middle fossa epidermoid cysts: technical case report. *Neurosurgery* 2008;62(3 Suppl 1):105-106; discussion 106-107.
18. de Divitiis O, Cavallo LM, Dal Fabbro M, Elefante A, Cappabianca P. Freehand dynamic endoscopic resection of an epidermoid tumor of the cerebellopontine angle: technical case report. *Neurosurgery* 2007;61(5 Suppl 2):E239-240; discussion E240.
19. Hanson JR, Esquivel C, Backous DD. Diagnosis and management of aggressive, acquired cholesteatoma with skull base and calvarial involvement: a report of 3 cases. *Am J Otolaryngol* 2006;27(4):291-294.
20. McMurphy AB, Oghalai JS. Repair of iatrogenic temporal lobe encephalocele after canal wall down mastoidectomy in the presence of active cholesteatoma. *Otol Neurotol* 2005;26(4):587-594.
21. Chen DA. Chapter 20 - Dural Herniation and Cerebrospinal Fluid Leaks. In: Shelton C, Arriaga MA (eds.), *Otologic Surgery* (3rd ed.), pp. 245-251. Philadelphia: W.B. Saunders 2010.

# LONG-TERM MANAGEMENT OF CHOLESTEATOMA WITH LABYRINTHINE DESTRUCTION, SKULL BASE INVOLVEMENT, AND INTRACRANIAL EXTENSION

Christina C. Cobb, P. Cody Buchanan, Uresh Patel, Douglas D. Backous

*Swedish Neuroscience Institute, Seattle, Washington*

## Abstract

**Objectives:** We analyzed the clinical presentation, imaging findings, and surgical treatment of ten patients with aggressive, skull base, acquired cholesteatoma in order to develop an acute treatment algorithm and a long-term management strategy for patients living with unresectable disease.

**Study design:** A retrospective case series at two tertiary referral centers.

**Methods:** A retrospective review of the clinical data on all patients at our institutions treated from 1997-2015 by the same surgeon for aggressive acquired cholesteatoma with skull base and/or labyrinthine involvement was conducted. Past otological history, clinical exam findings, pre- and postoperative audiometric, CT, MRI, and intraoperative results were compared between patients. Pertinent imaging was reviewed by at least two neuroradiologists in blinded fashion. We then defined an acute management protocol and long-term follow-up algorithm.

**Results:** From 1997 to 2015, six males and four females, age 12 to 73 years (mean, 42.3 years), were treated for acquired cholesteatoma with skull base or labyrinthine invasion at our institution. Mean follow-up was 76.6 months. Two patients had no prior otological surgery, while eight had an average of two prior procedures for cholesteatoma management. Hearing loss was present in ten patients, otorrhea in four, progressive facial palsy in three, otalgia in three and two described progressive imbalance. At surgical exploration, two patients had destruction of the cochlea, four had skull-base invasion and four had intracranial involvement. None had violation of the dura. Five patients required temporal bone obliteration, two had radical cavities with exteriorization of the petrous apex, and three required canal wall-down mastoidectomy and wide meatoplasty. One patient with HB grade V preoperative VII palsy recovered to HB grade III. After surgery, one patient with labyrinthine destruction maintained serviceable hearing post op. No patients had additional complications from their definitive surgical procedures.

**Conclusions:** Acquired cholesteatoma with labyrinthine destruction, skull-base extension, and intracranial involvement can have surprisingly subtle presentation. Disease eradication is often not possible due to anatomical challenges. Long-term clinical follow-up with periodic imaging and aggressive debridement is often necessary for disease control.

## 1. Introduction

Cholesteatoma with intracranial or skull-base extension is uncommon, and often presents with subtle clinical findings.<sup>1</sup> The majority of patients report a prior history of otological surgery.<sup>1,2</sup> Intraoperative findings dictate whether cavity exteriorization, partial mastoid obliteration, or complete mastoid obliteration with blind-sac closure of the external auditory canal should be performed.<sup>3</sup> Long-term clinical and radiological surveillance is mandatory to monitor recidivism and the risk for secondary infection.

Correspondence: Christina C. Cobb  
E-mail: c.cobb9@gmail.com

*Cholesteatoma and Ear Surgery – An Update 2017, pp. 21 -24*

*Edited by Matthew Yung*

*2017 © Kugler Publications, Amsterdam, The Netherlands*



## 2. Methods

A retrospective review of the clinical data on all patients at our institutions treated from 1997-2015 by the same surgeon for aggressive acquired cholesteatoma with skull base and/or labyrinthine involvement was conducted. Past otological history, clinical exam findings, pre- and postoperative audiometric, CT, MRI, and intraoperative results were compared between patients. Pertinent imaging was reviewed by at least two neuroradiologists in blinded fashion. We then defined an acute management protocol and long-term follow-up algorithm. The Human Subjects Review Committee from Swedish Medical Center granted this study an exemption.

## 3. Results

Between 1997 to 2015, six males and four females, age 12 to 73 years (mean, 42.3 years), were treated for acquired cholesteatoma with skull base or labyrinthine invasion at our institutions. Follow-up ranged from eight to 216 months (mean, 76.6 months). Two patients had no prior surgery, while eight had an average of two prior procedures. Table 1 shows the clinical presentations of the ten patients. All ten complained of hearing loss, four had otorrhea, three had acute facial palsy, three had otalgia and two presented with progressive imbalance. Four patients had history of otitis media. Table 2 provides a more comprehensive analysis into the presenting symptoms of the ten patients.

**Table 1.** Clinical Presentations

Case No.	Age (y)	Sex	Chief Complaint	History of Otitis Media	Prior Surgery (n)	PTA* (dB) at Presentation
1	73	Male	Progressive unilateral facial palsy	No	0	61.25
2	33	Male	Otalgia	No	4	28.75
3	40	Male	Otorrhea	No	0	77.5
4	12	Male	Otalgia	No	1	27.5
5	34	Female	Otorrhea	Yes	1	NR
6	64	Female	Otorrhea	No	1	91.25
7	50	Female	Progressive unilateral facial palsy	Yes	1	93.75
8	29	Female	Otorrhea	Yes	2	51.25
9	48	Male	Otalgia	Yes	2	71.25
10	40	Male	Progressive unilateral facial palsy	No	1	NR

\*Pure Tone Average  
\*\*No response

Upon analysis of the facial nerve weakness outcomes of the pre- and postsurgical procedure, it is noted that two patients remained at the same facial nerve function pre- and postsurgical outcome. One patient (number 7) had a HB grade of V presurgery, and remained HB grade V post-surgery. Another patient (number 10) had a HB grade of III presurgery, and remained HB grade III postsurgery. Case number 1 improved facial nerve functioning post-surgery. Case number 1 had a HB grade of VII pre-surgery, and a HB grade of III post-surgery. No patients had degradation of facial nerve function post-operation. Facial nerve function was described using the AAO-HNS facial nerve grading scale (House-Brackmann).<sup>4</sup> Table 3 presents the surgical findings and procedures performed. At surgical exploration, two patients had cholesteatoma with destruction of the cochlea, four had skull-base invasion and four had intracranial involvement. Five patients required temporal bone obliteration, two had radical cavities with exteriorization of the petrous apex, and three required modified radical cavities. One patient with labyrinthine destruction maintained residual hearing post op. No patients had additional complications from their definitive surgical procedures.

**Table 2.** Presenting Symptoms

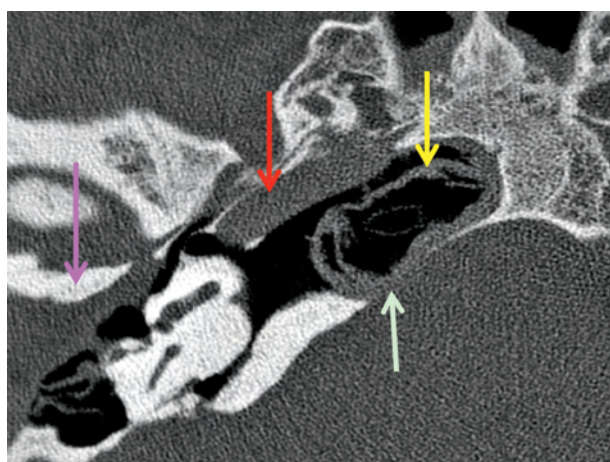
Symptom	Number of Patients	Percent (%)
Hearing loss	10	100
Otitis media	4	40
Otorrhea	4	40
Otalgia	3	30
Facial nerve weakness	3	30
Tinnitus	2	20
Vertigo	2	20
Progressive imbalance	2	20

**Table 3.** Surgical Findings

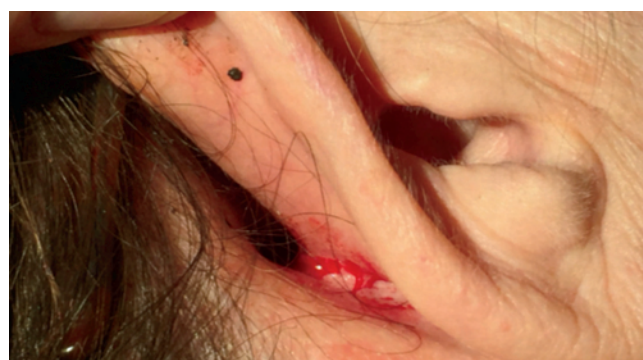Cholesteatoma Extension	Number of Patients (% total patients)
Destruction of the cochlea	2 (20)
Skull base invasion	4 (40)
Intracranial involvement	4 (40)
<b>Reconstruction Required</b>	
Modified radical cavity	3 (30)
Radical cavity with exteriorization of the petrous apex	2 (20)
Temporal bone obliteration	5 (50)

#### 4. Conclusions

Labyrinthine and skull base extension of cholesteatoma can present with surprisingly subtle findings. A high index of suspicion is necessary to define the extent of the disease. The decision to exteriorize versus closing off the defect cavity requires prudent radiological workup and surgical planning. Disease eradication is often not possible. Long-term clinical follow-up with periodic imaging and aggressive debridement is necessary for disease control in certain cases. The modality of imaging in our center is determined in consultation with our neuroradiology team. Figure 1 shows a patient with stable petrous apex cholesteatoma being followed with serial CT scanning. In this particular case, we chose CT scanning as opposed to the use of diffusion weighted MRI scanning under advisement of our radiologist. Patients may require repeated surgical explorations for known recidivistic disease, particularly in the petrous apex, due to the inability to eradicate all cholesteatoma in the setting of facial nerve dehiscence, labyrinthine destruction, intracranial extension, or with cerebrospinal fluid leakage. We feel it is important to provide informed consent prior to the patient's first operation, that due to the extent and anatomical location of their cholesteatoma, it is probable that they will require more than one surgical procedure, as dictated by clinical and radiological exam findings. Abdominal fat packing is controversial in cases of extensive cholesteatoma with concurrent CSF leakage due to potential bacterial involvement in the mastoid defect.



*Fig. 1.* Axial CT showing a cholesteatoma in the petrous apex (yellow arrow); carotid artery dehiscence into petrous apex (red arrow); dehiscence of the medial wall of the petrous apex (green arrow). There is a previous mastoidectomy defect with recurrent cholesteatoma (pink arrow).



*Fig. 2.* Controlled postauricular fistula is well epithelialized and provides access for exteriorization into the petrous apex and superior to the cochlear aqueduct in a patient with petrous apex involvement illustrated in Figure 1..



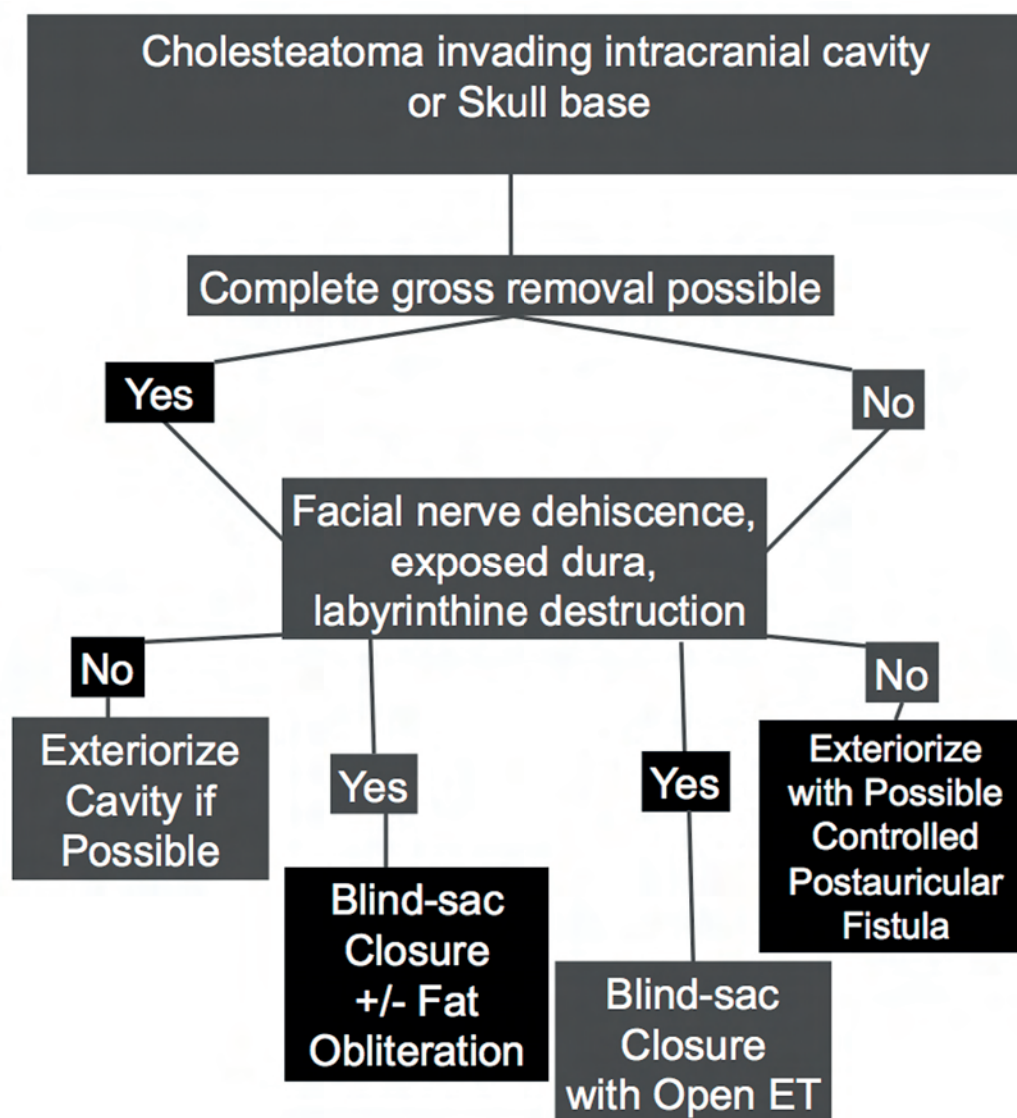


Fig. 3. Proposed intraoperative decision algorithm.

We did not experience CSF leakage in our study. The use of a controlled postauricular fistula enhanced petrous apex ventilation and cleaning in patient number 7 in our series (Fig. 2). We present our treatment algorithm in Figure 3 as a potential model for long-term care for these difficult to manage patients.

## References

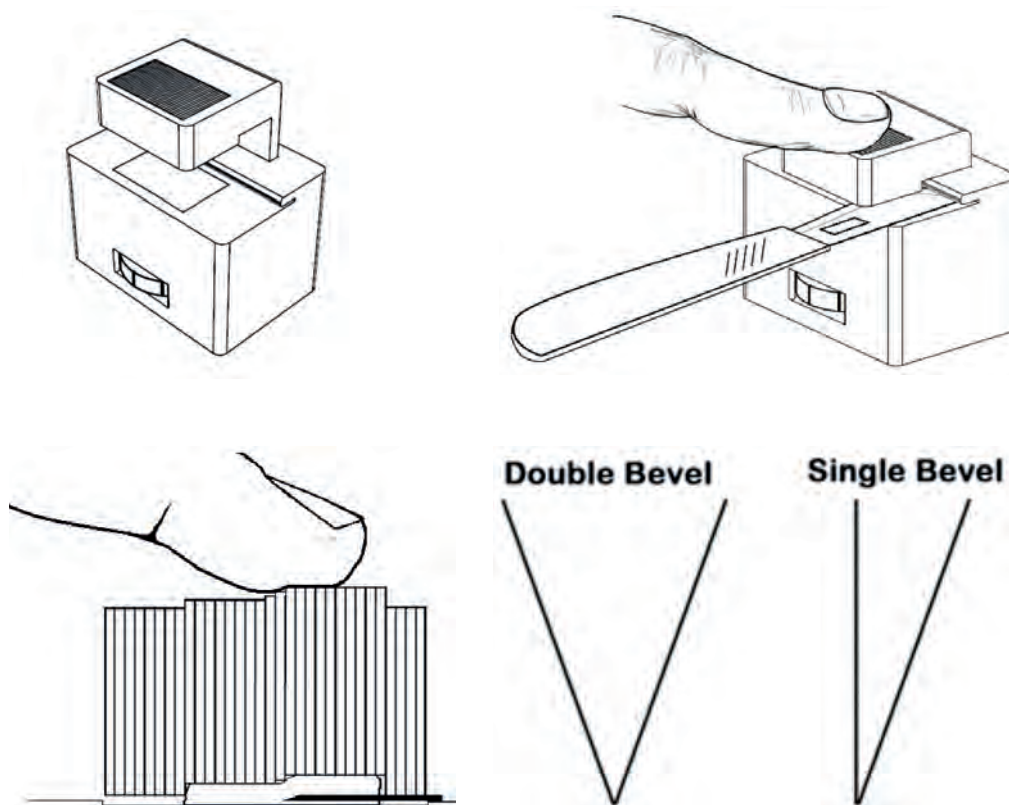
1. Horn K. Laryngoscope, 2000, 110: 761-772.
2. Burggraaff, B, et al. Am J Otol, 1995, 16: 480-485.
3. Axon O, et al. Am J Otol, 1999, 20: 505-510.
4. House JW, Brackmann DE. Otolaryngol Head Neck Surg 1985; 93: 146-147.
5. Hanson J, et al. Am J Otol, 2006, 27: 291-294

# ENDOSCOPIC EAR SURGERY: TIPS

M. Demir Bajin

*Hacettepe University Department of Otolaryngology, Ankara, Turkey*

Advantages of endoscopic ear surgery can be listed as: minimal invasive approach, faster healing, better quality of life, image quality and training benefits. Disadvantages are: lack of stereoscopic visualisation, one-handed approach and steep learning curve. We use 3-mm width, 14-cm length, 0° and 45° scopes, endoscope holder, cartilage slicer and a high-definition or 4K endovision system. The anaesthesiologist plays a vital role in keeping the surgical field bloodless by lowering the blood pressure throughout the operation. However, although we were very keen to use the endoscope holder we do not use it often, because it is time consuming, you need to take out the scope to clean the lens repeatedly and it is sometimes impossible to introduce the scope along with two other surgical instruments in a narrow ear canal. We almost always use cartilage graft, but we use a cartilage slicer to obtain 0,3-mm thick slices.



Correspondence: M. Demir Bajin, Hacettepe University Hospital Department of Otolaryngology, Altindag, 06100, Ankara, Turkey.  
E-mail: dbajin@hacettepe.edu.tr

*Cholesteatoma and Ear Surgery – An Update 2017, pp. 25 -26*

*Edited by Matthew Yung*

*2017 © Kugler Publications, Amsterdam, The Netherlands*



# TB PROTOTYPE : A PERFECT COMPLEMENT TO TRADITIONAL TEACHING OF MASTOIDECTOMY

D. Bakhos<sup>1,2</sup>, C. Dorbeau<sup>1</sup>, C. Aussedat<sup>1</sup>

<sup>1</sup>Service ORL et Chirurgie Cervico-Faciale, CHU de Tours, France; <sup>2</sup>Université François-Rabelais de Tours, CHRU de Tours, service ORL et CCF, UMR-S930, Tours, France

## 1. Background

Surgical experience plays a major role in the success of surgical procedures. This fact was demonstrated in locoregional surgical control techniques in colorectal cancer surgery<sup>1</sup> and in the audiometric results in functional stapes surgery.<sup>2</sup> This experience starts at the beginning of the otology resident training. However, the new regulations for patient safety, and the occupancy costs of operating rooms<sup>3</sup> have forced the scientific community to create new teaching programs to help overcome these limitations in surgical simulation of drilling.

The inexperienced otorhinolaryngologist must acquire a perfect knowledge of the temporal bone if they want to practice temporal bone and otologic surgery in order to perform masto-antro-atticotomy during cholesteatoma surgery or a cochlear implant procedure.

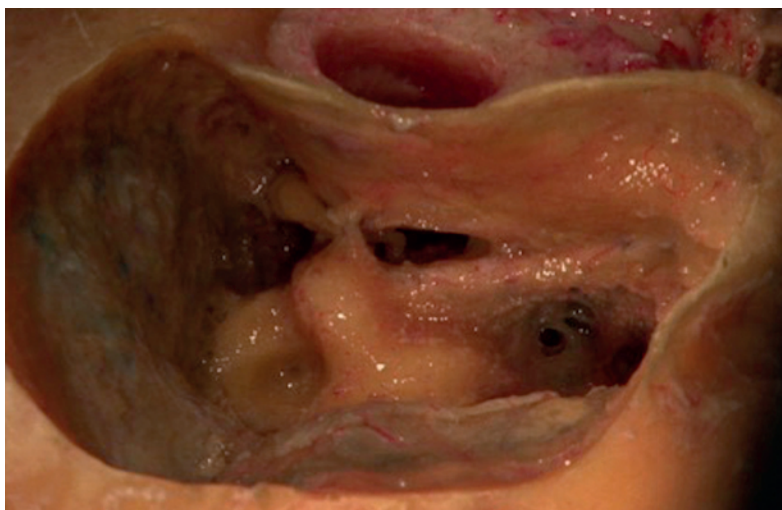

Fig. 1: Masto-antro-atticotomy, on a right cadaver temporal bone with facial nerve and semi-circular canals dissection.

The training starts with a thorough knowledge of the complex anatomy of the temporal bone. Therefore, reading reference books on the anatomy of the temporal bone and its dissection is mandatory. This complex anatomy can be more easily understood thanks to three-dimensional reconstruction virtual models now widespread on the Internet, following the development of computer science.

Acquiring surgical skills requires reading of surgery manuals, mostly written in English. Then, it is necessary to progress with dissection of temporal bones in anatomy laboratory before going to the operating room. This will enable the

students to identify main anatomic landmarks (Fig. 1) of the temporal bone (TB) and to acquire skills necessary to otologic surgery especially mastoid drilling. However, some medical faculties cannot facilitate this training opportunity for otologists because of body donation shortage and ethical restrictions. This can be compensated by virtual and physical prototyping, which allows otologic surgical training. These new tools have the advantage of reproducibility and are bound to be included in every training program in the future. In our center, we developed a TB prototype devoted to surgical education and training in three steps.

Correspondence: David Bakhos MD, PhD, ENT Department, UMR-S930, CHU Tours, 2 boulevard Tonnellé, 37000 Tours, France. .  
E-mail: bakhos\_d@med.univ-tours.fr

*Cholesteatoma and Ear Surgery – An Update 2017, pp. 27 -30*

*Edited by Matthew Yung*

*2017 © Kugler Publications, Amsterdam, The Netherlands*

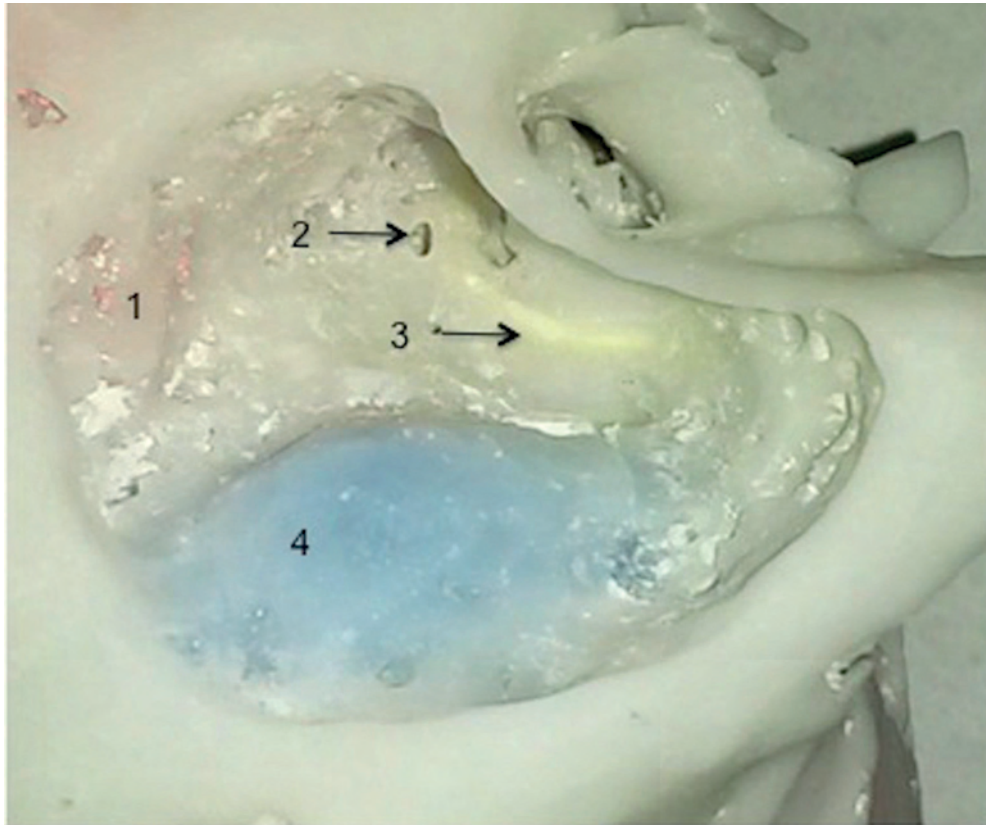


Fig. 2. Right temporal bone prototype made by stereolithography. Legend: 1: tegmen antri; 2: lateral semi-circular canal (open); 3: facial nerve (F3); 4: sigmoid sinus.

## 2. Material and method

In order to create an artificial TB prototype and to validate its usefulness during training program for young otologists, three steps were necessary: building a TB prototype, validation by external experts and evaluating the prototype in a training program.

Our **first step** was to build an artificial TB using rapid prototyping.<sup>4</sup> We used a TB CT scan to acquire DICOM data from a cadaveric TB. The DICOM data was converted into a machine file following data processing (segmentation and reparation). This file permitted to build a TB prototype using stereo-lithography (Fig. 2). Facial nerve canal relationships with other landmarks were compared between the cadaveric TB and the prototype using CT scan. The facial canal was injected with color (yellow) and several landmarks were painted (sigmoid sinus in blue, dura matter in pink). After the imaging validation, an oto-endoscopy of the tympanic cavity was performed in order to check the quality of the ossicular chain of the TB prototype. Then, we drilled the cadaveric TB and its prototype. Measurements of distances on the CT scan and during the TB drilling did not find significant differences.

The **second step** consisted of validation by external experts in otology.<sup>5</sup> Twenty-five otologists evaluated the TB prototype through a 20-item questionnaire, including aspects of anatomy-morphology, quality of drilling, identification of anatomical elements and stages of drilling. The satisfaction rate about the prototype was 92%. The drawbacks mentioned by otologists were the excessive vividness of the facial nerve color and the difficulty to identify the posterior semicircular canal. Among these experts, this kind of physical prototype appeared to be an attractive solution for the learning of TB dissection.

The **third step** of our work is to evaluate the interest of the TB prototype in a training program for ENT residents. We will perform a prospective and comparative study in order to evaluate two patterns of surgical teaching: on the one hand the *traditional* learning (drilling only cadaveric TB), on the other hand the *prototype* learning (two drillings: prototype, then cadaveric TB). Then, we will evaluate the surgical skills in these two



groups, using a validated scale. In conclusion, the physical prototype of TB could be a useful tool, allowing the enhancement of surgical skills (especially in the first steps) in a population of young otologists. Access to the anatomic laboratory or to cadaveric TBs is limited by a shortage of organ donors and the absence of a laboratory at many facilities. The major advantage of the TB prototype is the possibility to drill everywhere, unlike the cadaveric TB requiring an approved laboratory. Even if the cadaveric TB is the 'gold standard' regarding the teaching of mastoid dissection, these artificial models enable the young surgeons who do not have access to anatomic specimens to perform temporal bone drilling before surgery in real conditions. In this context, the physical TB model is a good opportunity to develop surgical skills, compared to traditional teaching, but cannot replace cadaveric TB drilling.

### 3. Perspectives

The development of rapid prototyping in the medical field, especially in surgery, has increased during the last years. Maybe in a near future, it would allow the surgeons to perform a surgical simulation before the procedure on a patient during a pre-planning using an artificial prototype. The development of virtual simulation also increases during this period, for example, with virtual reality glasses, and we can imagine in our best dreams the future for the education of our residents and the simulation for our patients. These new tools of simulation are just waiting to be validated in order to improve safety and patient care.

### References

1. Martling AL, Holm T, Rutqvist LE, et al. Effect of a surgical training program on outcome of rectal cancer in the County of Stockholm. Stockholm Colorectal Cancer Study Group, Basingstoke Bowel Cancer Research Project. *Lancet* 2000;356:93-96.
2. Levenson MJ. Methods of teaching stapedectomy. *Laryngoscope* 1999;109:1731-1739.
3. McLachlan AD, Bligh J, Bradley P, Searle J. Teaching anatomy without cadavers. *Med Educ* 2004;38:418-424.
4. Chenebaux M, Lescanne E, Robier A, et al. Evaluation of a temporal bone prototype by experts in otology. *J Laryngol Otol* 2014;128:586-590.
5. Bakhos D, Velut S, Robier A, Al Zahrani M, Lescanne E. Three-dimensional modeling of the temporal bone for surgical training. *Otol Neurotol* 2010;31(2):328-334.



# DEFINITIONS OF DISEASE IN EUSTACHIAN TUBOPLASTY

Mahmood F. Bhutta

*School of Paediatrics and Child Health, University of Western Australia, Perth, Australia and Royal Perth Hospital, Wellington Street, Perth, Australia*

For any treatment it is necessary to define and segregate the disease(s) being treated, and evaluate effectiveness in terms of benefit to patient symptoms. Eustachian tuboplasty is a relatively new treatment for disorders of the middle ear, whose role is still uncertain.

Treatment with Eustachian tuboplasty is premised on the hypothesis that:

1. The Eustachian tube ventilates the middle ear;
2. A failure of this function leads to middle ear disease;
3. Restoration of tubal function will treat middle-ear disease.

None of these hypotheses is without controversy.

Firstly, ventilation of the middle ear is recognized to be a complex phenomenon, and not fully understood. Trans-mucosal gaseous exchange is a prominent component of middle-ear ventilation, assisted by periodic opening of the Eustachian tube to equilibrate pressures, especially when there are gross changes to ambient pressure.<sup>1</sup>

Secondly, there is actually little evidence that ventilatory failure (as opposed to immunological compromise) of the Eustachian tube leads to middle-ear disease. Studies have failed to show any consistent difference in anatomical or functional Eustachian tube parameters of children or adults with middle-ear diseases such as glue ear or tympanic membrane retraction.<sup>2</sup> Eustachian tube ventilatory dysfunction may be a contributory risk factor for such diseases, but if so it is but one component of a complex disease aetiology. Other patients describe symptoms of what is termed 'Eustachian tube dysfunction', a disorder that has recently been defined through a consensus statement.<sup>3</sup> The relationship of Eustachian tube dysfunction to otitis media is uncertain, and in clinical trials such disorders should be defined and segregated for the purposes of recruitment or outcomes analysis.

Given the controversies outlined above, it is uncertain whether Eustachian tuboplasty will be an effective treatment for various forms of middle ear disease. To date, all reported trials of Eustachian tuboplasty have suffered from either a poor definition (or conflation) of the disorders being treated (such as Eustachian tube dysfunction, glue ear, and/or tympanic membrane retraction), lack of an adequate control group, or a failure to report important outcomes. Indeed many trials have suffered from all of these deficiencies.<sup>4</sup>

Whether the Eustachian tube is or is not a pathological mechanism for middle ear diseases may be debated, but is somewhat irrelevant to the evaluation of treatment. Future trials should be conducted to appropriate standards: with randomisation, large sample sizes, clear inclusion and exclusion criteria (including segregation of disease categories) and using patient reported outcome measures. Many current trials report outcomes in terms of scoring systems, but more relevant is alleviation of a patient's hearing disability, otorrhoea, otalgia, aural fullness, or disease-specific or general quality of life. Such a strategy is critical if we are to better understand and define the role of this novel treatment.

Correspondence: Mahmood Bhutta, School of Paediatrics and Child Health, Level 4, Administration Building, Princess Margaret Hospital for Children, Roberts Road, Subiaco WA 6008, Australia  
E-mail: m.bhutta@doctors.org.uk

*Cholesteatoma and Ear Surgery – An Update 2017, pp. 31 -32*

*Edited by Matthew Yung*

*2017 © Kugler Publications, Amsterdam, The Netherlands*



## References

1. Ars B, Ars-Piret N. Morpho-functional partition of the middle ear cleft. *Acta Otorhinolaryngol Belg* 1997;51(3):181-184.
2. Bhutta MF. Eustachian tube dysfunction is not the primary causative mechanism in “glue ear”. <http://www.bmj.com/rapid-response/2011/11/03/eustachian-tube-dysfunction-not-primary-causative-mechanism-glue-ear>, 2011.
3. Schilder AG, Bhutta MF, Butler CC, et al. Eustachian tube dysfunction: consensus statement on definition, types, clinical presentation and diagnosis. *Clin Otolaryngol* 2015;40(5):407-411.
4. Randrup TS, Ovesen T. Balloon eustachian tuboplasty: a systematic review. *Otolaryngol – Head Neck Surg* 2015;152(3):383-392.

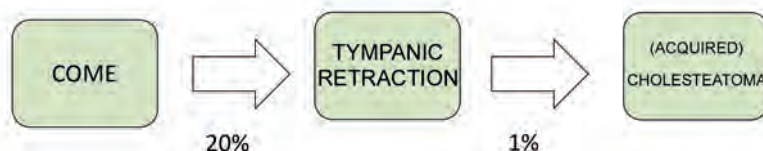# GENETICS OF CHOLESTEATOMA

Mahmood F. Bhutta<sup>1,2</sup>, Peter Prinsley<sup>3</sup>, Carl Philpott<sup>4</sup>, Barbara Jennings<sup>4</sup>

<sup>1</sup>*School of Paediatrics and Child Health, University of Western Australia, Perth, Australia;* <sup>2</sup>*Royal Perth Hospital, Perth, Australia;* <sup>3</sup>*James Paget University Hospital, Great Yarmouth, UK;* <sup>4</sup>*Norwich Medical School, University of East Anglia, Norwich, UK*

The full version of this article has been published as: The genetics of cholesteatoma. A systematic review using narrative synthesis. Jennings BA, Prinsley P, Philpott C, Willis G, Bhutta MF. *Clinical Otolaryngology*. 2017 May 9. doi: 10.1111/coa.12900.

The aetiology of acquired cholesteatoma remains elusive. Those with a history of chronic mucosal disease are susceptible, but only a few such individuals will develop cholesteatoma. Retrospective data from longitudinal studies suggest that around 20% of children with chronic otitis media with effusion (COME, glue ear) will develop tympanic membrane retraction, but only around 1% of those with a tympanic retraction will develop cholesteatoma (Fig. 1). The factors underlying transition between these disease states are unknown.



*Fig 1.* Risk of transition between phenotypes of chronic otitis media. COME = chronic otitis media with effusion.

Epidemiological data from twin studies reveal that duration with middle ear effusion in COME has high heritability. Is there evidence that susceptibility to cholesteatoma is also heritable? What methods can we use to elucidate that genetic susceptibility?

A recent systematic review by our group has looked for evidence of heritability in cholesteatoma. We found reports of familial clustering of disease, in a pattern suggestive of autosomal dominant inheritance with variable penetrance. There are also reports of cholesteatoma in monozygotic or dizygotic twins. Presence of cholesteatoma has been associated with certain syndromes, in particular congenital malformation syndromes of the head or ear, suggesting that polymorphisms in genes controlling ear embryology may be important for risk of disease.

Taken together, this evidence suggests that there is a significant but as yet unquantified genetic susceptibility to development of cholesteatoma. Methods to elucidate underlying genetic risk factors include whole genome transcript analysis to discover and analyse upregulated genes, or whole genome sequencing in affected pedigrees to enable linkage analysis

Correspondence: Mahmood Bhutta, School of Paediatrics and Child Health, Level 4, Administration Building, Princess Margaret Hospital for Children, Roberts Road, Subiaco WA 6008, Australia  
E-mail: m.bhutta@doctors.org.uk

*Cholesteatoma and Ear Surgery – An Update 2017, pp. 33 -34*

*Edited by Matthew Yung*

*2017 © Kugler Publications, Amsterdam, The Netherlands*



# MASTOIDECTOMY RECONSTRUCTION WITH TITANIUM SHEETING

Bruce Black

*Department of Otolaryngology, Lady Cilento Children's Hospital, Brisbane, Australia and Department of Surgery, University of Queensland, Brisbane, Australia*

## 1. Introduction

Complicated open cavity sites may be managed surgically in four ways: revision open surgery; mastoidectomy obliteration (cavity fill-in); external auditory canal (EAC) wall reconstruction; ablation (EAC closure).<sup>1</sup> Revision surgery may be ineffective. Obliteration may inaccessibly seal in disease. Ablation degrades hearing. Reconstruction offers the optimal method of achieving the aims of cholesteatoma surgery: disease eradication, restoration of function (hearing and EAC epithelial migration), and prevention of complications.

To achieve these, the key objectives are a well-fitted and durable wall repair layer, covered with a vascular stroma. Given these, skin healing is rapid and a satisfactory external canal lumen established. Optimally, the method used should be relatively simple in execution, versatile enough to adapt to a range of situations, and reliable in achieving these roles, whilst durable in the longer term. Previous techniques have struggled to achieve these aims for a variety of reasons.

Residual and recurrent disease necessitates Are the major complications to be avoided. These dictate an ability to re-check the cavity site, particularly the attic, at second stage surgery, and also an impervious wall repair with an absence of defects that might permit penetration by new sac formation. These were the two prime objectives of this work, which expands upon previous descriptions.

## 2. Method

Successful mastoid reconstruction is achieved in several steps:<sup>2,3</sup>

1. Transcanal tympanotomy to ensure clearance of disease from the middle ear, particularly the peri-stapedial area;
2. Creation of a middle temporal flap;<sup>4,5</sup>
3. Cavity clearance;
4. Drum and chain repair;
5. Wall repair;
6. Canal packing and wound closure.

Initially, the procedure cannot proceed successfully if the stapes and adjacent sinus tympani are not clear of squamous epithelium. Scutum reduction may be necessary for the optimal lateral approach to this area.

Creation of the middle temporal flap<sup>4,5</sup> (MTF) should be done at the initial post-aural incision, elevating the flap and fixing it anteriorly to enable cavity clearance without flap trauma. The flap should be created as long as possible and approximately four cm wide along the line of the supramastoid crest.

Correspondence: Dr. Bruce Black, 6/101 Wickham Terrace, Spring Hill, Brisbane, Queensland, Australia 4000  
E-mail: bruceblackmd@bigpond.com

*Cholesteatoma and Ear Surgery – An Update 2017, pp. 35 -38*

*Edited by Matthew Yung*

*2017 © Kugler Publications, Amsterdam, The Netherlands*

The cavity is cleared back to healthy bone, sparing sufficient skin flaps to line the new canal. This may not be possible with atrophic lining, but the flap vasculature stimulates rapid re-epithelialization within the new EAC. Beveling the cavity just postero-superiorly to the external canal may offer extra length; the MTF will contract considerably.

Once cavity clearance is complete, retention grooves are cut into the root of the zygoma and along the facial ridge. If the ridge has been lowered to the facial nerve, a notch in the mastoid tip suffices. The site is then ready to size and shape the titanium sheeting (.012 mm, annealed, light tight, Goodfellow, Cambridge), using a stiff aluminium foil template.

The wall defect is not a wedge shape, but rather a curved section of a cone. The repair therefore takes the shape of a hemi-ellipse, 2.5-3 x 1.5 cm, twisted rather than curved, to follow the line of the EAC defect. The template is tried in the site until a precise fit is obtained, then the titanium is cut to shape with heavy scissors and tried *in situ*.

Drum repairs are then undertaken with a composite cymba conchae cartilage-perichondrium graft, used to prevent drum re-collapse. The chain is repaired (our preference is an Alto PORP/TORP - Grace Medical, Memphis). A fine strip of Allevyn (Smith and Nephew, Hull) is placed on the drum and onto the anterior EAC wall for stability and to aid canal packing later. The cavity skin flaps are sited over this strip, squamous epithelium anteriorly.

The MTF is then swung medially, its calvarium surface facing the EAC lumen and completely covering the defect. In three cases, composite grafting was used to supplement the MTF in the anterior attic, in cases where the body tissues were somewhat delicate. The titanium is then fitted into the retention grooves. If slightly unstable, a U-clip made of a strip of titanium is wedged in for support. These clips are easily removed if second stage inspection is required.

The EAC skin flaps are positioned over the MTF via a transcanal approach (the strip on the anterior wall helps this step). Further Allevyn strips complete the packing, and the wound is closed.

### 3. Results

Titanium sheeting was used in 35 cases from 2008-2014. The average follow-up was 26 months, ranging from six to 60 months. The shorter duration cases were from distant sites. Whilst follow-up reports by the referring otologists were available in these cases, the inspections were not undertaken personally and therefore excluded from our data.

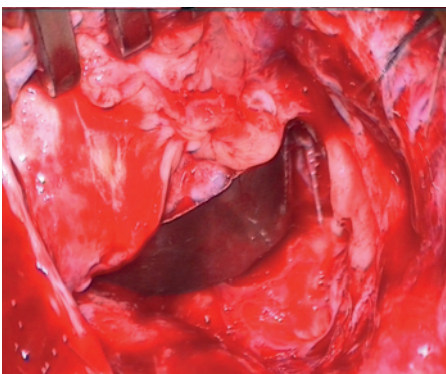


Fig. 1. Titanium sheeting wall in situ. Second stage surgery 12 months after initial cavity repair, demonstrating the access to the attic, which is essential to allow re-inspection for residual disease in this area.

Modified radical repairs were undertaken in 16 cases and in radical sites in 19. Second stage surgery was performed in 29 (83%), 12 months after initial surgery, to inspect for residual disease (Fig. 1). Non-staged cases had thick mastoid cavity lining, with corresponding little risk of residual disease.

Residual disease was detected in 4 cases, all in the attico-mastoid area, and eliminated without event.

Recurrent cholesteatoma occurred in three cases. One was invagination into the mesotympanum. The other two cases involved sac formation around the anterior edge of the repair due to poor insertion of the implant into the retention groove in the anterior attic. Both were corrected at second stage surgery using an implant removal and resiting after repair of the site with a composite graft. There were no instances of soft tissue breakdown over the sheeting itself.

Myringitic EAC patches occurred in three cases, treated successfully by wet scouring, 5% chlorhexidine application and subsequent ciprofloxacin drops.

#### 4. Discussion

The above technique derives from previous work that included successive but less successful methods,<sup>1-3</sup> the notable prior difficulties being a stable but ‘user-friendly’ wall material and the vascular supply of the reconstruction. The former included bone (difficult to shape, availability) homograft cartilage (resorption, prion concerns), hydroxylapatite (brittle, rigid, infection-prone).<sup>1</sup> The latter problem was solved by the author’s development of the middle temporal flap.<sup>4</sup>

Titanium sheeting was first used by Magnan and Chays<sup>6,7</sup> in this role, in a pre-formed prosthesis. The sized and shaped commercial sheeting however, adapts well, in both this and other EAC repair roles.<sup>8</sup>

The remaining minor recurrence rates may also diminish with better familiarity with the technique. The absence of other major concerns bodes well.

The sheeting proved superior to the use of titanium mesh, which resulted in dehiscence rates that precluded continued use (unpublished data). Combined with the MTF, the sheeting achieves a healthy self-cleaning EAC (Fig. 2).

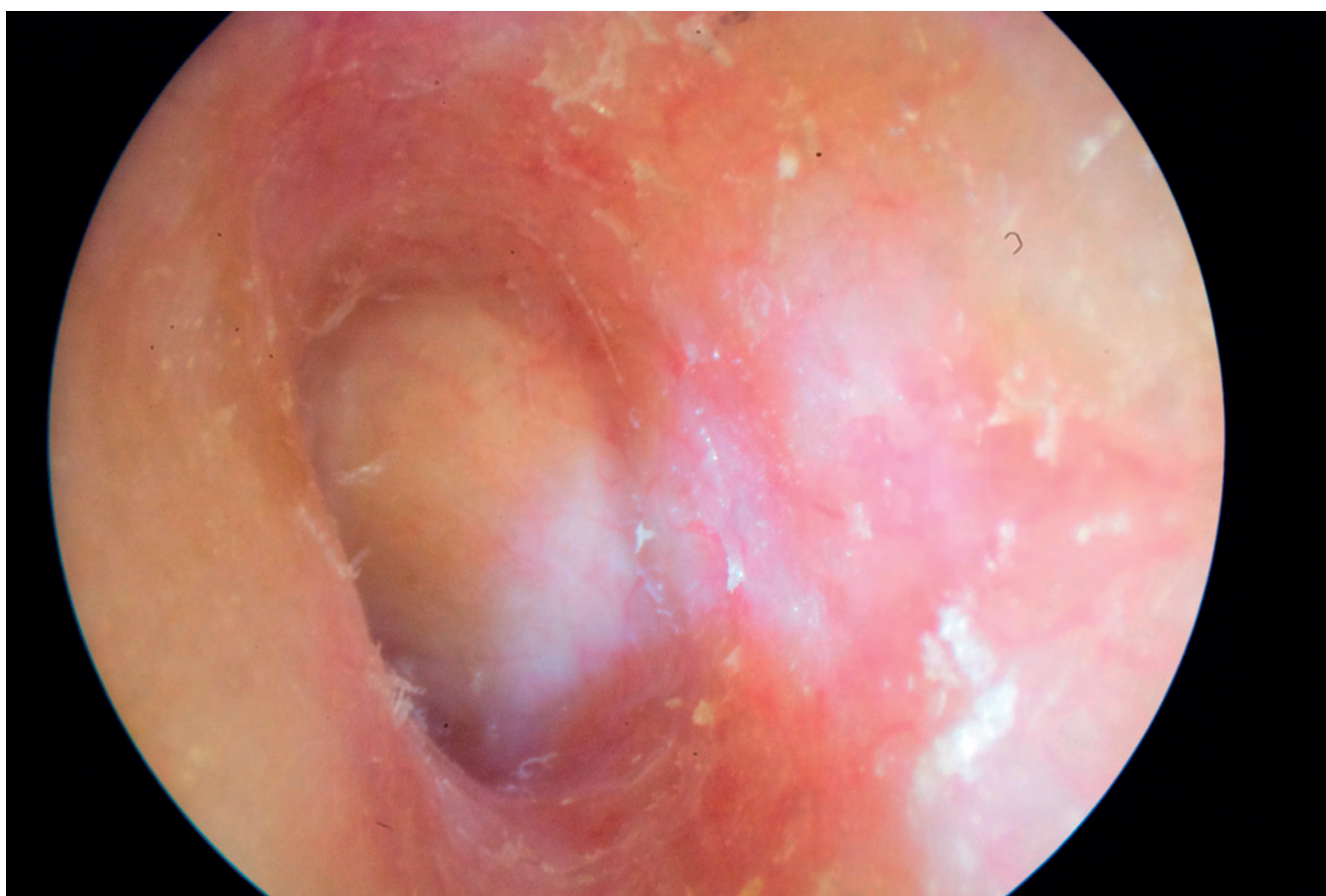


Fig. 2. Postoperative EAC. A healthy self-cleaning lumen is present. The drum repair used a total cymba conchae composite graft.

#### 5. Summary

Reconstruction with the titanium sheeting in combination with the middle temporal flap has proven a reliable and not difficult method of radical cavity canal wall repair. Greater details are available in the Educational Portal of our website [www.queenslandotology.com.au](http://www.queenslandotology.com.au).

## References

1. Black B. Mastoidectomy elimination: obliterate, reconstruct or ablate? *Amer J Otol* 1998;19(5):551-557.
2. Black B. Mastoidectomy elimination. *Laryngoscope* 1996;105(12)(Supp. 76):1-30. (Online: see end of December issue).
3. Black B. Mastoidectomy reconstruction: problems and solutions. In: Magnan J, Chays A (eds.), *Proceedings of the sixth international conference on cholesteatoma and ear surgery*, Cannes 2000, pp. 813-829. Marseille, Label Production 2001.
4. Black B, Kelly S. Mastoidectomy reconstruction: revascularizing the canal wall repair. *Am J Otol* 1994;15(1):91-95.
5. Black B. The use of vascular flaps in middle ear surgery. *Amer J Otol* 1998;19(4):420-427.
6. Magnan J, Chays A, Gignac D, Bremond G. Reconstruction of posterior canal wall: long-term results. In: Charachon R, Garcia-Ibanez E (eds.), *Long-term results and indications in otology and otoneurosurgery*, pp. 57-61. Amsterdam/Milano/New York: Kugler & Ghedini Publications 1991.
7. Magnan J, Chays A, Pencroff E, Locatelli M, Bruzzo M. Canal wall prosthesis: new devices. *Rev Laryngol Otol Rhinol (Bord)* 1995;116:19-21.
8. Black B. Use of Titanium in Repair of External Canal Defects. *Otol Neurotol* 2009;29:930-935.



# KEYHOLE COCHLEAR IMPLANT SURGERY: ADAPTATION FOR MED EL SOUNDBRIDGE AND BONEBRIDGE DEVICES

Bruce Black

*Department of Otolaryngology, Lady Cilento Children's Hospital, Brisbane, Australia and Department of Surgery, University of Queensland, Brisbane, Australia*

## 1. Introduction

Keyhole cochlear implant (CI) surgery,<sup>1-3</sup> evolved from previous more extensive procedures, for purposes similar to surgical trends in other disciplines. The technique focussed on reduction of surgical technique to the bare minimum to achieve a raft of aims:

1. Minimal patient impact
  - b. Little tissue damage, blood loss, overall patient impact;
  - c. Brief surgery; especially in the infant.
2. Safety/Infection
  - a. Neurovascular structures avoided;
  - b. Wound avoids the implant body/electrode array;
  - c. Wound tension avoided;
  - d. No bony retention well;
  - e. Minimal mastoidotomy;
  - f. Wound in the highly vascular auricular skin;
  - g. No diathermy;
  - h. Minimal wound exposure, desiccation;
  - i. Minimal scalp anaesthesia.
3. Cosmesis/Aesthetics/Psychology
  - a. Minimal and covert scarring;
  - b. No head shaving;
  - c. Minimal parental distress (small infants);
  - d. Optimal for bilateral simultaneous surgery in infants;
  - e. Optimal second side take-up.

The technique has proven effective and safe, reducing OT times and avoiding significant complication rates. In particular, implant migration (which has been the reason for more 'open' techniques) has been rare, and now evidently effectively countered.

Similar measures were adapted for The Med El Soundbridge (VSB) and Bonebridge devices. Surgery outlined in the manufacturer's literature for these implants described more traditional open exposure techniques including skin flaps, bony retention wells, sutures and troughs cut into the mastoid. Both devices, however, respond to Keyhole techniques to achieve similar ends.

Correspondence: : Dr. Bruce Black, 6/101 Wickham Terrace, Spring Hill, Brisbane, Queensland, Australia 4000.  
E-mail: bruceblackmd@bigpond.com

*Cholesteatoma and Ear Surgery – An Update 2017, pp. 39 -42*

*Edited by Matthew Yung*

*2017 © Kugler Publications, Amsterdam, The Netherlands*



## 2. Method

Keyhole CI surgery<sup>2,3</sup> is performed via a two-cm diameter C-incision on the rear of the auricle, the midline being at the level of the round window. The adjacent auricular and post-aural skin is widely undermined in the avascular plane between skin and underlying periosteum. This mobilizes the incision for better access; continual visualization of the entire field is unnecessary. A Palva-type pinna-based mastoid periosteal flap is raised to expose the upper mastoid.

A pocket is developed between pericranium and calvarium postero-superior to the mastoid. The lower entrance is bevelled to facilitate the introduction of an implant blank, used to judge the correct snug pocket size, the lower edge of the implant being 1.5-2 cm from the auricular sulcus.

A limited mastoidotomy is then created in the suprameatal triangle, leading directly to the antrum. Within, the “stalagmites” in the normal site lead directly to the lateral semicircular canal, the critical landmark.<sup>2</sup> Sequential identification of the posterior geniculate artery, the descending facial nerve and the chorda tympani permit creation of a posterior tympanotomy that effectively displays the round window, followed by a cochleostomy/round window membrane incision, as required.

The implant is then sited in the pericranial pocket, and the array is passed into the cochlear spiral. For further implant stabilisation, a 3/0 plain gut percutaneous suture is passed around the neck of the array under direct vision. This is left to dissolve spontaneously, by which time tissue fibrosis effectively stabilises the implant *in situ*.

The periosteal pinna flap is then laid over the array, the wound is closed with 5/0 soluble plain gut suture and a head bandage applied for one week.

The technique was mainly used with Cochlear devices, with a small minority of Med El implants.

VSB implantation varies from the above in two ways. Firstly, the posterior tympanotomy is widened as much as possible to expose the long process of the incus and stapes, to permit passage of the floating mass transducer (FMT) through the tympanotomy, then fixation on to the long process. Fixation is facilitated by holding the FMT on the tip of a fine sucker, using the innate magnetic pull, and positioned to anticipate that the fixation ‘jaws’ of

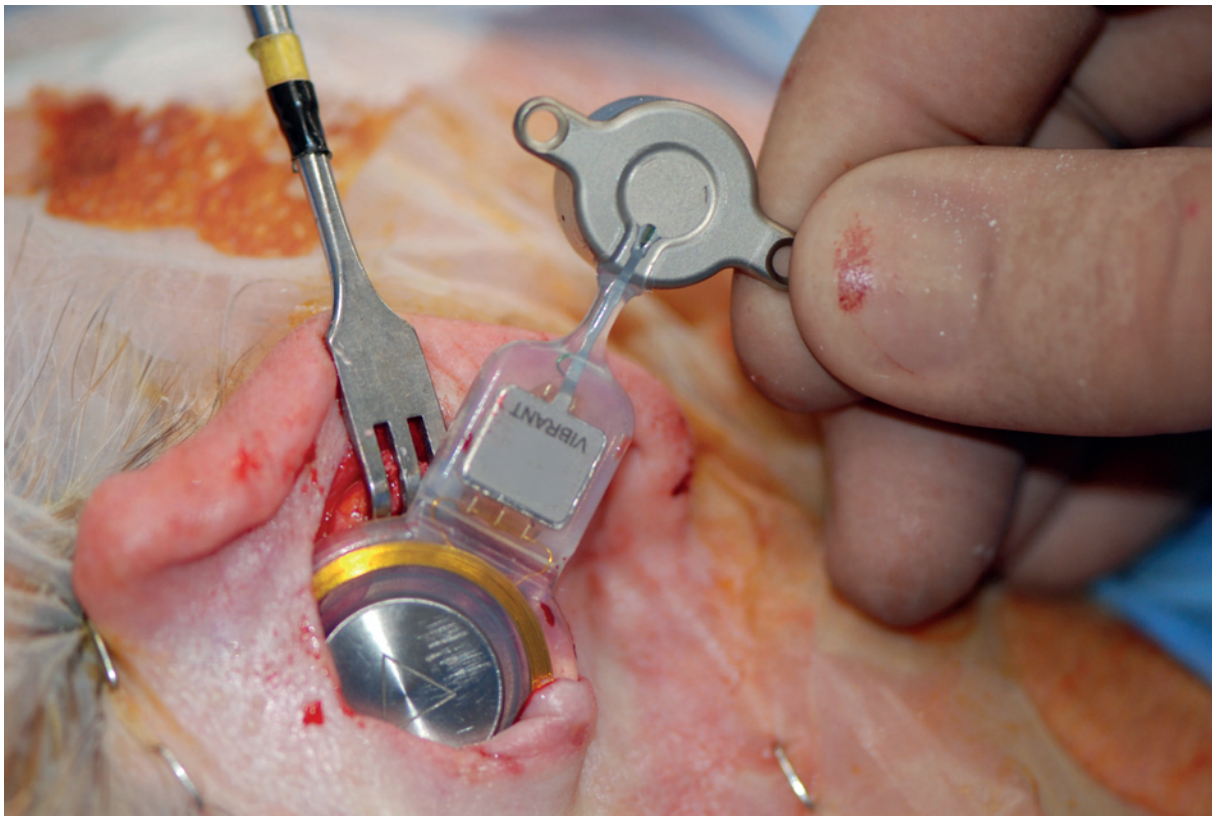
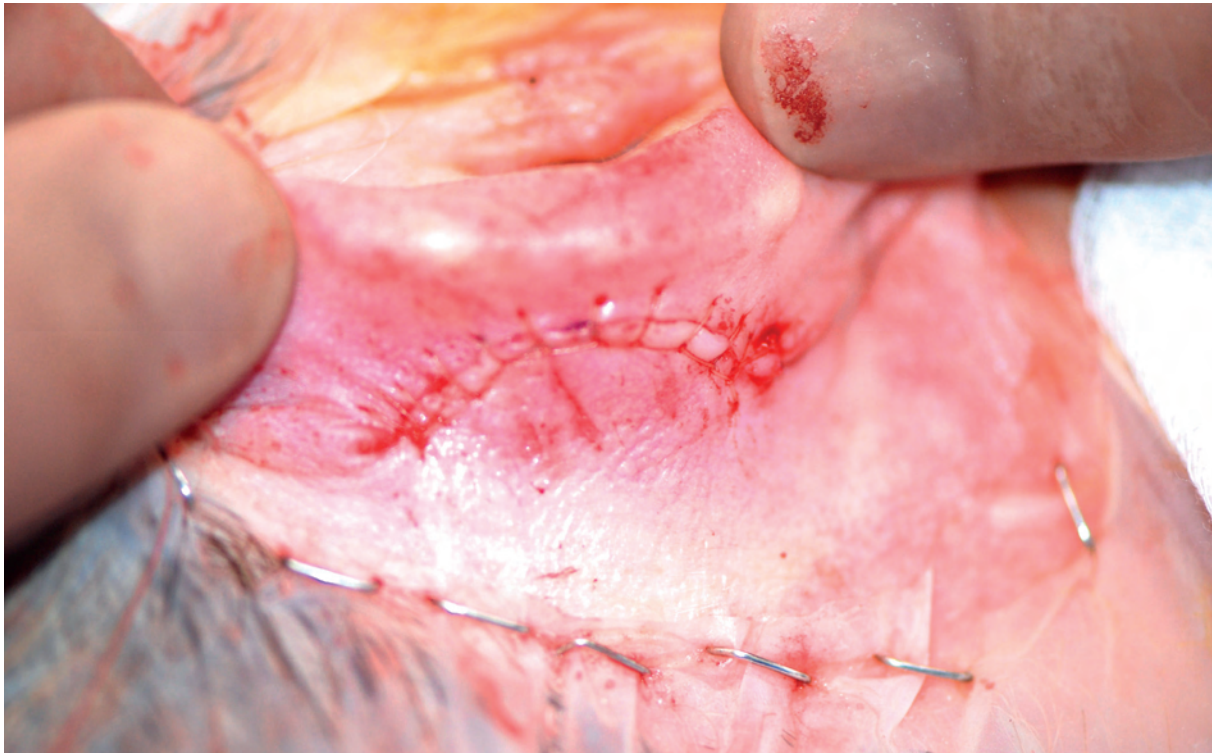

Fig. 1. Use of the Keyhole technique with the Bonebridge implant. Device insertion into the pericranial pocket.



*Fig. 2.* Incision used for the Bonebridge implant. The diameter of three to four cm is slightly larger than that used for CI or VSB devices.

the device may be guided onto the incus without other positioning. Once on the long process, The FMT is then detached off the sucker with a titanium needle and the jaws are clamped. In a small number of cases, fixation may be aided via trans-canal tympanotomy inspection. Percutaneous suture fixation around the implant neck is used for these devices also.

Bonebridge implantation requires different adaptations. Due to the bulk of the transducer barrel, the wound diameter is enlarged to three to four cm (Figs. 1, 2). The mobility of the incision permits adequate access for bed drilling and device fixation. The transducer is covered with the pinna-based flap.

In addition, the pericranial pocket is widened considerably to allow greater mobility that facilitates device siting during fixation. Positioning is also aided by (pre-insertion) accurately assessing the degree of angulation of the neck of the device required to site the device precisely over the retention screw holes upon insertion into the well. Suture fixation is unnecessary as the implant is screwed on to the bone.

### 3. Results

From 1997, the CI technique has been employed in over 600 cases. Functionally, the cases achieved the expected outcomes. Two infections occurred, one implant being lost (in a 92-year-old male). One case developed an auricular keloid.

The main concern was implant body migration, a low incidence being previously reported. This phenomenon was successfully countered, initially using titanium 'bridges',<sup>3</sup> but more recently by the percutaneous suture method, which proved simple and effective. Any haematomas were mild and self-resolving. Surgical times average 30 minutes in uncomplicated cases. Four cases required enlarged posterior tympanotomy access, the scutum defect being repaired with readily available conchal bowl cartilage. One facial paresis resulted from acute otitis media, and transient pareses were noted in two other cases.

Soundbridge implants were used in 28 cases. Difficulties in this group were confined to four electronic failures, managed with three (successful) re-implantations.

Additional transcanal exposure was required in two cases to aid fixation on to the incus.

Bonebridge implantations were done in 32 cases. Of these, 31 were successful, the sole disappointment being in a single-sided profound loss where the outcomes in noisy circumstances did not meet patient expectation. The enlarged pericranial pocket caused no tangible problems. The torque wrench recommended by the manufacturer seemed superfluous.

#### 4. Discussion

Traditionally, CI and other implant surgery have used wider exposure surgery, partly to enable fixation of the device to the skull by a variety of methods that included drilling bony retention wells.<sup>4</sup> By its nature, such surgery destabilised the overlying tissues, reinforcing the need for such fixation. Since, the trend has been to avoid open surgery<sup>4,5</sup> and to use other means such as pericranial pockets to retain the device.<sup>7,8</sup>

The Keyhole philosophy aimed to reduce the surgery to the minimum, avoiding techniques that required more extensive intervention and thus longer surgical times. This series found that fixation can be achieved with relatively simple methods, with reduced times and minimal morbidity.

As with minimalist approaches in other disciplines, the reduced access requires a surgical 're-think', but in the majority of cases, implant surgery is more a limited anatomical dissection than a disease-management technique. As such, avoidance of complex measures and reduction of the surgery to the essentials may be the norm rather than the rule.

#### 5. Summary

The Keyhole technique proved effective in achieving the raft of objectives outlined in the Introduction. A key part of the method is the mobilisation of the wound by undermining the surrounding skin, which provides wide access with minimal constant exposure, little tissue trauma, and limited operating times.

#### References

1. Black B, Black J, Wallwork B. Early paediatric implantation: Cochlear implant surgery at the crossroads? *Med J Otol* 2005;2:94-103.
2. Black B. Keyhole cochlear implantation surgery. *Cochlear Implants International* 2009;10(3):150-159.
3. Black B. Keyhole Cochlear Implant Surgery: Current status. *Otol Neurotol* 2011;32(9):1459-1463.
4. Clark GM, Blamey PJ, Brown AM, et al. The University of Melbourne Nucleus multi-electrode cochlear implant. *Adv Otol Rhinol Laryngol* 1987;38:94-112.
5. Gibson WPR, Harrison HC, Prowse C. A new incision for placement of cochlear implant. *J Laryngol Otol* 1997;111:924-927.
6. O'Donoghue GM, Nikopolous TP. Minimal access surgery for paediatric cochlear implantation. *Otol Neurotol* 2002;23:891-894.
7. Balkany TJ, Whitley M, Shapira Y, et al. The temporalis pocket technique for cochlear implantation: an anatomical and clinical study. *Otol Neurotol* 2009;30:903-907.
8. Molony T, Giles J, Thompson TL, Motamedi KK. Device fixation in cochlear implantation: is bone anchoring necessary? *Laryngoscope* 2010;120:1837-1839.

# PROGNOSTIC FACTORS IN PAEDIATRIC COCHLEAR IMPLANTATION: DEFINITION, LOCATION, EVALUATION

Jane Black<sup>1</sup>, Bruce Black<sup>2</sup>

<sup>1</sup>*School of Health and Rehabilitation Sciences, University of Queensland, St Lucia, Brisbane, Australia;*

<sup>2</sup>*Department of Otolaryngology, Lady Cilento Children's Hospital, Brisbane, Australia and School of Medicine, University of Queensland, St Lucia, Brisbane, Australia*

## 1. Introduction

Why prognosticate in paediatric cochlear implantation (PCI)? Firstly, an accurate and comprehensive assessment is the basis for successful outcomes and in turn the prognosis is dependent on the presence or absence of factors that may prevent an optimal outcome. Secondly, preoperative prognostic information is essential for successful family counselling in the lead-up to PCI.<sup>1</sup> There are three aspects relevant to the prognostic process in PCI. These are description – a clear definition of prognostic threats; distribution – where these threats will act along the auditory pathway; evaluation – what is the impact of both the individual and cumulative prognostic factors/threats present in each case?

## 2. Threat description

In an extensive literature review identification of validly studied, prognostic factors proved difficult with only four found; meningitis, inner ear abnormalities, age at implantation and GJB2 mutations (Connexin 26 – neutral effect).<sup>2</sup> Further work demonstrated that the initial three substantiated adverse factors were inadequate for accurate clinical prognostication or related research purposes.

There were several recurrent descriptive problems; use of aetiology (meningitis, Cytomegalovirus (CMV)), ill-defined terms (inner ear malformations), ambiguous terms (age at implantation), inaccurate descriptions (Auditory Neuropathy Spectrum Disorder vs. true eighth nerve pathology). For example, when we studied the children in our series for the effect of meningitis, we found that the group contained dissimilar pathology<sup>3,4</sup> – well children had excellent or good results, whereas central nervous system damaged children had different pathology and lesser results. Therefore, the caseload was heterogeneous. Equally, examination of inner ear malformations showed that those children with enlarged vestibular aqueducts had a good prognosis whereas a malformed cochlea may not accept the electrode array and had a suspect prognosis.<sup>5</sup> Furthermore, age at implantation proved to be an ambiguous descriptor with the cases needing to be divided into the very young (early cortical stimulation via the cochlear implant), the prior-stimulated (the child became deaf after 24 months with the cortex being normally stimulated during this time), or the older never stimulated groups (deaf from birth and implanted after 24 months).<sup>6,7</sup> Therefore, threat description in the past literature showed poor scrutiny of the relevant threats to cortical function and had an inadequate focus on the pathology. This degraded the quality of the data used, thus demonstrating that a more precise evaluation of prognostic threats is needed.

Correspondence: Jane Black, 6/101 Wickham Terrace, Brisbane, Australia 4000.  
E-mail: jblack@bigpond.com

*Cholesteatoma and Ear Surgery – An Update 2017, pp. 43 -46*  
*Edited by Matthew Yung*  
2017 © Kugler Publications, Amsterdam, The Netherlands



### 3. Threat distribution

An important factor in prognostication in PCI is to visualize the threat and how it will impact on ability – this requires two steps. Initially, to identify the exact mechanisms of the site and nature of the pathological effect on the auditory pathway and secondly, to understand the action of those threat(s) on pathway function from the implant itself to the auditory cortex. Of significance, the cortex is the ultimate site of success or failure in PCI as cortical function (and thus the prognosis) may be degraded in two ways – damage to the cortex itself or denial of the data.<sup>8,9</sup> The latter occurs either by impeded maturation (this is because the brain depends on auditory stimulation, of particular importance in the first two years of supply) or interruption of input, *e.g.*, damage to the brain itself in cases of CMV, cerebral palsy, meningitis or hypoxia.<sup>10,11</sup> Consequently, success in PCI must be viewed through the prism of the cortical effect.

If the degradation of cortical function is broken down into domains we have a variety of effects on PCI. The anatomical distribution of perceived major causes of problems fell into three groups: **primary** influences (central nervous system), **secondary** influences (cochlea and eighth nerve) and **tertiary** influences (extracorporeal). These anatomical effects are further sub-grouped into six domains of function; *cortical maturation* and *neurological damage* (primary domain); *otological* (secondary domain); *general medical, psychological* and *family/social* (tertiary domains).

### 4. Threat evaluation

Multiple adverse factors have the potential to cause less than optimal results in PCI – a method to assess these factors both individually and cumulatively was developed. This prognostic assessment process provided a technique that enables the clinician to study both isolated prognostic factors and multiple factors which when present may span several domains. This process offers a flexible technique and is particularly useful in the multi-handicapped case. It facilitates the ability to judge the accumulative threats in all domains and to gain a prognostic rating (Table 1).

Table 1. Prognostication method.

<b>1. Identify individual threats and list each factor in the relevant domain affected</b>	<b>2. Assess individual threat probability</b>  The clinically assessed likelihood that the threat will affect the PCI outcome:  1. Minimal 2. Possible 3. Probable 4. Certain	<b>3. Assess individual threat severity</b>  Clinical estimation of the severity of the perceived threat:  1. Minimal 2. Slight 3. Substantial 4. Severe
<b>4. Overall individual threat assessment</b>  <b>Likelihood x severity.</b> The scores are then re-classified, 1-4, minimal to maximal risk:  1. Minimal threat: 1-4 2. Some threat: 6, 8 3. Considerable threat: 9,12 4. Major threat: 16	<b>5. Individual domain rating</b>  Threats within the domain are tabled. <b>Combined effect</b> is calculated 1-4, minimal to maximal, using the three assessments listed below  1. Rate according to worst threat 2. Two '3' threats = 4 3. Three '2' threats = 3	<b>6. Combined domain rating: Prognosis</b>  Domains are tabled, <b>assess prognosis</b> as per prior box, 1-4  1. Excellent prognosis 2. Good prognosis 3. Fair prognosis 4. Poor prognosis

#### 4.1 Sample case study

A child, aged nine months, with congenital CMV presents with profound bilateral sensorineural deafness from birth. Magnetic resonance imaging demonstrates significant pathology and poor motor skills are evident. There is probable reduced intellect, suspect cognition, delayed milestones and a disruptive family with a history of poor compliance.

Application of the case prognostication method is demonstrated in Table 2.

Table 2: Case prognostication - Combined Domains Assessment (Prognosis)

Domain	Factor	Threat probability	Threat severity	Overall threat rating	Comment	Domain rating	Prognosis  4
Auditory cortex	CMV damage	3	2	2	Some threat	2	
Neurology	MRI – CMV changes	3	3	3	Considerable threat	3	
	Poor motor skills	3	2	2	Some threat		
Otology	Nil	1	1	1	Minimal threat (EABR normal)	1	
General medical	Nil	1	1	1	Minimal threat	1	
Psychology	Reduced intellect	3	2	2	Some threat	3	
	Delayed milestones, poor cognition	3	3	3	Considerable threat		
Family / Social	Disruptive family	3	3	3	Major threat	4	
	Poor compliance	4	3	3			

## 5. Specialized tools

To enable the use of the prognostication method, a number of specialized tools were developed. These were for both prognostication and auditory performance measurement.

### 5.1 Prognosis: Family assessment profile

This profile was derived from the Nottingham Children's Implant profile (NChIP) and is used to classify the possible impact of the family situation on both prognosis and outcome. It has several units of analysis: family structure/support; history of hearing loss/impact on family or child; understanding of the CI process/family expectations; compliance/commitment aspects. It allows a grading to be developed: grade 1 = no concern; grade 2 = mild concern; grade 3 = great concern. This family assessment approach is also useful to mitigate any potential perceived risks pre-operatively.

### 5.2 Prognosis: Cochlear Implant Paediatric Prognostic Index (CIPPI)

The CIPPI is a prototype prognostic index intended as a reference tool during PCI prognostication. It provides a framework for the evaluation of isolated or multiple adverse factors based on the literature, therefore it is evidence-based.<sup>12</sup> This tool combines a comprehensive 'check list' which enables PCI clinicians to fully understand the prognosis based on both diagnostic and assessment information.

### 5.3 Outcomes: Categories of Auditory Performance Index (CAPI)

The CAPI is an index of performance categories arranged in increasing ability based on the child's performance on tests of auditory perception. It has nine descriptive categories ranging from nil or limited awareness to advanced

open set speech perception in noise on auditory perception test performance. It succeeds the Nottingham Categories of Auditory Performance (CAP), is objective, repeatable and a valuable research tool. The CAPI is thus a 'Rosetta Stone' for such purposes. It provides a means of data comparison by giving a grading of outcomes, is adaptable to all assessment techniques and enables retrospective research without patient recall.<sup>13</sup>

## 6. Conclusion

PCI prognostication requires precise evaluation of the site, pathology and action of adverse factors/threats evident in an individual case. The focus should be on the specific pathology of the threats and vague terminology/descriptors should be avoided. When assessing a PCI prognosis, it is essential to examine the auditory pathway systematically for evident prognostic threats. Importantly, each case is a clinical judgement; the balance depends on factors specific to the individual child and the CI team.

## References

1. Black J, Hickson L, Black B. Defining and evaluating success in paediatric cochlear implantation – an exploratory study. *Int J Pediatr Otorhi* 2012;76(9):1317-1326.
2. Black J, Hickson L, Black B, Perry C. Prognostic indicators in paediatric cochlear implant surgery: a systematic literature review. *Cochlear Implants Int* 2011;12(2):67-93.
3. Nichani J, Green K, Hans P, et al. Cochlear implantation after bacterial meningitis in children: outcomes in ossified and nonossified cochleas. *Otol Neurotol* 2011;32(5):784-789.
4. Philippon D, Bergeron F, Ferron P, Bussieres R. Cochlear implantation in postmeningitic deafness. *Otol Neurotol* 2010;31(1):83-87.
5. Zhihua Z, Yun L, Lingxiang H, et al. Cochlear implantation in children with cochlear nerve deficiency: a report of nine cases. *Int J Pediatr Otorhi* 2012;76(8):1188-1195.
6. Britz A, Fry L, Owston K. Paediatric cochlear implant outcomes for children switched on under 2 years, over 2 years and those with complex needs. *Cochlear Implants Int* 2010;11(S2):94-98.
7. Artieres F, Vieu A, Mondain M, Uziel A, Venail F. Impact of early cochlear implantation on the linguistic development of the deaf child. *Otol Neurotol* 2009;30(6):736-742.
8. Fallon J B, Irvine D R F, Shepherd R K. Cochlear implants and brain plasticity. *Hearing Res* 2008;238(1-2):110-117.
9. Dettman SJ, D'Costa WA, Dowell RC, et al. Cochlear implants for children with significant residual hearing. *Arch Otolaryngol Head Neck Surg* 2004;130(4):612-618.
10. Lee DJ, Lustig L, Sampson M, Chinnici J, Niparko JK. Effects of cytomegalovirus (CMV) related deafness on pediatric cochlear implant outcomes. *Arch Otolaryngol Head Neck Surg* 2005;133(6):900-905.
11. Steven RA, Green KMJ, Broomfield SJ, et al. Cochlear implantation in children with cerebral palsy. *Int J Pediatr Otorhi* 2011;75(11):1427-1430.
12. Black J. Prognostication in paediatric cochlear implantation: principles and practice. [thesis]. The University of Queensland: School of Health and Rehabilitation Sciences 2013.
13. Black J, Hickson L, Black B, Khan A. Paediatric cochlear implantation: adverse prognostic factors and trends from a review of 174 cases. *Cochlear Implants Int* 2014;15(2):62-77.



# INTEGRATING ENDOSCOPY INTO EVERYDAY OTOLOGY PRACTICE

Jose Carlos Casqueiro

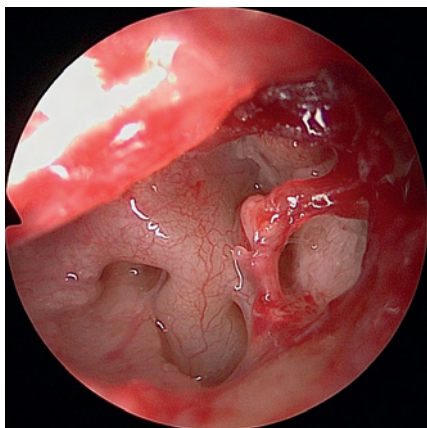
*Hospital Universitario Severo Ochoa, Leganes, Comunidad de Madrid, Spain*

## 1. Introduction

Although endoscopes are not new for otologists, the use of the endoscope to perform otologic surgery is still debated and its indications must be defined. Initially, the endoscopes were used mainly for diagnosis in the office and all otologic surgery was performed exclusively with the operating microscope. Although some surgeons began to use the endoscope as operating tool in the early 90's with some success,<sup>1,2</sup> it was not until technological development (mainly in medical imaging) that endoscopic ear surgery (EES) has rapidly spread worldwide.

## 2. Why you should consider using endoscopes in otologic practice

Transcanal approaches sometimes can be very limited and a canalplasty may be required, especially in pediatric population. In some other cases, like complex middle ear disease a retro-auricular approach with a canal wall-up



*Fig. 1. 0° endoscope offers a straight-on panoramic view of the middle ear.*

mastoidectomy associated with a posterior tympanotomy is needed to control the middle ear cleft. The use of the endoscope increases the visualization of the middle ear cleft, without the need of a canalplasty or an unnecessary mastoidectomy. Furthermore, because of the properties of rigid endoscopes, light source would never be obstructed by the external auditory canal and we could always see the distal tip of the instruments while performing dissections. With an angulated wide field endoscope, we can also reach occult recesses as retro-tympanic sinuses and modern high definition cameras offer crystal-clear images with sharp detail that are even better than the microscope which facilitates the teaching experience (Fig. 1). The use of endoscopes expands the indications of the transcanal approach that now can be applied in more complex middle ear disease as attic cholesteatoma.

## 3. Endoscope selection

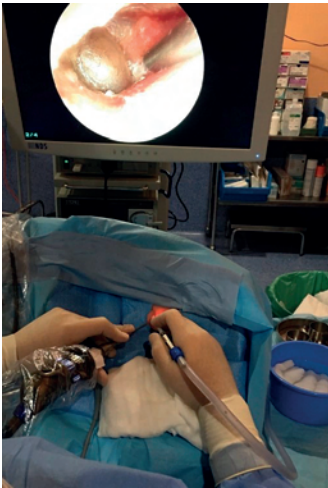When it comes to endoscope selection it all depends on the choice of the surgeon. As a rule, the wider the endoscope, the bigger the image and more light reaches the endoscope's distal tip. That also implies more heat at the tip of the endoscope, so watch out the intensity of your light source. We generally prefer to use a long and wide diameter endoscope like a 14-cm long, three-mm wide nasal pediatric endoscope. The main advantage of using long endoscopes is that they do not interfere with the dominant hand when working in a limited space like the external auditory meatus. In our experience, 14 cm is long enough to not interfere with the other hand and a width

Correspondence: José Carlos, Euterpe 17 28022 Madrid Madrid Spain  
E-mail: jccasqueiro@gmail.com

*Cholesteatoma and Ear Surgery – An Update 2017, pp. 47 -50*

*Edited by Matthew Yung*

*2017 © Kugler Publications, Amsterdam, The Netherlands*



*Fig. 2.* The video display should be placed 10 to 25° below surgeon's eye level. The scrub nurse is placed at the head of the bed. Notice hand position.

of three mm is a good compromise between a small size and a big image (Fig. 2). Almost all our cases are performed with a 0° endoscope. In some cases, particularly when we need to control occult retrotympanic recesses or when the disease reaches the posterior attic we also use a 45° endoscope to ensure the complete removal of the disease.

#### **4. Choose your first cases in endoscopic ear surgery well**

When starting out with endoscopic ear surgery, we recommend to begin with easy cases that could be done through a transcanal approach with a microscope, like dry posterior perforations or grommet insertion. Sometimes the most difficult stage of the surgery is at the beginning of the procedure, when raising the tympanomeatal flap. If necessary, this stage can be performed under microscopic view and when the middle ear is reached, the endoscope can be used.

Once you are more comfortable and confident with the endoscope and have learned how to use the instruments under endoscopic view, it is time to progress to more challenging surgeries like anterior marginal perforations, posterior atelectasis or limited attic cholesteatomas. Always avoid ears with inflammatory disease or granulation tissue because in these cases more bleeding is expected. Mesotympanic or limited attic cholesteatoma lateral to the ossicles are the easiest cases to deal with, and we recommend to first attempt these cases before more experience in this approach is obtained.

It is important to remember that in EES the field of view is different than that with a microscope and the surgeon must adapt to it. Wide field images tend to magnify the peripheries of the image and some measures can be compromised and misjudged, such as the amplitude of the tympanomeatal flap. In some other cases the paradox occurs when the endoscope allows you to see, but not allow to work, because of the lack of dedicated angled instruments. In cases that a complication is expected (dehiscent high jugular bulb, a lateral semicircular canal fistula, a middle fossa encephalocele...), it is better and more safe to approach these with the microscope. It is advisable to perform a preoperative CT scan and even a MRI to rule out these complications before selecting what approach is better in each single case.

Finally, we recommend the inexperienced surgeon to begin with left sides (if the surgeon is right-handed) because the position of the endoscope in the inferior part of the external auditory canal will make it easier to use instruments in the mesotympanum or the attic.

#### **5. Prepare yourself for a long learning curve**

The main drawback of the EES is that it is a one-handed technique. The no dominant hand must hold the endoscope steadily and in our experience, we cannot preclude the use of external holders to avoid it. This is because of the potential risk of damage to the patient if he makes an unexpected movement during surgery and because of the limitation that a holder makes to our movements inside the external auditory canal. Given the fact that to obtain a pseudo tri-dimensional perspective of the middle ear cleft we need to move the endoscope forward and backward (in the same manner that we do in sinus surgery) it is better to have the endoscope free to move.

Although experienced surgeons will not require any special training to begin with the endoscope, moreover if they have any experience in endoscopic sinus surgery, it is advisable to attend to an endoscopic-focused temporal bone course to gain some skill. There are several courses based in fresh-frozen or partially preserved (Thiel method) specimens, that permits to master the one-handed technique. A relatively easy maneuver like raising a tympanomeatal flap, can be challenging even to experienced otologic surgeons because they are used to perform

this stage of the surgery with both hands. EES like any other surgery is all about practice.

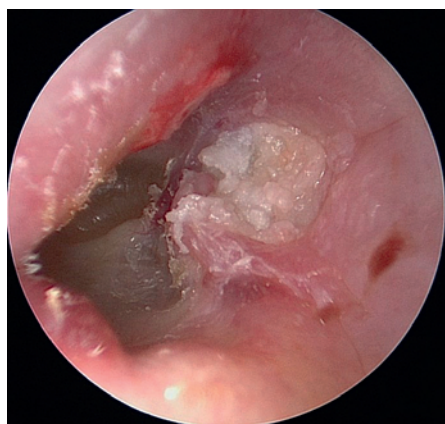

Fig. 3. Limited attic cholesteatoma. Main EES indication.

## 6. Our indications for EES

We perform almost all our tympanoplasties under endoscopic approach. We also use the endoscope for middle ear exploration, and mesotympanic disease such as cholesteatoma. Limited attic cholesteatomas are also managed with an endoscopic atticotomy (on demand technique) (Fig. 3). In some cases, we associate the use of the endoscope with a post-auricular mastoidectomy to increase the control of the disease in occult recesses. Sometimes the endoscope can be very useful in second-look surgeries in open cavities. And finally, we find the endoscopic approach very useful to treat posterior tympanic membrane retractions (atelectasis).

## 7. Pearls and pitfalls

- Infiltration of vasoconstrictors with local anesthetic is paramount in this approach. It is advisable to do it a few minutes before starting and allow a reasonable time to let it take effect.
- Hair trimming of the auditory meatus could be necessary in some cases.
- Always use cottonoid pledges to pack off areas of bleeding where you are not working.
- If profuse bleeding appears, regular warm saline irrigation can clean the operative field.
- Soft dissection with a cottonoid on the tip of a suction cannula can be very useful.
- Before harvesting the graft material, pack off the middle ear to obtain a clean view.
- Keeping the endoscope submerged in a thermos with warm water can help with fogging.
- Be careful with anti-fog solutions because they can lead to an ototoxic effect.<sup>3</sup>
- Be careful with the heat at the tip of the endoscope. Check your light source intensity.<sup>4</sup>

## References

1. Thomassin JM, Korchia D, Doris JMD. Endoscopic-guided otosurgery in the prevention of residual cholesteatomas. *Laryngoscope* 1993;103:939-943.
2. Yung MMW. The use of rigid endoscopes in cholesteatoma surgery. *J Laryngol Otol* 1994;108(4):307-309.
3. Nomura K, Oshima H, Yamauchi D, et al. Ototoxic effect of Ultrastop antifog solution applied to the guinea pig middle ear. *Otolaryngol Head Neck Surg* 2014;151(5):840-844.
4. Aksoy F, Dogan R, Ozturan O, et al. Thermal effects of cold light sources used in otologic surgery. *Eur Arch Otorhinolaryngol* 2015;272:2679-2687.



# BONE CONDUCTION IMPLANTS IN PEDIATRIC CHOLESTEATOMA MANAGEMENT\*

Stephen P. Cass<sup>1</sup>, Gregory C. Allen<sup>2</sup>, Kenny H. Chan<sup>2</sup>

<sup>1</sup>*Department of Otolaryngology, University of Colorado School of Medicine, Aurora, Colorado, USA;*

<sup>2</sup>*Department of Pediatric Otolaryngology, Children's Hospital Colorado, Aurora, CO, USA*

## 1. Introduction

The use of bone conduction hearing implants (BCI) to manage hearing loss in children with cholesteatoma or chronic suppurative otitis media has not been well studied. In particular, are BCI-related complications in patients with cholesteatoma/CSOM different from those in patients without cholesteatoma/CSOM? Can the use of a BCI permit alteration of the surgical approach or technique resulting in better management of their underlying chronic ear disease? Do BCI's provide sufficient speech audibility?

## 2. Methods

Following IRB approval, a 12-year retrospective chart review of our BCI population at a tertiary academic children's hospital was performed.<sup>1</sup> Clinical charts were identified based on search of the electronic health records as well as CPT codes. All subjects that underwent BCI implantation underwent a thorough chart review to obtain demographic and clinical data for the initial implantation and the postoperative care period. Complications were examined by timing and severity. Timing of complications was divided into peri-operative (< three months) and postoperative (> three months). The severity of the complications was classified by the medical and/or surgical interventions required to resolve the complication into minor, moderate, and major complications. Minor was defined as no medication or surgery needed (*i.e.*, re-education for skin hygiene, tightening of a loose abutment). Moderate was defined as the need for medication or minimal treatment in the outpatient clinic (oral antibiotic and/or topical antibiotic or steroid therapy, silver nitrate topical cauterization). Major was defined as the need for a revision surgical procedure in the operating room. In addition, major complications involving soft tissue infection, loss of the fixture, loss of use, and conversion to a different kind of device separately were analyzed.

## 3. Results

Overall, 45 subjects were identified with a mean age at implantation of 8.2 years (range 1.7 to 19.1 years). The most common indication for the BCI was congenital aural atresia. All subjects had a device implanted with a percutaneous abutment. In this cohort of subjects, 58 BCI-related complications occurred in 29 subjects. The majority of the complications were related to skin infection or overgrowth: 18 events required oral antibiotic and/or office-based cauterization and 17 events required revision surgery (43% of patients).

\*Supported by NIH/NCRR Colorado CTSI Grant Number UL1 RR025780

Correspondence: Stephen P. Cass, M.D., Academic Office Building 1, B 205, 12631 East 17th Ave, Aurora, Colorado, 80210, USA.  
E-mail: stephen.cass@ucdenver.edu

*Cholesteatoma and Ear Surgery – An Update 2017, pp. 51 -54*

*Edited by Matthew Yung*

*2017 © Kugler Publications, Amsterdam, The Netherlands*

In nine out of 45 subjects, a BCI was placed in conjunction with surgery for cholesteatoma/CSOM. In these children, the mean age at BCI implant was 9.2 years (5-14 years) and mean follow-up was 5.5 years (1-11 years). All children with cholesteatoma/CSOM were syndromic (trisomy 21 in seven patients and Crouzon Syndrome in two) and all had conductive or mixed hearing loss present. In these subjects, moderate (requiring medical intervention) BCI-related complications occurred in five out of nine subjects and major (requiring surgical intervention) occurred in four out of nine subjects. Thus, the rate of BCI-related complications was no different than in our larger cohort of children without cholesteatoma/CSOM (40% rate of major complications). Excellent speech audibility (SRT 20-25 dB) was documented in eight out of nine subjects and successful long-term BCI use was documented in five out of nine subjects with a mean follow-up of 5.6 years. Three out of nine subjects returned to hearing aid use: one due to STR's, one due to better sound quality with a hearing aid, and one due to better audibility using high powered hearing aids (this subject had mixed hearing loss). One subject has become non-auditory (severe autism). These children all required several otologic procedures to control their underlying disease. However, when recurrent active disease was present and the decision was made to use a BCI for hearing, we were able to modify our surgical approach using thick cartilage grafting for revision perforations with chronic otorrhea and EAC closure for persistent cholesteatoma. These subjects all have dry and stable ears (6-11 year FU) and are being monitored for cholesteatoma using MRI q three to five years.

#### 4. Discussion

Development of chronic ear disease in these subjects followed a stereotypical pattern with early formation of chronic serous otitis media causing persistent conductive hearing loss that was treated with PE tubes. Then chronic suppurative otitis media developed with either chronic tympanic membrane perforation or cholesteatoma formation and persistent conductive hearing loss. There are few studies available to guide management of OME in children with Down syndrome, but those available do suggest lower rates of cure and higher rates of persistent hearing loss and greater rates of complications in children with Down syndrome compared to controls. Based on these studies, NICE recommendations suggest a trial of hearing aids prior to PET placement.

In this review, the reasons to consider a BCI over an air-conduction hearing aid included: hearing aid impractical due to repeated otorrhea, fluctuating hearing loss due to OM, stenotic ear canals, or the subject simply did not tolerate hearing aids. The use of a BCI permitted alteration of the otologic procedure (either EAC closure or thick cartilage grafting) that resulted in enduring dry/stable ears.

#### 5. Summary

- Children with recurrent cholesteatoma/CSOM and unfavorable clinical factors can benefit from a bone conduction implant.
- The rate of BCI-related complications is not greater in children with cholesteatoma.
- Use of a BCI to manage hearing loss due to cholesteatoma permits alterations in surgical technique resulting in a stable/dry ears.
- Long-term FU indicates BCIs are not always a permanent hearing solution (one out of three returned to hearing aid use).

---

**References**

1. Chan KH, Gao D, Jensen EL, Allen GC, Cass SP. Long-term Complications and Parent Satisfaction in Pediatric Osseointegrated Bone Conduction Hearing Implants: A Correlative Study. *Laryngoscope* 2017; in press.





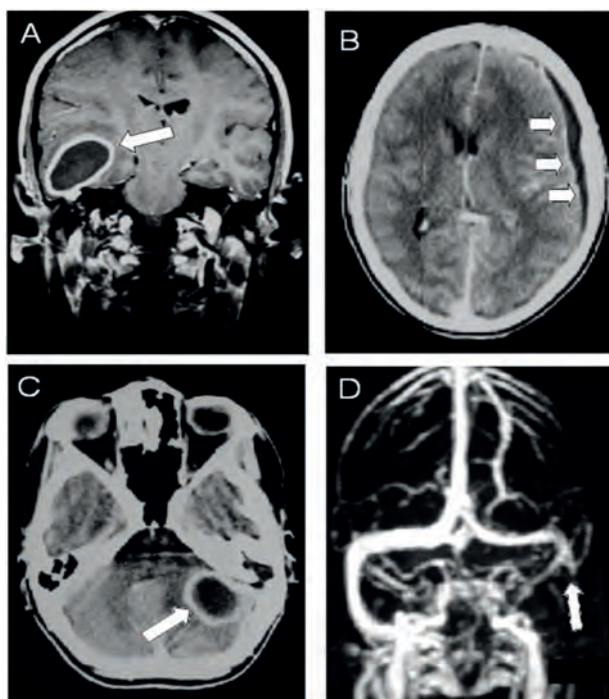
# MANAGING CHOLESTEATOMA: SOMETHING OLD, SOMETHING NEW, AND SOMETHING BORROWED

Sujana S. Chandrasekhar

*New York Otology, Department of Otolaryngology – Head and Neck Surgery of Hofstra-Northwell School of Medicine, American Otological Society, New York, USA*

## 1. Introduction

Optimizing patient outcomes in cholesteatoma and chronic otitis media (COM) remains challenging. Using old techniques that are still vitally important, such as histopathologic evaluation, remembering old complications that many in the developed world incorrectly consider only a problem in the developing world, fine-tuning diagnostic techniques including otoscopy, micro-endoscopy, and working with our radiology colleagues to use better imaging modalities, will all enable improved patient care, less recidivism, fewer operations per patient, and fewer complications.



*Fig. 1. Imaging of intracranial complications of otitis media including cerebral abscess in the middle cranial fossa (A) and the posterior cranial fossa (C), subdural empyema (B) and magnetic resonance angiogram showing left lateral sinus thrombosis (D). Arrows point to ICC. (From: Maranhão AS<sup>1</sup>.)*

## 2. Something old

### 2.1. Intracranial complications (ICCs) of otitis media (OM)

Surgical extirpation of cholesteatoma must be adequate to negate recurrent or recidivistic disease but maintain as much hearing function as possible in a healthy mucosalized space. The problem of intracranial complications (ICCs) of cholesteatoma remains a current concern, even as we seek to fine-tune hearing outcomes and minimize re-operation.

The overall rate of ICCs from otitis media (OM) is 8%. Thirty percent of OM complications are ICC, and 5-26% of ICCs from OM result in mortality. Of great importance to both treating otolaryngologists as well as primary care physicians (PCP), when it arises from COM, the ICC course can be indolent for a long while.<sup>1</sup>

ICCs of OM include: meningitis, which accounts for 21-72%, cerebral abscess, accounting for 18-42%, lateral sinus thrombosis, seen in 2-26%, extradural abscess, occurring in 7-16%, otitic hydrocephalus, seen in 5-11%, and encephalitis, occurring in 2% (Fig.1).<sup>2</sup>

Prevention of ICC in OM is important. This lies in the realm of both the PCP and the otolaryngology specialist. It is important that both PCPs and otolaryngologists train themselves to examine ears accurately.<sup>3</sup> Detection and treatment of ongoing COM and/or incipient cholesteato-

Correspondence: Sujana S. Chandrasekhar, MD, 1421 Third Avenue, 4th Floor, New York, NY 10028, USA  
E-mail:ssc@nyotology.com

*Cholesteatoma and Ear Surgery – An Update 2017, pp. 55 -58*

*Edited by Matthew Yung*

*2017 © Kugler Publications, Amsterdam, The Netherlands*

ma in childhood and timely referral to otolaryngology for aggressive management will greatly reduce the risk of later development of ICCs. There is data that shows that pediatric residents suffer from a paucity of formalized resident instruction in diagnosis of OM; when measured against pediatric otolaryngologists, there was only slight or fair agreement, and when measured compared to tympanometry, resident interpretation was only slightly in agreement while otolaryngologist interpretation had fair agreement.<sup>4</sup>

When an ICC occurs from indolent or inadequately treated COM or cholesteatoma, the connection to (often subclinical) ear disease may be missed, as the meningitis or cerebral abscess, etc., is more pressing. However, neurosurgical management alone is inadequate and will result in recurrence of ICCs. Identification of the underlying COM and aggressive surgical management of the ear disease, which may extend to transmastoid drainage of cerebral abscess, has the best possible patient outcome.

## **2.2. Temporal bone histopathology to assist the care of COM/cholesteatoma**

Studying temporal bone sections in ears with COM and/or cholesteatoma enables the otologic surgeon to operate most effectively, minimizing opportunity for recidivistic or residual disease. In cholesteatoma, histopathologic sections will delineate the narrow neck in most sacs which accounts for the buildup of keratinous material. Wetness then hastens accumulation and enzymatic degradation of surrounding bone. Additionally, cholesteatoma includes sub-osteitic granulation tissue, which is why it is important not only to remove the matrix, but to drill the mastoid down to healthy bone. Intimate knowledge of histopathology will also enable correct interpretation of preoperative imaging studies.

## **3. Something new**

### **3.1. High-resolution micro-endoscopy (HRME)**

It can be difficult distinguishing between cholesteatoma and mucosa. This problem can result in either removal of too little disease, with ensuing residual cholesteatoma formation, or removal of too much normal mucosa, resulting in scar tissue and poor hearing outcome. High-resolution micro-endoscopy (HRME) is a technique that may be able to help distinguish normal mucosa from cholesteatoma *in vivo*. It has previously been used in mucosa. Proflavine is applied topically to the tissue, and gingival keratin appears as disorganized hyperfluorescence without visible nuclei. Similarly, in *ex-vivo* specimens of middle ear epithelium, nuclei are seen clearly on HRME, while in cholesteatoma specimens, keratin again appears as disorganized hyperfluorescence without visible nuclei. The potential ototoxicity of proflavine is not known, however, and this technique is not available for clinical use at this time.<sup>5</sup>

### **3.2. Multiwavelength fluorescent otoscopy**

Otoscopy examination has been performed using white-light illumination has for over a hundred years. The limited contrast of white-light otoscopy constrains the ability to make accurate assessment of middle ear pathology and is subject to significant observer variability. Researchers have employed a modified otoscope with multi-color imaging capabilities for superior characterization of the middle ear constituents *in vivo* and for enhanced diagnosis of acute OM and cholesteatoma.<sup>6</sup> A pilot study of five patients undergoing surgery for tympanostomy tube placement and congenital cholesteatoma excision showed that the multi-color imaging approach offers an increase in image contrast, thereby enabling clear visualization of the middle ear constituents, especially of the tympanic membrane vascularity. Differential absorption at the multiple wavelengths provides a measure of biochemical and morphological information, and the rapid acquisition and analysis of these images aids in objective evaluation of the middle ear pathology. There is additional potential of using label-free narrow-band reflectance imaging to differentiate middle ear pathological conditions from normal middle ear.

### 3.3. Intranasal surfactant delivery for treatment of Eustachian tube dysfunction (ETD)

Eustachian tube dysfunction (ETD) is both a cause and effect of OM and middle ear effusion (MEE). Moreover, in COM, the struggle for middle ear and hearing reconstruction is against the chronic negative pressure of ETD. Treatments have primarily been myringotomy with or without insertion of pressure-equalization tubes for OM and MEE, and for many cases of COM. Use of rigid tympanoplasty techniques including cartilage is another attempt to counteract ETD's negative pressure. Recently, balloon dilatation of the cartilaginous Eustachian tube (ET) has been used; however, it appears that much of the ETD in middle ear disease is at the protympanic or bony ET, which are not affected by balloon dilatation.<sup>7</sup> Surfactants are normally present in the ET and middle ear, and their concentration is reduced in cases of OM.

A synthetic surfactant composed of dipalmitoyl phosphatidylcholine (DPPC) and cholesteryl palmitate (CP) and delivered aerosolized via a metered dose inhaler has been shown to be effective in animal models in: (a) reducing ET passive opening pressure in normal ears; (b) dramatically reducing days of effusion in OM with effusion (OME); and (c) resolving bacterial acute OM without antibiotic administration.<sup>8</sup> Unlike balloon or other mechanical dilatation of the nasopharyngeal (cartilaginous) ET, surfactant applied in the nose should, by its physicochemical properties, travel along the moist mucosal surface into the lumen of the ET. Entering the ET, the surfactant should 'de-stick' the apposed mucosal surfaces, effectively opening the tube along its full length up through the bony ET and to the protympanum. Human trials are anticipated to begin in due course.

## 4. Something borrowed

### 4.1. Magnetic resonance imaging (MRI)

The most commonly used imaging modality for cholesteatoma is computerized tomography (CT) scanning. It is used by some surgeons for preoperative planning and is often used to determine if there is recurrent or residual cholesteatoma as a non-surgical 'second look.' However, soft tissue changes seen on postoperative CT scans cannot definitively be identified as cholesteatoma versus mucosal thickening. Diffusion-weighted magnetic resonance imaging (DWMRI) is a useful technique to distinguish cholesteatoma from non-cholesteatomatous soft tissue in the mastoid and middle ear, while avoiding even the minimal risks of intravenous gadolinium-DTPA injection.<sup>9</sup> Non-echo planar DWMRI is seen to have high sensitivity and specificity for identifying cholesteatoma (Table 1).<sup>10</sup> Figure 2 shows the utility of DWMRI in distinguishing between cholesterol granuloma and cholesteatoma in a postsurgical temporal bone. The surgeon must be aware, however, that there is the possibility of false positive findings, and the clinical presentation remains of significant importance.

*Table. 1.* Utility of various imaging techniques in detecting cholesteatoma. CT = computed tomography. DW-EPI = diffusion-weighted echoplanar imaging. DW Non-EPI = diffusion-weighted non-echoplanar imaging. DW-EPI and DW Non-EPI refer to techniques of magnetic resonance imaging.

	CT Scan	DW-EPI	DW Non-EPI
<b>Sensitivity</b>	42.9%	68 %	97%
<b>Specificity</b>	48.3%	87 %	97%
<b>Positive Predictive Value</b>	28.6%	81%	97%
<b>Negative Predictive Value</b>		78%	97%

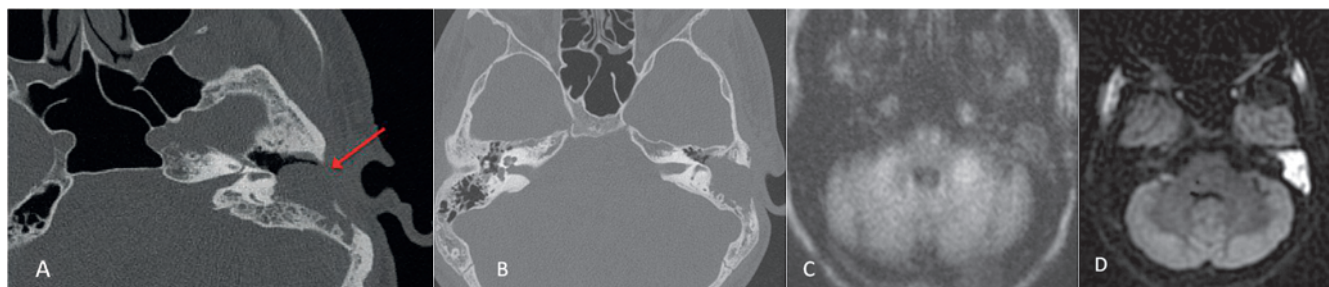

Fig. 2. CT images A and B show smooth soft tissue density in postsurgical mastoid bones. DWMR images C and D show the difference between those densities. In C, corresponding with A, the soft tissue is seen to be cholesterol granuloma. In D, corresponding with B, the soft tissue is seen to be cholesteatoma. (Images courtesy of Dr. Eloisa Santiago Gebrim, HC-FMUSP, Hospital Sirio-Libanes, Sao Paulo, Brazil.)

## 5. Conclusion

The best surgical and patient outcomes for COM and cholesteatoma will be achieved by incorporating many tactics. Proper study of histopathologic growth and spread patterns will allow for better microsurgical and mastoidectomy techniques. Staying alert for the development of ICCs, ensuring that the treatment encompasses the underlying otologic cause, and, preferably, avoiding those complications entirely by improving first level diagnostic techniques, is important throughout the world. New techniques for enhanced appreciation of cholesteatoma vs. middle ear mucosa should result in better hearing outcomes and less recidivism. Use of other than white light in otoscopic evaluation may allow for earlier and more accurate diagnosis by both PCP and otolaryngologist. Addressing the underlying ET dysfunction in all types of OM should result in better hearing outcomes. Adding MR images may prevent unnecessary ‘second look’ surgeries. It is an exciting time in otology where the confluence of knowledge by time and by specialty is improving patient care.

## References

1. Maranhão AS, Godofredo VR, Penido Nde O. Suppurative labyrinthitis associated with otitis media: 26 years' experience. *Braz J Otorhinolaryngol* 2016;82(1):82-87.
2. Penido NO, Chandrasekhar SS, Borin A, Maranhão AS, Gurgel Testa JR. Complications of otitis media – a potentially lethal problem still present. *Braz J Otorhinolaryngol* 2016;82(3):253-262.
3. Rosenfeld RM, Shin JJ, Schwartz SR. Clinical Practice Guideline: Otitis Media with Effusion (Update). *Otolaryngol Head Neck Surg* 2016;154(1 Suppl):S1-S41.
4. Steinbach WJ, Sectish TC, Benjamin DK, Chang KW, Messner AH. Pediatric Residents' Clinical Diagnostic Accuracy of Otitis Media. *Pediatrics* 2002;109(6):993-998.
5. Bradley J, Jiang N, Levy L, et al. High-Resolution Microendoscope Images of Middle Ear Cholesteatoma and Surrounding Tissue: Evaluation of Interobserver Concordance. *Otolaryngol Head Neck Surg* 2014;150(4):654-658.
6. Valdez TA, Spegazzini N, Pandey R, et al. Multi-color reflectance imaging of middle ear pathology in vivo. *Anal Bioanal Chem* 2015;407(12):3277-3283.
7. Tarabichi M, Najmi M. Site of eustachian tube obstruction in chronic ear disease. *Laryngoscope* 2015;125(11):2572-2575.
8. Chandrasekhar SS, Mautone AJ. Otitis Media: Treatment with Intranasal Aerosolized Surfactant. *Laryngoscope* 2004;114(3):472-485.
9. Pennanéach A, Garetier M, Ollivier M, Ognard J, Marianowski R, Meriot P. Diagnostic accuracy of diffusion-weighted MR imaging versus delayed gadolinium enhanced T1-weighted imaging in middle ear recurrent cholesteatoma: A retrospective study of 39 patients. *J Neuroradiol* 2016;43(2):148-154.
10. Jindal M, Riskalla A, Jiang D, Connor S, O'Connor AF. A systematic review of diffusion-weighted magnetic resonance imaging in the assessment of postoperative cholesteatoma. *Otol Neurotol* 2011;32(8):1243-1249.



# BONE CEMENTS FOR MASTOID/POSTERIOR CANAL WALL RECONSTRUCTION

Sujana S. Chandrasekhar

*New York Otology, Department of Otolaryngology – Head and Neck Surgery of Hofstra-Northwell School of Medicine, American Otological Society, New York, USA*

## 1. Overview

The ‘great debate’ in mastoid surgery, canal wall up (CWU, also called ‘intact canal wall’ or ICW) versus canal wall down (CWD), continues. Briefly, CWU or ICW techniques are considered more physiologic for hearing and for self-cleaning, as the external auditory canal (EAC) is preserved. Therefore, there is no need for long-term mastoidectomy bowl care, as there is no bowl. However, there is an increased risk of recurrent or recidivistic disease that may be hidden behind the intact posterior canal wall (PCW), and there is a push for a second stage surgery to assess for remaining disease, often combined with ossicular reconstruction for hearing restoration. On the other hand, CWD techniques result in a mastoid bowl that is not self-cleaning like the EAC is and so requires life-long mastoid bowl care, and a potentially significant degree of hearing loss. Most of these patients must maintain life-long water precautions as well. A good CWD bowl is accompanied by a large external auditory meatoplasty that may be cosmetically unpleasing. But in removing the posterior bony canal and creating a bowl, the risk of recurrent or residual disease in the mastoid is minimized or eliminated. The reader is reminded that the sinus tympani remains hidden in both ICW and CWD approaches. A planned ICW case can be converted to a CWD case due to the extent of the disease, as shown in Figure 1.

The EAC is not just a passive conduit for sound in the environment to reach the tympanic membrane. The radius, length and volume contribute to the resonant frequency of the EAC which is between 2800 Hz and 3100 Hz in normal humans. The acoustic pressure amplification is about 20 dB between frequencies of 2000 and 4000 Hz. After classical CWD operations, the acoustic relationships of the EAC and middle ear change. Creation of a bowl (removal of the posterior EAC wall) leads to a fall in resonance frequency from 2942 Hz to 1939 Hz through volume expansion, from 0.9 ml to 2.3 ml. This may dramatically affect understanding speech and hearing music, as the formant area from 2800 to 3200 Hz is essential for the entire speech spectrum.<sup>1</sup>

Additionally, removing the posterior EAC wall often results in reduced air volume behind the tympanic membrane. In a radical cavity situation, the normal ME/mastoid volume of 6 cm<sup>3</sup> is reduced to 1 cm<sup>3</sup>, and this can cause 10 dB and more low frequency hearing losses.<sup>2</sup>

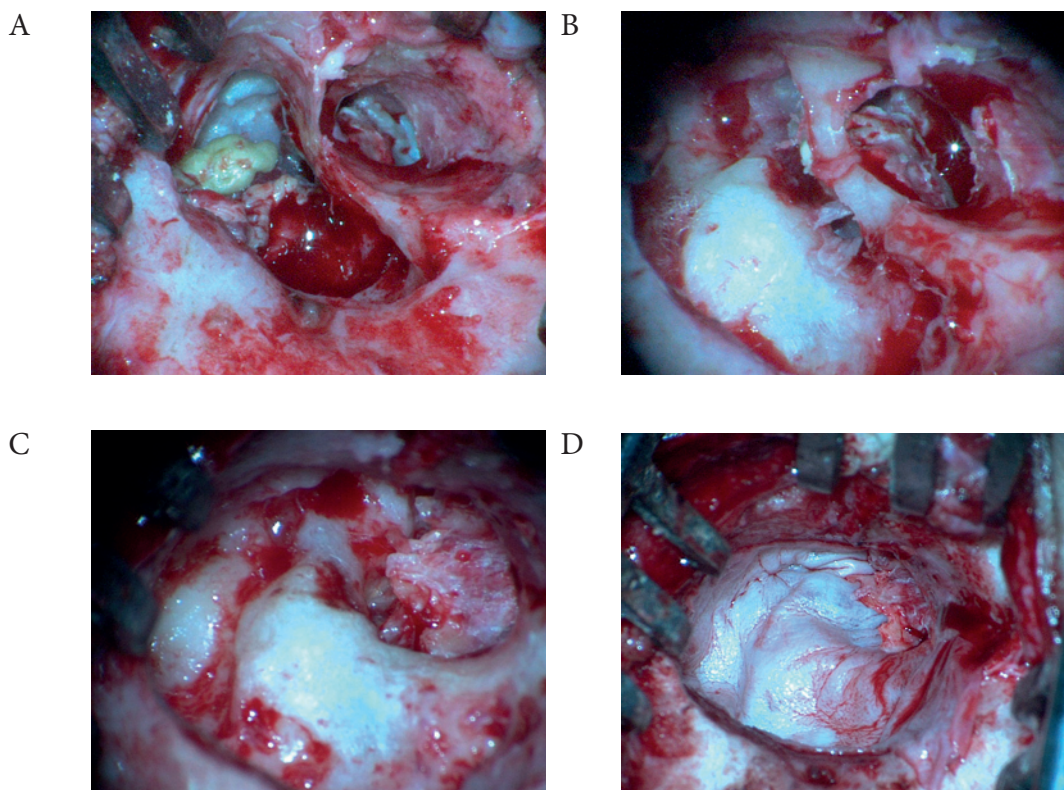
It is possible, in many cases, to derive the benefits of CWD mastoidectomy and end up with the improved physiology of the ICW. The PCW can be removed and replaced after the disease is cleared. When the PCW is drilled away, techniques for obliteration of the mastoid bowl to minimize the a-physiologic and hearing issues with CWD mastoidectomy include using thick soft tissue including free fascia grafts and Palva flaps, as well as using bone chips and other materials in the bowl beneath the fascia.

Correspondence: Sujana S. Chandrasekhar, MD, 1421 Third Avenue, 4th Floor, New York, NY 10028, USA  
E-mail:ssc@nyotology.com

*Cholesteatoma and Ear Surgery – An Update 2017, pp. 59 -62*

*Edited by Matthew Yung*

*2017 © Kugler Publications, Amsterdam, The Netherlands*



*Fig. 1.* Conversion of a planned CWU (ICW) mastoidectomy to CWD. *A* – attic canal cholesteatoma is seen. *B* – it burrows deep despite appropriate thinning of the bony canal and creation of a good facial recess approach. *C* – the PCW has been taken down and the facial ridge is drilled down to be as shallow as possible between the inferior EAC and the mastoid tip. *D* – A large fascial graft is placed in an underlay fashion under the anterior tympanic membrane remnant, extending superiorly and posteriorly over the facial ridge to line the mastoid bowl. Not shown here is the placement of the posterior tympanomeatal skin flap over the fascia in the mastoid bowl.

## 2. Cements for mastoid reconstruction

### 2.1. Glass ionomer cement

Glass ionomer cements were developed as dental cements in the 1960s and are made of a silicate glass powder combined with a water-soluble polymer. Often an acid is combined as well. They have been used successfully in dental and orthopedic implants, but are known to be brittle and unable to be used in load-bearing areas there. They have been tried in middle ear hearing reconstruction as well as in PCW reconstruction. One study with over five years of follow-up in 23 patients showed the same poor results seen by others.<sup>3</sup> Six of the 23 patients had severe middle ear infection and otorrhea after 12 months. There were an additional three spontaneous extrusions after four years, for a total of nine of 23 spontaneous extrusions. Mean survival time of the cement was 28 months. Another study with three years of follow-up showed a significant reduction in aural care visits and improvement in quality of life following mastoid obliteration in chronically discharging ears with one brand of glass ionomer granules, but noted that postoperative infection can prevent osseointegration of the cement.<sup>4</sup>

In addition, due to the composition of glass ionomer cement, there is potential neurotoxicity if it comes into contact with dura or a cranial nerve, with a significant risk of aluminum encephalopathy.

Glass ionomer cements should be used with care for mastoid or PCW reconstruction.

### 2.2. Hydroxylapatite for PCW/mastoid reconstruction

Hydroxylapatite (also written as hydroxyapatite) (HA) is a mineral of the apatite group that is the main inorganic constituent of tooth enamel and bone. Hydroxyapatite cement is a calcium phosphate-based material that when mixed with water forms a dense paste that sets within 15 minutes and isothermally converts *in vivo* to a microporous hydroxylapatite implant. It was first described for experimental use in 1992<sup>5</sup> and has since been used extensively for various surgical applications.



HA can be used as cement or as granules. One study showed that four of eight patients whose PCW was reconstructed with HA cement failed while none of the patients for whom HA granules were used failed. One-year outcomes were excellent in terms of epithelized ears that could tolerate swimming.<sup>6</sup> In another study, 28 ears with chronically weeping mastoid cavities for an average of ten years were reconstructed with autologous bone pate mixed with HA granules. They were examined at six months and 25 were successful. At longer-term follow-up, 21 out of the original 28 remained successful.<sup>7</sup>

HA can also be used as a coating for other materials. One study looked at eight patients with chronically discharging radical mastoidectomy cavities. Their reconstruction was done with titanium net combined with porous HA coating. They all had rapid healing and good aeration of the middle ear and mastoid, with good to excellent outcomes after a year or more of follow-up, with the exception of one TM perforation.<sup>8</sup>

HA cement can be used as a 'spackle' when the PCW is removed en bloc for the duration of the surgical extirpation and then replaced. Care must be taken to ensure that there is complete, healthy soft tissue coverage and that none of the cement is visible in the EAC.<sup>9</sup> Local infection rates for HA mastoid reconstruction are higher than reported for pristine skull base or other bony work. Infection rates range from 6% to 35% and underscore the need for early identification and treatment of even a 'minor' infection in the area. One study of pediatric cholesteatoma ears showed HA cement failure in three of three cases, two with delayed failure of integration and infection, and one with severe osteitis.<sup>10</sup>

### 3. Calcium phosphate paste

One study examined the use of calcium phosphate paste in mastoid bowl obliteration. Ten ears with various infective/cholesteatomatous otopathologies underwent CWD mastoidectomy. Once the disease was exenterated, the bowl was filled with calcium phosphate paste and then that was covered with artificial dermis soaked in fibroblastic growth factor.<sup>11</sup> Outcomes were very good at two months and remained excellent at an average of 20 months follow-up. Intraoperative images show the obliteration technique, and pre- and postoperative computerized tomography images highlight the paste implant – as seen in Figure 2.

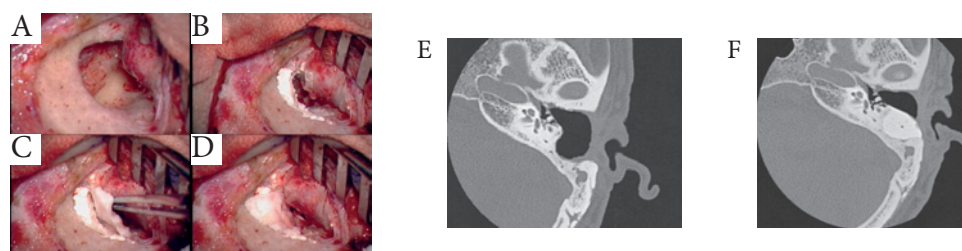


Fig. 2. Intraoperative images of a CWD mastoidectomy bowl (A), gradually being reconstructed with calcium phosphate paste (B,C,D). E – preoperative CT scan showing CWD bowl. F – postoperative CT scan showing paste reconstruction. (From: Kakigi *et al.*<sup>11</sup>)

### 4. Summary

There is ample evidence of improved hearing and quality of life outcomes when the ear canal is able to be as normal as possible – either by a CWU approach or with canal wall reconstruction after a CWD surgery. Cements can be used successfully in mastoid cavity reconstruction or obliteration in selected cases. It is imperative that surgeon adhere to meticulous techniques when employing artificial materials, including cements, for PCW/mastoid reconstruction. The site must be completely clean and dry. There should be no perceived risk of residual disease that may be buried under the reconstruction. There must be no infection or granulation tissue in the mastoid bowl as placement of bone cement over that will assuredly result in failure. When there is failure of osseointegration due to infection, the patient will present with pieces of cement 'spitting' from their ear canal. Complete coverage of

the cement by healthy tissue is vital. Exposed cement in the EAC will also extrude. Glass ionomer cements have less inherent strength than do HA cements, and should not be used in cases of dural or cranial nerve exposure. It must be kept in mind that there is a significant extrusion rate over one year postoperatively and therefore long-term follow-up is necessary. Adherence to stringent surgical techniques, close follow-up, and aggressive management of even minor site infections will result in the best outcomes.

## References

1. Zahnert T. Reconstructive methods in hearing disorders – surgical methods. *GMS Curr Topics Otorhinolaryngol Head Neck Surg* 2005;4:Doc02.
2. Rosowski JJ, Merchant SN. Mechanical and acoustic analysis of middle ear reconstruction. *Am J Otol* 1995;16:486-497.
3. Kupperman D, Tange RA. Ionomeric cement in the human middle ear cavity: long-term results of 23 cases. *Laryngoscope* 2001;111(2):306-309.
4. Clark MP, Bottrill I. SerenoCem – glass ionomeric granules: a 3-year follow-up assessment of their effectiveness in mastoid obliteration. *Clin Otolaryngol* 2007;32(4):287-290.
5. Costantino PD, Friedman CD, Jones K, Chow LC, Sisson GA. Experimental hydroxyapatite cement cranioplasty. *Plast Reconstr Surg* 1992;90(2):174-185; discussion 186-191.
6. Mahendran S, Yung MW. Mastoid obliteration with hydroxyapatite cement: the Ipswich experience. *Otol Neurotol* 2004;25(1):19-21.
7. Magiulo G, D'Amico R, Fusconi M. Reconstruction of old radical cavities and long-term results. *J Otolaryngol* 2004;33(3):155-159.
8. Magliulo G, D'Amico R, Forino M. Reconstruction of the posterior auditory canal with hydroxyapatite-coated titanium. *J Otolaryngol* 2001;30(6):330-333.
9. Dankuc D, Vlaski L, Pejakovic N. Techniques of the tympanomastoidectomy with reconstruction of the posterior bone wall of the external auditory canal. *Srp Arh Celok Lek* 2015;143(7-8):480-486.
10. Ridenour JS, Poe DS, Roberson DW. Complications with hydroxyapatite cement in mastoid cavity obliteration. *Otolaryngol Head Neck Surg* 2008;139(5):641-645.
11. Kakigi A, Taguchi D, Takeda T. Mastoid obliteration using calcium phosphate bone paste with an artificial dermis soaked with basic fibroblast growth factor: Preliminary clinical report. *Auris Nasus Larynx* 2009;36(1):15-19.

# SURFACTANT AND EUSTACHIAN TUBE DYSFUNCTION/OTITIS MEDIA

Sujana S. Chandrasekhar<sup>1</sup>, Alan J. Mautone<sup>2</sup>

<sup>1</sup>New York Otology, Department of Otolaryngology – Head and Neck Surgery of Hofstra-Northwell School of Medicine, American Otological Society, New York, USA; <sup>2</sup>Department of Physiology, Pharmacology and Neuroscience, Rutgers New Jersey Medical School, Newark, NJ and Department of Biomedical Engineering, Department of Chemistry, Chemical Biology and Biomedical Engineering, Stevens Institute of Technology, Hoboken, NJ, USA

Both authors are shareholders in Otodyne, Inc., and consultants for Otic Pharma, Inc. – which are the patent holders and developers of this surfactant product, respectively.

Surfactants are found in the normal upper and lower respiratory system, including at the nasopharyngeal orifice of the Eustachian tube (ET). In otitis media (OM), there is a measurable reduction of surfactant in the ET. ET dysfunction is both a cause and result of middle ear (ME) fluid accumulation. The hypothesis is that restoration of exogenous surfactant – a combination of dipalmitoyl phosphatidylcholine (DPPC) and cholesteryl palmitate (CP) delivered in an aerosol via a metered dose inhaler (MDI) – at the ET orifice will restore physiologic opening and closing function of the ET, draining ME fluid and reestablishing an aerated ME space. All experiments described were conducted in accordance with the institutions IRB and IACUC.

We developed a method of testing ET passive opening pressure (POP) in a living animal model without traumatizing the tympanic membrane (Figs. 1, 2) In gerbil and mouse models, exogenous synthetic surfactant resulted in significant reduction of POP ( $p < 0.05$ ).<sup>1</sup> Subsequently, OM with effusion (OME) was developed in gerbils with heat-killed *Klebsiella pneumoniae* endotoxin. Intranasal spray of either the active agent (DPPC+CP), propellant alone, active agent with steroid, or active agent with phenylephrine was administered either once or twice daily. A dramatic and persistent reduction of ME fluid was seen, with surfactant alone once daily reducing effusion

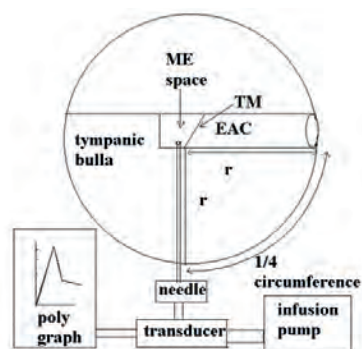


Fig. 1. Schematic diagram of atraumatic, repeated measurement system for Eustachian tube passive opening pressure. ME = middle ear. TM = tympanic membrane. EAC = external auditory canal. r = radius of the circle defined by the longest length of the EAC.

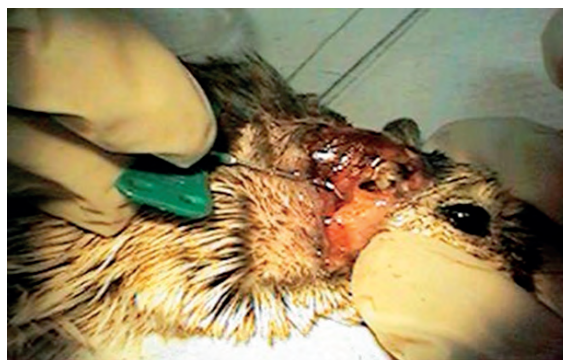


Fig. 2. Needle entering bulla behind the external auditory canal (arrow).

Correspondence: Sujana S. Chandrasekhar, MD, 1421 Third Avenue, 4th Floor, New York, NY 10028, USA.  
E-mail:ssc@nyotology.com

*Cholesteatoma and Ear Surgery – An Update 2017, pp. 63 -66*

*Edited by Matthew Yung*

*2017 © Kugler Publications, Amsterdam, The Netherlands*

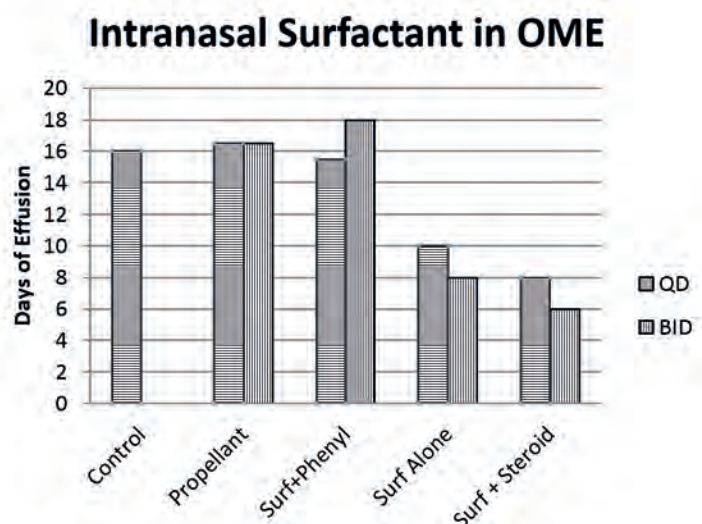


Fig. 3. Intranasal MDI aerosolized surfactant reduces days of effusion in OME when surfactant (Surf) is given alone or with steroid, once or twice per day. It increases days of effusion when given with phenylephrine (Phenyl), twice daily. ( $p < .05$ ) Gerbil model.

time from 16 days to ten days, surfactant alone twice daily or surfactant with steroid once daily reducing it to eight days, and surfactant with steroid twice daily reducing it to just six days ( $p < 0.05$ ). Propellant alone and surfactant with phenylephrine once daily were the same; increasing the surfactant with phenylephrine to twice daily prolonged the days of effusion to 18<sup>2,3</sup> (Fig. 3).

Acute OM (AOM) was developed in a chinchilla model using intrabullar injection of *Hemophilus influenzae*. Antibiotics were not administered. Thirteen were not treated; 13 were given intranasal surfactant via MDI daily starting at the day of *H. flu* inoculation; 13 were given surfactant daily starting two days after *H. flu* inoculation. There was no difference between the two surfactant groups, but there were significant differences between treated and untreated groups. Tympanometry became normal or near normal in 60% of treated animals and in only 20% of untreated animals by day 12 ( $p = 0.012$ ). Quantitative culture (QC) was initially positive in all animals and then dropped off dramatically starting at day 12 in the treatment groups; by day 27, QC was positive in 10-15% of treated ears vs. 70% of untreated ears ( $p = 0.002$ ). Severity of disease, measured by occurrence of labyrinthitis, was high in the untreated group – nine animals succumbed, while only two animals in each of the treatment groups had severe labyrinthitis ( $p = 0.001$ ). Direct visual inspection revealed that on day 8, all untreated ears had pus, while only 50% of treated ears did ( $p = 0.002$ ), and on day 27, 60% of untreated ears still had pus while 60% of treated ears were dry ( $p = 0.035$ )<sup>4</sup> (Fig. 4).

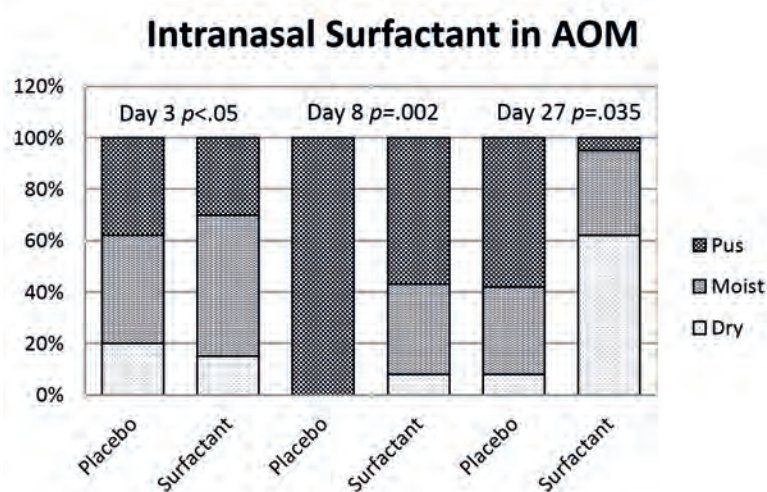


Fig. 4. Intranasal MDI aerosolized surfactant hastens resolution of bacterial acute otitis media in the absence of concomitant antibiotic administration. Direct visual inspection, chinchilla model.



Other studies have looked at the utility of nebulized (not aerosolized) surfactant at the nasopharyngeal ET or irrigated into the middle ear.<sup>5</sup> It is a bovine product, whereas the synthetic surfactant described here has no animal products, and it is not as successful. Because of the physicochemical properties of DPPC and CP, their lipid crystals change shape when exposed to moisture, and nebulizing them reduces their ability to move along moist surfaces such as the nasal mucosal lining and render their 'de-stick' properties effectively.

In humans, ET dysfunction is commonly associated with OME, AOM, recurrent OME and chronic OM, as well as persistent fluid in the middle ear space. In addition, ME fluid causes and perpetuates dysfunction of the ET. Current interventions include antibiotics, myringotomy with or without pressure-equalizing ('Grommet') tube insertion, and use of thicker materials such as cartilage in the tympanic membrane during tympanic and ossicular reconstruction surgery. Recent interventions aimed at the ET include balloon and other surgical dilatation of the nasopharyngeal ET. Studies have shown that the majority of ET dysfunction in chronic OM is in the protympanic area of the middle ear, and there is reasonable concern that dilatation of the nasopharyngeal ET will be inadequate to address this problem.<sup>6</sup>

We believe that the animal data show promise for the use of synthetic, aerosolized surfactant in a combination of DPPC and CP and delivered via metered dose inhaler in the treatment of Eustachian tube dysfunction as well as its sequelae of acute, serous, chronic and recurrent OM. Human clinical trials will soon be underway to establish a role for intranasal MDI surfactant spray in the ongoing management of ETD and OM.

## References

1. Venkatayan N, Troublefield YL, Ammar M el-S, et al. Effect of Intranasal Metered Dose Aerosolized Surfactant on Passive Opening Pressure of the Eustachian Tube – Comparison Study in Two Animal Models. *Otol Neurotol* 2002;23(1):3-7.
2. Venkatayan N, Connelly PE, Mautone AJ, Troublefield YL, Chandrasekhar SS. Dosage regimens of intranasal aerosolized surfactant on otitis media with effusion in an animal model. *Otolaryngol Head Neck Surg* 2001;124(4):388-393.
3. Johnson D, Chandrasekhar SS, Mautone AJ. Intranasal Phenylephrine-Surfactant Treatment is Not Beneficial in Otitis Media with Effusion. *Int J Pediatr Otorhinolaryngol* 2008;72(7):1085-1089.
4. Chandrasekhar SS, Mautone AJ. Otitis Media: Treatment with Intranasal Aerosolized Surfactant. *Laryngoscope* 2004;114(3):472-485.
5. Jang CH, Cho YB, Oh SE, et al. Effect of Nebulized Bovine Surfactant for Experimental Otitis Media with Effusion. *Clin Exp Otorhinolaryngol* 2010;3(1):13-17.
6. Tarabichi M, Kapadia M. Preoperative and Intraoperative Evaluation of the Eustachian Tube in Chronic Ear Surgery. *Otolaryngol Clin N Amer* 2016;49(5):1135-1147



# MIDDLE EAR PRESSURE MAINTENANCE: (1) A CONCERT PLAYED BY MANY INSTRUMENTS; (2) PATHOLOGY AS COMPENSATION

Udi Cinamon

*Department of Otolaryngology, Head and Neck Surgery, Wolfson Medical Center, Sackler School of Medicine, Tel Aviv University, Israel*

It is crucial that the pressure in the middle ear (ME) will be kept approximately to ambient pressure. As a physiological system that needs to confront constant intrinsic and extrinsic changes (*e.g.*, cardiovascular system, respiratory system, etc.) the ME needs to possess special capabilities to maintain a physiological steady state. This ME pressure homeostasis is a concert played by several mechanisms, *i.e.*, pressure regulators meant to neutralize or minimize pressure changes. These mechanisms adjust the amount of gas, its flow and diffusion, as well as the volume and temperature of the middle ear cleft, all following the law of gases [ $PV = nRT$ ]

**Volume:** Size matters, the mastoid and the tympanic membrane (TM) being a ‘pressure buffers’.

**Surface matters:** The ‘radiator’ effect of the ME cleft regarding gas exchange, temperature, moisture (number of molecules, Temperature). The Eustachian tube (ET) being a conduit possessing a pumping effect. Nerves and pressure receptors may control ventilation by opening the ET. When one or more of these mechanisms fails, a ‘disorder’ may kick in. Therefore, developing a chronic ME insufficiency is accepted as the pathophysiological setting for developing chronic ME disease, clinically presented as otitis media with effusion (OME), atelectasis of the TM or associated with developing cholesteatoma.

These chronic changes can be addressed as compensatory mechanisms (*e.g.*, heart hypertrophy to keep up with perfusion having a failing heart). Edema of the mucosa, engorgement of vessels and transudate will diminish the volume and influence gaseous content in the ME elevating pressure. TM atelectasis changes the ME volume being a pressure buffer.

Failure to confront a prompt and significant pressure change, a situation in which the ME pressure needs to be elevated instantly, will be presented as barotrauma. The consequence would be transudate, hemorrhage, and TM perforation, all means ‘trying’ to compensate.

Correspondence: Udi Cinamon, Department of Otolaryngology, Head & Neck Surgery, Wolfson Medical Center, 62 Halohamim St., Holon, Israel  
E-mail: [udicin@yahoo.com](mailto:udicin@yahoo.com)

*Cholesteatoma and Ear Surgery – An Update 2017, pp. 67 -68*  
*Edited by Matthew Yung*  
*2017 © Kugler Publications, Amsterdam, The Netherlands*





# STUDIES BY NATURE OF EUSTACHIAN TUBE DYSFUNCTION: A PRELIMINARY REPORT

Udi Cinamon<sup>1,4</sup>, Hussein Amer<sup>2</sup>, Avraham Lazary<sup>1</sup>, Dov Albukrek<sup>2,4</sup>, Tal Marom<sup>3,4</sup>

<sup>1</sup>Department of Otolaryngology, Head and Neck Surgery, Wolfson Medical Center, Holon, Israel; <sup>2</sup>Reuth Medical and Rehabilitation Center, Tel Aviv, Israel; <sup>3</sup>Department of Otolaryngology, Head and Neck Surgery, Assaf Harofe Medical Center, Zerifin, Israel; <sup>4</sup>Sackler School of Medicine, Tel Aviv University, Israel

## 1. Background and Objective

The Eustachian tube (ET) is a conduit communicating the middle ear (ME) with the nasopharynx. Although the ET is usually collapsed, its active, intermittent, transient opening is accepted to play a critical role in the maintenance of the ME pressure approximately at ambient pressure, consequently allowing normal ME function. Interference of fluid passage through the ET was termed 'ET dysfunction', implying its insufficiency is the pathophysiology of chronic ME diseases, such as otitis media with effusion (OME), tympanic membrane (TM) atelectasis or development of cholesteatoma.<sup>1-7</sup> Our objective was to study a unique group of patients with a severely diminished ability to actively open the ET.

## 2. Patients and Methods

An informed consent was obtained from the authorized guardian(s).

The 20 patients enrolled in this study were evaluated, treated and hospitalized in a specialized rehabilitation institution. All were unconscious due to severe brain damage caused by various head traumas, severe anoxic damage or severe cerebrovascular accidents. All were tracheotomized, unable to swallow, to produce valsalva or yawn, requiring oral suction of saliva and fed by gastric tubes for a long period of time. None had a known otogenic problem or a recent upper respiratory illness. Each patient underwent otoscopic examination, tympanometry, nasopharyngoscopy, evaluation of gag reflex and soft palate movement. Some patients underwent fiberoptic endoscopic evaluation of swallowing with sensory testing (FEESST).

## 3. Results

Of the 20 patients recruited, 17 were eligible and fully evaluated: 12 males and five females, aged 18-93 years (average 57.8). The period of tube feeding and mechanical ventilation was three months and up to 15 and 18 years, respectively. All patients had a normal nasopharynx, lacked a gag reflex, had no palatal movement and no response to laryngeal stimulating by touching it with the tip of the fiberscope. Otoscopy of 34 ears revealed 16 with OME (47%) and 18 normal aerated ears (53%). Tympanometry type B or C was documented in 20 ears (59%) and type A in 14 (41%).

Correspondence: Udi Cinamon, Department of Otolaryngology, Head & Neck Surgery, Wolfson Medical Center, 62 Halohamim St., Holon, Israel  
E-mail: [udicin@yahoo.com](mailto:udicin@yahoo.com)

*Cholesteatoma and Ear Surgery – An Update 2017, pp. 69 -70*  
*Edited by Matthew Yung*  
2017 © Kugler Publications, Amsterdam, The Netherlands

Seven patients had had FEESST which was abnormal. In this FEESST-group, eight ears were aerated and a corresponding tympanometry type A and six ears with OME had B curves.

Noteworthy, none of the participants had a high-grade TM atelectasis or cholesteatoma.

Twenty-four ears (70%) were impacted by cerumen. In comparison, the incidence of impacted cerumen in the general adult population is approximately 5-10%, while among older patients in nursing homes (57%) and in patients with mental retardation (36%).<sup>8,9</sup>

#### 4. Conclusions

1. Despite the fact that all patients had a dysfunctional ET, about half had normal ME and TM. This strongly supports that the ET is an important but not the only factor maintaining and regulating ME pressure.
2. The majority of patients had a significant cerumen blockage and OME, which, individually and especially combined, may cause a hearing impairment. This may be of importance in patients having a better rehabilitation prognosis.<sup>10</sup>

#### References

1. Chang KH, Jun BC, Jeon EJ, Park YS. Functional evaluation of paratubal muscles using electromyography in patients with chronic unilateral tubal dysfunction. *Eur Arch Otorhinolaryngol* 2013;270:1217-1221.
2. Honjo I, Okazaki N, Kumazawa T. Experimental study of the Eustachian tube function with regard to its related muscles. *Acta Otolaryngol* 1979;87:84-89.
3. Honjo I, Okazaki N, Kumazawa T. Opening mechanism of the Eustachian tube. A clinical and experimental study. *Ann Otol Rhinol Laryngol Suppl* 1980;89:25-27.
4. Bluestone CD. Eustachian tube function: physiology, pathophysiology, and role of allergy in pathogenesis of otitis media. *J Allergy Clin Immunol* 1983;72:242-251.
5. Ishijima K, Sando I, Balaban CD, Miura M, Takasaki K. Functional anatomy of levator veli palatini muscle and tensor veli palatini muscle in association with Eustachian tube cartilage. *Ann Otol Rhinol Laryngol* 2002;111:530-536.
6. Sadé J, Ar A. Middle ear and auditory tube: middle ear clearance, gas exchange, and pressure regulation. *Otolaryngol Head Neck Surg* 1997;116:499-524.
7. Cinamon U. Passive and dynamic properties of the Eustachian tube: quantitative studies in a model. *Otol Neurotol* 2004;25:1031-1033.
8. McCarter DF, Courtney AU, Pollart SM. Cerumen impaction. *Am Fam Physician* 2007;75:1523-1528.
9. Crandell CC, Roeser RJ. Incidence of excessive/impacted cerumen in individuals with mental retardation: a longitudinal investigation. *Am J Ment Retard* 1993;97:568-74.
10. Thaut MH, McIntosh GC. How Music Helps to Heal the Injured Brain: Therapeutic Use Crescendos Thanks to Advances in Brain Science. *Cerebrum* 2010. <http://dana.org/news/cerebrum/detail.aspx?id=26122>.

# FACIAL PARALYSIS IN CHRONIC OTITIS MEDIA

Vincent C. Cousins

*The Alfred Hospital, Melbourne and Department of Surgery, Monash University, Melbourne, Australia*

## 1. Introduction

Chronic otitis media (CSOM) is still seen commonly across all countries of the world. Complications, both intra-temporal and intracranial, still present with variable frequency. Facial paralysis is one important complication that needs to be managed early to minimize long-term patient morbidity.

## 2. Causes of paralysis

CSOM without or with cholesteatoma may be responsible for facial paralysis. Cholesteatoma can involve any segment of the facial nerve from the internal auditory canal (IAC) to the stylomastoid foramen by direct contact with disease in the middle ear cleft or via its extension into the petrous temporal bone. Non-cholesteatomatous disease affecting the nerve is generally confined to the horizontal and vertical segments.

Surgery of the middle ear and mastoid also provided the opportunity for facial nerve injury. This may occur due to direct nerve damage (blunt or sharp) caused by surgical instruments and otologic drills or thermal injury due to diathermy or laser application. Direct injuries may be crush injuries, partial or complete lacerations, or areas of loss of nerve substance.

Delayed postoperative paralysis may be seen due to compression secondary to haematoma formation or mastoid cavity packing.

When the facial nerve has no protective bone cover, it may be more easily affected. Dehiscent areas may be present congenitally or occur secondary to bone erosion by the pathologic process. An unprotected nerve may be more easily infected by the primary pathology leading to an active neuritis, easily compressed or eroded by a pathological mass lesion or traumatised by instrumentation.

## 3. Levels of intervention

The degree of intervention required in managing facial paralysis occurring secondary to CSOM will depend on the particular circumstances of the case.

Uncomplicated cases of CSOM should be recognized and managed early to **prevent** progression and possible paralysis. When performing middle ear and mastoid surgery for CSOM, the chance of secondary facial paralysis will be minimized by excellent knowledge of temporal bone and nerve anatomy, detailed knowledge of the pathological processes as well as meticulous surgical technique assisted with facial nerve monitoring where appropriate.

In cases of CSOM or secondary trauma where there is a possibility of nerve discontinuity, the nerve should be **explored** in all affected segments and appropriate management undertaken.

Correspondence: Department of Otolaryngology Head & Neck Surgery, The Alfred Hospital, 55 commercial Road, Melbourne, Victoria, Australia, 3004.

E-mail: vccousins@iinet.net.au

*Cholesteatoma and Ear Surgery – An Update 2017, pp. 71 -74*

*Edited by Matthew Yung*

*2017 © Kugler Publications, Amsterdam, The Netherlands*

Early after the onset of paralysis, **decompression** will have a role. Drainage of middle ear fluid and pus and the use of intravenous antibiotics may be sufficient. In a progressive or total paralysis, mastoidectomy and surgical decompression of the involved segment(s) will be required.

Damaged nerves may be **repaired** primarily or with a **cable graft**.

Where there is no proximal nerve stump but viable distal nerve, a nerve **replacement** using nerves such as the hypoglossal or trigeminal branch to masseter can be employed. When nerve repair and replacement are not available and when a complete palsy has been present for more than 12 to 18 months, **substitution** techniques will be necessary, including nerve and /or muscle transfers and adjunctive eyelid weight and plastic procedures.

#### 4. Preoperative assessment

The history of the primary condition and of the occurrence and any progression of the paralysis are sought.

Associated symptoms of hearing loss and vertigo may suggest inner ear involvement and are fully assessed.

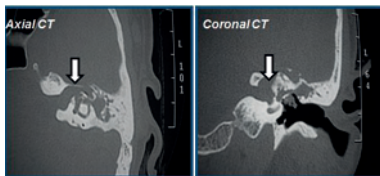


Fig. 1. Petrous bone cholesteatoma presenting with facial paralysis.

CT scanning is the mainstay of imaging and will show the extent of pathology and degree of bone erosion (Fig. 1). Complications of CSOM are often multiple in the same case due to long duration or severity of disease. MRI scanning offers better detail of intracranial extension than CT. Diffusion weighted MRI sequences can confirm the presence of cholesteatoma when necessary. CT contrast venography and/or MRI venography will identify

thrombosis of the dural venous sinuses.

Investigations assessing the infective aspects of the condition must be undertaken. Microbiologic specimens obtained before or during surgery are sent for culture and other pathologic assessment. Results are used to direct appropriate antimicrobial therapy. Lumbar puncture and CSF analysis will be required in cases of suspected meningitis.

#### 5. Operative management

The imaging should be able to identify the site or sites of expected facial nerve involvement thus directing the surgical approach(es) required. Hearing preserving techniques (including canal-wall-up and canal-wall-down mastoidectomy) will mostly be used, but a translabyrinthine or transotic approach may be required when the inner ear function has been already lost or significantly compromised.

Surgery must provide full exposure of the involved segments of nerve. Standard landmarks are used to identify the nerve in its normal position. Dissection is undertaken on both sides of the pathological segment and proceeds from normal to abnormal. High magnification is useful and facial nerve monitoring will help in some cases.

Other complications are managed as required. Inner ear fistulae should be suspected and identified early but are generally managed at the end of the procedure to minimize inner ear trauma.

All abnormal tissue is removed from the nerve and it is decompressed as necessary.

The nerve must be uncovered back to normal appearance on each side of the pathologic segment, with removal of granulation tissue and cholesteatoma and opening of the nerve sheath. Absorbable gauze soaked in antibiotic and steroid containing preparations may be applied directly to the nerve.

Areas of nerve loss should be debrided. In general, if more than 50% of the nerve cross section is intact, the nerve is left *in situ*. Larger defects are best resected back to healthy nerve and a primary repair undertaken if adequate length can be obtained with nerve re-routing. More commonly, a cable graft of greater auricular or sural nerve is used to repair the nerve leaving proximal and distal stumps in their native position. The graft should be

longer than one centimetre in order to separate the two anastomoses. 9/0 Nylon epineurial sutures may be used, but tension-free anastomoses can be achieved in the temporal bone by simply laying the cable in the open fallopian canal, abutting the stumps at each end and covering with fascia and possibly tissue glue.

Small defects of the nerve (less than 50%) may be repaired with a small inlay graft of donor nerve in a similar manner.

Iatrogenic nerve injury may be identified intra-operatively and should be managed in the same way.

When a facial palsy is identified post-operatively, the time course and severity must be assessed. Incomplete or delayed onset paralysis can be managed initially with early removal of any suspect packing and institution of intravenous steroids. Progression of weakness will mostly indicate the need for formal surgical decompression.

An immediate postoperative complete paralysis raises the possibility of a significant nerve injury. Early exploration and appropriate decompression or formal repair will be required.

All cases of facial paralysis will require patient support and explanation. Eye care, using lubricants will help avoid corneal injuries. Ophthalmology management is important in any case with more than a minimal weakness. Once facial movement has begun to return, appropriate physical exercise therapy is always used and assists in minimising aberrant nerve regrowth such as synkinesis.

## 6. Surgical results

In 11 cases of non-cholesteatomatous CSOM with facial palsy who required surgical exploration, eight achieved a Grade 1 to 2 (House-Brackman) result, having presented with up to Grade 5 weakness. Two presenting with grade 5 and 6 levels respectively achieved a Grade 3 result. One who presented with Grade 5 palsy of prolonged duration did not achieve any improvement despite the nerve being in anatomical continuity.

In 14 operative cases of cholesteatoma with facial palsy, and presenting with up to Grade 5 weakness, ten achieved a Grade 1 or 2 result. Two achieved a Grade 3 result having presented with Grade 5 and 6 palsies. One required a cable graft and achieved a Grade 4 result and one presenting with Grade 5 showed no improvement.

## 7. Conclusions

Facial paralysis still occurs as a complication of CSOM, and sometimes with other intra-temporal or intracranial complications. These patients need early assessment and timely surgical intervention coupled with appropriate antimicrobial therapy for the best outcome





# MIDDLE EAR GAS EXCHANGE PROBLEMS IN OTITIS MEDIA WITH EFFUSION AND ACQUIRED CHOLESTEATOMA

Zsuzsanna Csakanyi, Gabor Katona

*Department of Otorhinolaryngology, Heim Pal Children's Hospital, 1089 Budapest, Hungary*

## 1. Background

Gas pressure balance is substantial for normal middle ear (ME) function. However, mechanisms involved in the ME pressure control are still not fully understood. The role of ET dysfunction and temporal bone anatomical variations is substantial in the development of otitis media with effusion (OME).<sup>1</sup> It is generally accepted that ME gas pressure deregulation are associated with prolonged OME, tympanic membrane structural changes and acquired cholesteatoma. Nevertheless, prediction and prevention of intractable OME cases remain our professional challenges.

It is known that periodic ET openings enable the ME cavity to replenish itself with air and maintain a steady state balance.<sup>2</sup> The tympanic membrane (TM) as an active pressure buffer compensates for small, sudden pressure changes. We think that the mastoid serves as a pressure buffer proportionally to its volume. Furthermore, its morphology suggests that gas exchange takes place between the ME and the surrounding mucosal venous blood in the epitympanum and the mastoid air cells, which results in ME pressure decrease<sup>3,4</sup> The surface area of the mucosal lining is one of the determining factors of gas exchange in the ME. The gas flow rate during the passive gas exchange is directly proportional to the extent of surface area, and the rate of ME pressure decrease depends on the surface-to-volume ratio.

## 2. Objective

Our objective was to examine how temporal bone anatomical variations may contribute to the OME pathogenesis. One possible theoretical approach is simple geometrical. The surface-to-volume ratio of any geometric shape decreases as the volume increases as a nonlinear function. We assumed that human MEs follow this trend and the surface-to-volume ratio is higher in smaller MEs. Consequently, the gas exchange is faster, thus, the pressure fluctuations between ET openings are greater here, than in larger MEs.

## 3. Method of approach

Comparative analysis of 3D CT reconstruction data of temporal bones in healthy children (aged two to 18 years) and age-matched children with prolonged OME with and without TM structural changes [for detailed description see refs. 5 and 6].

Correspondence: Zsuzsanna Csakanyi  
E-mail: csakanyi.zsuzsanna@gmail.com

*Cholesteatoma and Ear Surgery – An Update 2017, pp. 75 -78*  
*Edited by Matthew Yung*  
2017 © Kugler Publications, Amsterdam, The Netherlands

A mathematical description and MatLab® modeling of the ME pressure development is presented in the function of different ME volumes ( $V_{ME}$ ), considering normal and malfunctioning ET. Published human gas pressure data as input values and our 3D CT reconstruction data of healthy and pathological MEs of children are applied.

#### 4. Results

Three-dimensional CT reconstruction data of our healthy and pathological temporal bones showed that ears of children with prolonged OME have significantly higher mean surface-to-volume ratio (more than one and a half times) than healthy ears and smaller mean ME volume than three ml. OME cases with TM structural changes have the smallest mean ME volume. The results show that the mean ME volume in healthy preschool children is 3.2 ml, in young school children is 6.0 ml. These values are significantly smaller in prolonged OME cases, fairly below two ml. Prolonged OME cases show a very slow growing tendency with age, larger during puberty, while in OME cases showing ME structural changes the mean ME volume decreases with age.<sup>7</sup>

The mathematical model predicted that at perfect ET function, in a one-ml ME the dynamic pressure balance stabilizes with small pressure fluctuations (values within the pars flaccida buffering capacity), when ET opens every 90 seconds. The model estimates showed that perfect ET function in  $V_{ME} < \text{three ml}$  still results in much greater ME total pressure (TP) fluctuations than in  $V_{ME} \geq \text{three ml}$ . Transient or prolonged ET dysfunction causes pressure fluctuations of an order of magnitude larger. These are inversely proportional to the ME volume. Modeling mastoid obliteration situation (MAO) METP fluctuations in a  $V_{ME} = 0.6 \text{ ml}$  become similar to that in a  $V_{ME} > \text{three ml}$ .

#### 5. Discussion

At transient ET dysfunction, larger pressure fluctuations in smaller MEs represent greater strain on the TM and can initiate changes in TM behavior. At prolonged ET dysfunction, the ME pressure decrease in smaller MEs exceeds the capillary hydrostatic pressure when effusion accumulates in the ME from blood vessels decreasing the ME volume and surface area for gas exchange.<sup>8</sup> This mechanism compensates for high negative ME pressure and normalizes hearing. If ET dysfunction recovers, effusion eliminates.<sup>9</sup>

The model predictions revealed that in MEs over six ml the METP fluctuations are so small, that they have nearly constant METP and stable gas pressure balance due to larger volume and smaller surface-to-volume ratio and can tolerate even longer periods of ET dysfunction while maintaining gas pressure balance. However, as the ME volume decreases, the passive pressure buffer capacity of the mastoid reduces and the surface-to-volume ratio increases. Faster gas exchange results in larger METP fluctuations and a larger strain on the TM as long as effusion accumulates. These MEs require frequent ET opening to maintain normal ME function (normal hearing).<sup>10</sup>

The measured mean ME volume of our healthy schoolchildren was 6.0 ml, in preschool children was 3.2 ml. ET dysfunction is very common at preschool children that may easily lead to ME gas pressure deregulation and may initiate ME pathology due to smaller volume and higher surface-to-volume ratio. These results are consistent with clinical findings.

Depending on the ME volume and the duration of ET dysfunction larger pressure fluctuations may initiate transient or permanent changes in the TM behavior. Prolonged ET dysfunction results in persistent effusion that may contribute to chronic ME granulation and ossification of the bony mastoid, narrowing the ME volume, changing ME geometry and leading to chronic otitis media with or without cholesteatoma. Accordingly, the prolonged OME cases with TM structural changes showed a slight ME volume decrease with age.

Mastoid obliteration proved to be effectively improve long-term outcome in cholesteatoma surgery.<sup>11-14</sup> During the obliteration procedure, the mucosal lining of the mastoid and the epitympanum responsible for gas exchange

is eliminated. According to the model estimates, gas pressure balance in this small MEs with poor ET function becomes similar to that of three ml or larger MEs. It can be considered as a surgical adaptation of the ME gas pressure balance to the limited outer gas supply due to prolonged ET dysfunction. As a result, development of ME pathology and long-term changes in TM behavior can be limited. MAO with disproportionate surgical reduction of gas exchange surface can be curative in pathological MEs, where mastoid has lost its pressure buffer capacity and ET is dysfunctional, lowering the recurrence rate and improving long-term outcome.

## 6. Conclusion

The data support that MEs between three to six ml are very sensitive to the duration of ET dysfunction. The mastoid volume, extent and duration of ET dysfunction, which can differ individually, are determinant in initiating ME pathology and in clinical course. The ME volume and surface area-to-volume ratio are potential predictors of the ME gas pressure balance. These parameters can be important to consider for a pathophysiology-oriented approach to the ME surgery that may improve the long-term outcome.

## References

1. Fink N, Ar A, Sadé J, et al. Mathematical analysis of atelectasis formation in middle ears with sealed ventilation tubes. *Acta Physiol Scand* 2003;177:493-505.
2. Gaihede M, Dirckx JJ, Jacobsen H, et al. Middle ear pressure regulation- complementary active actions of the mastoid and the eustachian tube. *Otol Neurotol* 2010;31:603-611.
3. Ars B, Ars-Piret N. Morpho-functional partition of the middle ear cleft. *Acta Otorhinolaryngol Belg* 1997;51:181-184.
4. Ars B, Wuyts F, Van de Heyning P, et al. Histomorphometric study of the normal middle ear mucosa. Preliminary results supporting the gas-exchange function in the postero-superior part of the middle ear cleft. *Acta Otolaryngol* 1997;117:704-707.
5. Csakanyi Z, Katona G, Josvai E, et al. Volume and surface of the mastoid cell system in otitis media with effusion in children: a case-control study by 3D reconstruction of computed tomographic images. *Otol Neurotol* 2011;32:64-70.
6. Csakanyi Z, Katona G, Konya D, et al. Middle ear gas pressure regulation: the relevance of mastoid obliteration. *Otol Neurotol* 2014;35(6):944-953.
7. Hasebe S, Takahashi H, Honjo I, et al. Organic change of effusion in the mastoid in otitis media with effusion and its relation to attic retraction. *Int J Pediatr Otorhinolaryngol* 2000;53:17-24.
8. Alper CM, Tabari R, Seroky JT, et al. Magnetic resonance imaging of the development of otitis media with effusion caused by functional obstruction of the Eustachian tube. *Ann Otol Rhinol Laryngol* 1997;106:422-431.
9. Sadé J, Handrich Y, Bernheim J, et al. Pressure equilibration in the penguin middle ear. *Acta Otolaryngol* 2008;128:18-21.
10. Doyle WJ. The mastoid as a functional rate-limiter of middle ear pressure change. *Int J Pediatr Otorhinolaryngol* 2007;71:393-402.
11. Silvola J, Palva T. Long-term results of pediatric primary one-stage cholesteatoma surgery. *Int J Pediatr Otorhinolaryngol* 1999;48:101-107.
12. Takahashi H, Sato H, Nakamura H, et al. Correlation between middle-ear pressure-regulation functions and outcome of type-I tympanoplasty. *Auris Nasus Larynx* 2007;34:173-176.
13. Sun J, Sun J, Hu Y, et al. Canal-wall-down mastoidectomy with mastoid obliteration for pediatric cholesteatoma. *Acta Otolaryngol* 2010;130:259-262.
14. Vercruysse JP, De Foer B, Somers T, et al. Mastoid and epitympanic bony obliteration in pediatric cholesteatoma. *Otol Neurotol* 2008;29:953-960.



# CURRENT TRENDS IN MANAGING COMPLICATIONS OF CHRONIC OTITIS MEDIA WITH CHOLESTEATOMA

Jyoti P. Dabholkar, Jaini Lodha, Nitish Virmani

*Department of Otorhinolaryngology, Seth G.S Medical College and KEM Hospital, Mumbai, India*

## 1. Introduction

Complications secondary to cholesteatomatous otitis media are associated with significant morbidity and mortality. Despite a significant decline in the incidence of these complications in developed countries, they still pose a considerable challenge in developing countries such as India. Low socio-economic status of a majority of population is one of the most important factors predisposing to a high rate of complications. The present study has been conducted to outline our experience in managing intracranial and extracranial complications of cholesteatoma. Being a tertiary care centre with a high influx of referrals, we routinely encounter different types of complications. Their clinicopathological behavior, diagnostic modalities, treatment options and surgical outcomes have been reviewed. We emphasize the importance of accurate and early diagnosis followed by appropriate surgical therapy with multidisciplinary approach.

## 2. Materials and Methods

This study was a retrospective review of the archives of the Department of Otolaryngology at King Edward Memorial Hospital in India, a tertiary care referral center. We accessed the clinical charts of patients with cholesteatoma who had presented with clinical or radiological evidence of complications and had undergone surgical interventions between 2009 and 2014. The patients were contacted to arrange for follow-up visits. Patient demographics, clinical presentation, clinical course, investigations, management and postoperative outcomes were analyzed.

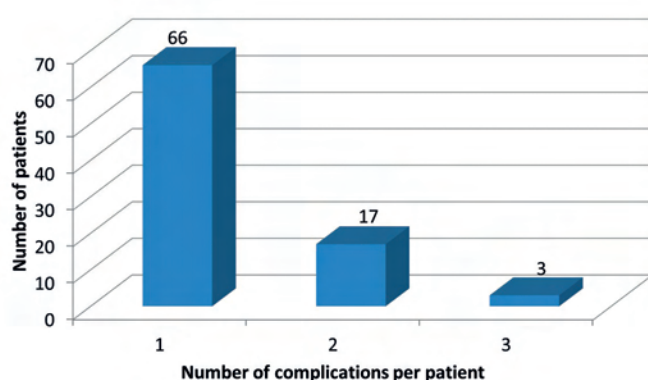


Fig. 1. Graph showing number of complications per patient.

## 3. Observations and Results

Over a five-year period between 2009 and 2014, 469 patients underwent surgery for cholesteatoma in our hospital. Eighty-six (18.33 %) of these had presented with clinical or radiological evidence of complications. Of these 86 patients, 20 (23.2 %) presented with multiple complications simultaneously (Fig. 1).

Correspondence: Dr. Nitish Virmani, H. No. 576, Sector-37, Faridabad, Haryana, 121003, India.  
E-mail: nitish\_virmani@yahoo.com

*Cholesteatoma and Ear Surgery – An Update 2017, pp. 79 -82*

*Edited by Matthew Yung*

*2017 © Kugler Publications, Amsterdam, The Netherlands*



*Table 1.* Extracranial complications of cholesteatoma observed in the study group (n = 75).

Complications	Number of patients
Facial palsy	14
Labyrinthine fistula	22
Labyrinthitis	1
Post-auricular abscess	30
Zygomatic abscess	2
Neck abscess	6

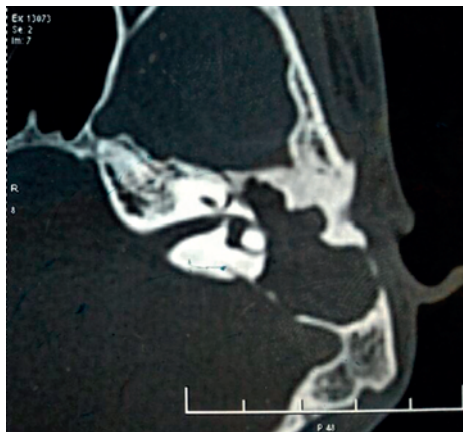*Table 2.* Intracranial complications of cholesteatoma observed in the study group (n = 34).

Complications	Number of patients
Meningitis	15
Lateral sinus thrombophlebitis	9
Subdural empyema	5
Brain abscess	15

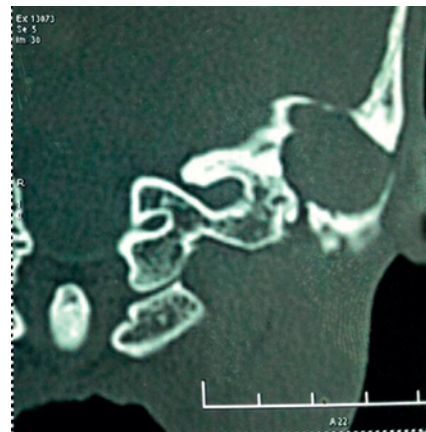Extracranial complications (75, 68.8%) dominated the clinical picture and included labyrinthine fistula, facial paralysis, zygomatic abscess, post-auricular abscess, neck abscess and labyrinthitis (Table 1).

Intracranial complications (34, 31.2%) included meningitis, brain abscess, sigmoid sinus thrombophlebitis and subdural empyema. The reliable warning signs and symptoms of IC complications were fever, headache, earache, vestibular symptoms, meningeal signs and impairment of consciousness (Table 2).

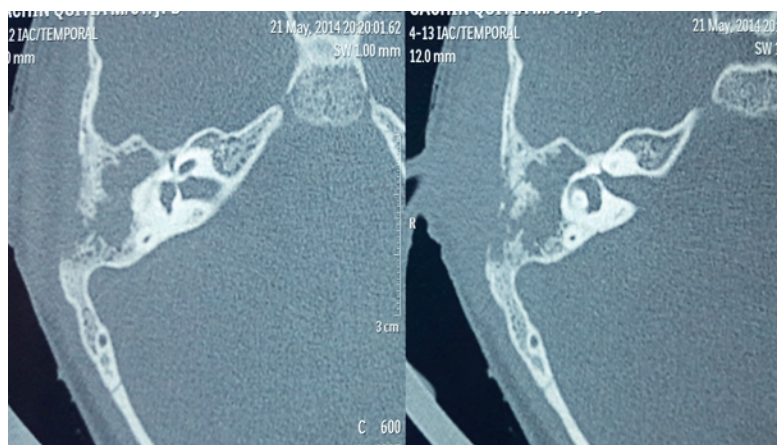
Imaging in the form of HRCT temporal bone and CT/MRI Brain with contrast was done in all cases to establish the diagnosis. (Figs. 2, 3 and 4) The initial management of these complications differed significantly. While meningitis and sigmoid sinus thrombophlebitis were controlled by parenteral antibiotics, brain abscess required craniotomy and drainage. This was followed by definitive otological surgery when the patient was neurologically stable. Extracranial abscesses underwent drainage of pus followed by surgery after 7-10 days of antibiotics. We



*Fig. 2.* HRCT Temporal bone showing erosion of lateral semicircular canal (labyrinthine fistula).



*Fig. 3.* HRCT Temporal bone showing erosion of vertical segment of facial canal by cholesteatoma.



*Fig. 4.* HRCT Temporal bone showing erosion of lateral mastoid cortex causing post-auricular abscess.

believe in canal wall down (CWD) mastoidectomy as the definitive procedure for complete eradication of cholesteatoma. Labyrinthine fistula was managed by single staged matrix removal followed by closure of fistula. Decompression of facial nerve was done in patients with facial palsy. Residual disease or recidivism was observed in none of these patients.

#### 4. Discussion

Despite the incidence of the complications of cholesteatoma decreasing markedly in developed countries, it still poses a significant challenge in developing countries such as India. Lower socio-economic status of a majority of population predisposes them to recurrent ear infections. In addition, there is a lack of knowledge about the propensity of an ear problem to cause a life-threatening complication. This in turn leads to poor treatment seeking-patterns in the form of self-medication, visits to quacks and general practitioners. A specialist consultation is often delayed, leading to presentation at an advanced or complicated stage.<sup>1</sup> Increase in illness duration, being infected by multi drug resistant bacteria, being HIV positive and otalgia are independent factors found to predict disease complications.<sup>2</sup>

Being a tertiary referral centre, we tend to share a huge burden of referral/revision cases and also encounter complications very frequently. In recent times, there has been a notable shift towards predominant extracranial pattern of complications in developing countries.<sup>3</sup> In our study as well, extracranial complications accounted for more than two-thirds of cases. These are generally classified further as intra- and extra-temporal, which were roughly equally distributed in our patients.

Among intratemporal complications, labyrinthine fistula was the most common complication, followed by facial palsy. Among intracranial complications, brain abscess was the most common, followed by lateral sinus thrombophlebitis and meningitis. Overall, the commonest complication observed was post-auricular abscess, which is a sequela of lateral mastoid cortex erosion.

Any recent onset giddiness, facial asymmetry, deterioration of hearing, focal neurological deficit should prompt one to immediately suspect an impending complication and perform imaging of the temporal bone and brain. The preferred modality of investigation is HRCT Temporal bone with gadolinium enhanced MRI Brain to look for intracranial complications.

In literature, the natural incidence of facial nerve paralysis ranges from 20-74%.<sup>4</sup> The most common site of dehiscence is the tympanic segment. The prevalence of facial nerve paralysis due to chronic otitis media with or without cholesteatoma is around 3%. In our series, we noted a 2.9% incidence of facial nerve palsy in cholesteatoma cases. The reason for the paralysis is due to toxins and enzymatic activity of cholesteatoma causing bony destruction. We have treated this with limited bony decompression of the facial nerve around the dehiscence segment with good recovery in postoperative period.

Labyrinthine fistula which is one of the commonly encountered complications is treated with direct single stage matrix removal and in addition we have used bone paté and fascia to cover the fistula after ensuring complete eradication of disease.<sup>5</sup>

Intracranial complications require urgent neurological management before ear surgery can be considered. While meningitis and sigmoid sinus thrombophlebitis were first controlled by parenteral antibiotics, brain abscess required craniotomy and drainage by neurosurgery team. Systemic anti-coagulants do not seem to offer any benefit in cases of sigmoid sinus thrombophlebitis. Definitive otological surgery is considered when the patient is neurologically stable. Surgical technique for sigmoid sinus thrombophlebitis has often remained a matter of debate. Sinus incision and thrombectomy or clot evacuation which used to be performed earlier does not seem to improve recanalization.

Definitive otological surgery in all complicated CSOM cases is canal-wall-down (CWD) mastoidectomy with complete eradication of the disease.

## 5. Conclusion

Complications secondary to cholesteatoma still remain a formidable challenge in developing countries. A high index of suspicion is necessary to prevent significant morbidity and mortality. HRCT plays a pivotal role in diagnosis of both intracranial and extracranial complications. While the initial management may differ, a canal wall down mastoidectomy remains the most reliable surgical procedure in these patients.

## References

1. S H C, M M K, Handi P, et al. To Study the Level of Awareness About Complications of Chronic Suppurative Otitis Media (CSOM) in CSOM Patients. *J Clin Diagn Res* 2014;8(2):59-61.
2. Mushi MF, Mwalutende AE, Gilyoma JM, et al. Predictors of disease complications and treatment outcome among patients with chronic suppurative otitis media attending a tertiary hospital, Mwanza Tanzania. *BMC Ear, Nose, and Throat Disorders* 2016;16:1.
3. Orji FT, Ukaegbe O, Alex-Okoro J, Ofoegbu VC, Okorafor IJ. The changing epidemiological and complications profile of chronic suppurative otitis media in a developing country after two decades. *Eur Arch Otorhinolaryngol* 2016;273(9):2461-2466.
4. Di Martino E, Sellhaus B, Haensel J, et al. Fallopian canal dehiscences: a survey of clinical and anatomical findings. *Eur Arch Otorhinolaryngol* 2005;262(2):120-126
5. Moon IS, Kwon MO, Park CY, Hong SJ . Surgical management of labyrinthine fistula in chronic otitis media with cholesteatoma. *Auris Nasus Larynx* 2012;39(3):261-264.

# THE SURGICAL MANAGEMENT OF TEMPORAL BONE CHOLESTEATOMA INVOLVING THE JUGULAR FORAMEN

Chunfu Dai

*Otology & Skull Base Surgery Department, Eye, Ear, Nose & Throat hospital, Fudan University, Shanghai, 200031, China*

## 1. Background

Temporal bone cholesteatoma may arise from embryonic epithelial remnant in the petrous bone or an acquired middle ear cholesteatoma. Cholesteatoma involving the jugular foramen is rare. Clinical findings such as symptoms or signs are frequently non-specific in cases of temporal bone cholesteatoma.<sup>1</sup> Temporal bone high-resolution computed tomography (HRCT) and magnetic resonance imaging (MRI) are the most reliable methods for providing appropriate identification and differential diagnosis of the lesions, as well for planning surgical approaches, and for detecting recurrence after surgery. However, the surgical removal of cholesteatoma in this region is a great challenge for the skull base surgeons. In the present study, we retrospectively reviewed 18 cases with temporal bone cholesteatoma involving the jugular foramen. All these cases underwent surgical intervention. The surgical approaches, intraoperative findings and surgical outcomes were retrospectively reviewed.

## 2. Clinical data

Eighteen patients were enrolled during 2006-2016 in the Department of Otology and Skull Base Surgery of the Eye, Ear, Nose and Throat Hospital at the Fudan University, Shanghai, China. All patients underwent thorough clinical otoneurologic examination. Audiologic examinations were performed preoperatively and in follow-up visits. Temporal bone HRCT and MRI with axial and coronal images were conducted in all patients. Once the lesion involved the facial nerve, or the patients presented incomplete facial paralysis, facial nerve electronystagmography (ENG) was performed.

## 3. Results

Eight cases were female, ten cases were male; eight cases in the left side, ten in the right. The age ranged from 26-68 years. The symptoms included hearing loss (17/18), otorrhea (eight out of 18), pulsatile tinnitus (seven out of 18), and headache (two out of 18). Ten patients complained of facial paralysis, no patients suffered from dysfunction of the lower cranial nerves. All patients underwent an infratemporal fossa approach with facial fallopian canal bridge technique. The jugular foramen showed erosion in all 18 cases, the horizontal segment of ICA was encroached in six cases, the sigmoid sinus and posterior fossa were compressed in 17 cases. In two cases, the clivus was destructed.

The facial nerve had remained intact in six patients, a cable graft was conducted in two patients, facial hypoglossal nerve anastomosis was performed in two patients. Intraoperatively, cerebrospinal fluid (CSF) leakage

Correspondence: Chunfu Dai, 83 Fenyang Rd, Shanghai, 200031, China  
E-mail: cfdai66@163.com

*Cholesteatoma and Ear Surgery – An Update 2017, pp. 83 -86*  
*Edited by Matthew Yung*  
*2017 © Kugler Publications, Amsterdam, The Netherlands*

incurred in nine patients, in three cases the sigmoid sinus or jugular bulb erupted and sigmoid sinus occlusion with jugular vein ligation was performed. The Eustachian tube was packed with temporal muscle and bone wax, the surgical cavity was packed with abdominal fat, blind sac closure was conducted in all patients. No major complications were observed.

#### 4. Discussion

Temporal bone cholesteatoma is a slow-growing expansile lesion in the petrous bone with an incidence of 4-9% of all petrous pyramid lesions. The rarity of these lesions, the slow and silent growth pattern, their complex location in the skull base, the proximity to vital neurovascular structures and the tendency to recur make temporal bone cholesteatoma very challenging to diagnose and manage.<sup>2,3,4</sup> In case of temporal bone cholesteatoma involving the jugular foramen, the close proximity of the disease to the labyrinth, the facial nerve, the jugular bulb and the internal carotid artery threaten the hearing and facial nerve function and create risk of CSF leakage as well as blood loss.

The main challenges of dealing with temporal bone cholesteatoma lie both in diagnosis and management: diagnostic challenges are due to a delay in identification of the disease because of its silent and slow growth pattern; therapeutic challenges are due to the difficulty in the complete surgical removal of the disease because of its complex location. Diagnostic challenges have been partly surmounted by the introduction of techniques specific to cholesteatoma, like diffusion-weighted imaging (DWI) which has made it possible to detect lesions early and early recurrences in patients after surgery.

Surgery with radical removal is the mainstay of treatment for temporal bone cholesteatoma involving the jugular foramen. The infratemporal fossa approach provides an excellent exposure of the clivus, the petrous apex, the dura of the posterior and middle fossa, the sigmoid sinus, the jugular bulb, and the internal carotid artery. Management of the facial nerve is one of the many challenging aspects of lateral skull-base surgery, especially in temporal bone cholesteatoma where the nerve is likely to be involved.<sup>5,6,7</sup> In this study, we applied skeletonization (fallopian canal bridge technique) in six cases. The facial nerve function was preserved in all six patients, cable motor nerve graft or hypoglossal facial nerve anastomosis were conducted in another four patients. In four patients, the facial nerve function recovered partially.

Temporal bone cholesteatoma involving the jugular foramen also means the lesions involving the jugular bulb and internal carotid artery. Dealing with the jugular bulb is a delicate strategy. Preoperative images with magnetic resonance venography (MRV) must be carefully analyzed in two aspects: the relationship of the lesion with the jugular bulb and the patency of the contralateral venous drainage system.<sup>8,9,10</sup> In cases where the opposite venous drainage is patent, it is safe to occlude the jugular bulb or sigmoid sinus by intra- or extra-luminal packing with surgical and bone wax if it is injured during dissection. In the present study, three patients underwent occlusion of the jugular bulb due to damage while removing cholesteatoma from the jugular bulb. On the contrary, when the wall of the internal carotid artery is much thicker than that of the jugular bulb, careful dissection of cholesteatoma with fine bipolar coagulator from the internal carotid artery without damage is possible.<sup>11</sup>

An infratemporal-fossa approach with facial nerve canal bridge technique is a good option for patients with cholesteatoma involving the jugular foramen, which is sufficient to remove the lesion and control the vessels, as well to preserve the facial nerve function.

#### References

1. Sanna M, Khrais T, Mancini F, Russo A, Taibah A. Facial Nerve Management in Petrous Bone Cholesteatoma Surgery. In: *The Facial Nerve in Temporal Bone and Lateral Skull Base Microsurgery*, pp. 237-258. Stuttgart: Georg Thieme Verlag 2006.

2. Sanna M, Mazzoni A, Saleh E, Taibah A, Mancini F. The system of the modified transcochlear approach: a lateral avenue to the central skull base. *Am J Otol* 1998;19:88-97; discussion 97-88.
3. Sanna M, Pandya Y, Mancini F, Sequino G, Piccirillo E. Petrous bone cholesteatoma: classification, management and review of the literature. *Audiol Neurotol* 2011;16:124-136.
4. Sanna M, Piazza P, Shin SH, Flanagan S, Mancini F. Surgical Management of Class A and B Tumors. In: *Microsurgery of Skull Base Paragangliomas*, pp. 160-216. Stuttgart: Thieme 2013.
5. Sanna M, Saleh E, Khrais T, et al. The Transcochlear Approaches. *Atlas of Microsurgery of the Lateral Skull Base*, pp. 80-126. Stuttgart: Georg Thieme Verlag 2008.
6. Sanna M, Shin SH, Mancini F, Russo A, Taibah A, Falcioni M. *Middle Ear and Mastoid Microsurgery*. Stuttgart: Thieme 2012.
7. Sanna M, Zini C, Gamoletti R, Frau N, Taibah AK, Russo A, Pasanisi E. Petrous bone cholesteatoma. *Skull Base Surg* 1993;3:201-213.
8. Moffat D, Jones S, Smith W: Petrous temporal bone cholesteatoma: a new classification and long-term surgical outcomes. *Skull Base* 2008;18:107-115.
9. Omran A, De Denato G, Piccirillo E, Leone O, Sanna M: Petrous bone cholesteatoma: management and outcomes. *Laryngoscope* 2006;116:619-626.
10. Ozmen OA, Falcioni M, Lauda L, Sanna M: Outcomes of facial nerve grafting in 155 cases: predictive value of history and preoperative function. *Otol Neurotol* 2011;32:1341-1346.
11. Pandya Y, Piccirillo E, Mancini F, Sanna M: Management of complex cases of petrous bone cholesteatoma. *Annals Otol Rhinol Laryngol* 2010;119:514-525.





# PAST, PRESENT AND FUTURE TREATMENT OF BIOFILMS IN OTITIS MEDIA

Mat Daniel

*Otorhinolaryngology Head & Neck Surgery, Nottingham Children's Hospital / Nottingham University Hospitals, Nottingham, UK*

Otitis media with effusion (OME) is common, and at least a quarter of children require grommets more than once, with attendant risks. Better treatments would be welcome, especially if they obviate the need for repeat surgery, or avoid the requirement for anaesthesia and surgery altogether. Recent advances in our understanding of the importance of biofilms in otitis media pathogenesis<sup>1,2</sup> have opened up potential new treatment avenues that could improve patient care in the future.

Treatment of biofilms requires antibiotic levels that are typically 100 to 1000 times higher than concentrations that inhibit free planktonic bacteria. Systemically administered antibiotics do not reach levels in the middle ear sufficiently high to eradicate biofilms (at least not without causing systemic toxicity).<sup>3</sup> Ventilation tube (VT) insertion dries the middle ear and thus could suppress biofilms, but it may not eradicate them, possibly accounting for the high rate of OME recurrence after VT extrusion. Biofilms in the middle ear could be eradicated by administering antibiotics directly to the middle ear,<sup>4</sup> to reach an antibiotic level that is locally high enough to eradicate biofilms; drug delivery methods could include slow-release formulations placed surgically,<sup>5</sup> or trans-tympanic delivery. Oral treatment strategies could also be useful, but rely on appropriate selection of antibiotics that work well against biofilms, perhaps potentiated by agents to disrupt biofilm matrix and middle ear mucus.

In conclusion, better understanding of biofilms in otitis media has the potential to lead to development of better treatments in the future.

## References

1. Hall-Stoodley L, et al. Direct detection of bacterial biofilms on the middle-ear mucosa of children with chronic otitis media. *JAMA* 2006;296(2):202-211.
2. Daniel M, Imtiaz-Umer S, Fergie N, Birchall JP, Bayston R. Bacterial Involvement in Otitis Media with Effusion. *Int J Paed Otorhinolaryngol* 2012;76(10):1416-1422.
3. Belfield K, Bayston R, Birchall JP, Daniel M. Do orally administered antibiotics reach concentrations in the middle ear sufficient to eradicate planktonic and biofilm bacteria? A review. *Int J Pediatr Otorhinolaryngol* 2015;79(3):296-300.
4. Hoskison E, Daniel M, Al-Zahid S, et al. Drug delivery to the ear. *Ther Deliv* 2013;4(1):115-124.
5. Daniel M, et al. Biofilm eradication with biodegradable modified-release antibiotic pellets: a potential treatment for Glue Ear. *Arch Otolaryngol Head Neck Surg* 2012;138(10):942-949.

Correspondence: Mat Daniel, Department of Otorhinolaryngology Head & Neck Surgery Nottingham Children's Hospital / Nottingham University Hospitals Derby Rd Nottingham, NG7 2UH, UK.  
E-mail: matija.daniel@nottingham.ac.uk

*Cholesteatoma and Ear Surgery – An Update 2017, pp. 87-88*

*Edited by Matthew Yung*

*2017 © Kugler Publications, Amsterdam, The Netherlands*



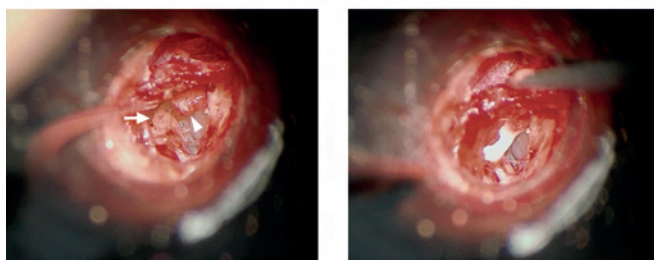
# HYDROXYAPATITE CEMENT FOR HEARING RECONSTRUCTION

Stefan Delrue, Joost van Dinther, Andrzej Zarowski, Thomas Somers, Erwin Offeciers

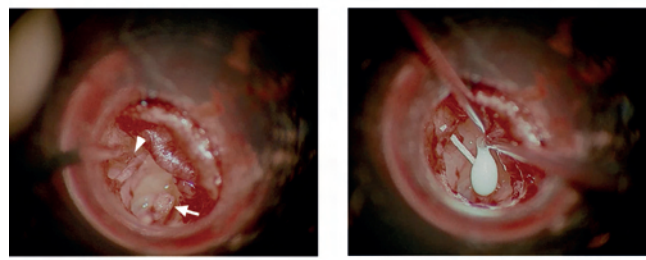
*European Institute for ORL – HNS, Sint-Augustinus Hospital, Wilrijk, Antwerp, Belgium*

## 1. Introduction

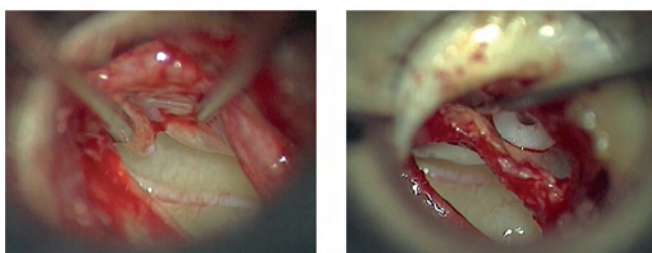
To overcome the impedance mismatch between the tympanic membrane and cochlear fluids, the normal ossicular chain functions as a lever system. Several surgical techniques are available to restore its continuity in case of interruption. Biocements are one of the latest innovations and allow maintaining the normal triossicular structure, which results in a more physiologic energy transfer.<sup>1,2</sup> Hydroxyapatite (HA) is an inorganic mineral and natural component of the human bone. It can be easily prepared by mixing a powder and a liquid component, which subsequently forms a paste that slowly hardens. Compared to ionomeric cement, HA does not provoke any inflammatory reaction when in contact with the soft tissues of the middle ear.<sup>1</sup> HA cement allows to bridge incudostapedial discontinuity as well as other ossicular interruptions in a faster and easier way.<sup>2-9</sup> HA cement can also be used in revision stapes surgery to overcome erosion of the long process of the incus.<sup>10-12</sup>



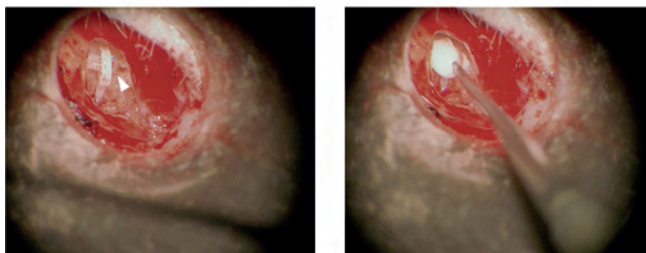
*Fig. 1.* Small incudostapedial interruption. (a) Intraoperative view showing discontinuity between the long process of the incus (arrowhead) and stapes head (arrow). (b) Situation after bridging with HA cement.



*Fig. 2.* More extensive incudal lysis. (a) Intraoperative view showing a large interruption between the remnant of the long process of the incus (arrowhead) and stapes head (arrow). (b) Bridging with HA cement. A Vicryl suture serves as a guide for the cement.



*Fig. 3.* Fracture of the malleus handle. (a) Intraoperative view showing a fracture at the level of the neck of the malleus. (b) Situation after bridging with HA cement. A grommet has been placed in order to avoid postoperative mobilization of the reconstruction provoked by a Valsalva maneuver.



*Fig. 4.* Revision stapes surgery. (a) Mobile stapes prosthesis due to erosion of the long process of the incus (arrowhead). (b) Stabilization of the prosthesis with HA cement.

Correspondence: Stefan Delrue, MD, European Institute for ORL – HNS, Sint-Augustinus Hospital, Oosterveldlaan 24, B-2610, Wilrijk, Antwerp, Belgium.  
E-mail: delrue.stefan@gmail.com

*Cholesteatoma and Ear Surgery – An Update 2017, pp. 89-92*

*Edited by Matthew Yung*

*2017 © Kugler Publications, Amsterdam, The Netherlands*

## 2. Video stills

Four different cases are presented in Figures 1, 2, 3 and 4. HA cement is used in a uniform way. After removal of some mucosa, a dry and bloodless field is created. The powder and liquid components are mixed (30–45 seconds) and applied within four minutes (working time). All excess material is removed to prevent fixation. The reconstruction is left undisturbed for ten minutes to allow drying and hardening.

## 3. Discussion

The use of HA cement in ossicular reconstruction and revision stapes surgery has been supported by the audiometric results of several studies.<sup>2–12</sup> In case of incudostapedial discontinuity, our group found a better intermediate air-bone gap gain with HA cement compared to incus remodeling.<sup>4</sup> In revision stapes surgery intermediate-term hearing outcome with HA cement is comparable to the outcome with a malleovestibular prosthesis.<sup>10</sup> No adverse reactions with HA cement have been reported so far.<sup>2–12</sup> Long-term audiometric results should be considered in future studies.

## 4. Conclusions

HA cement allows restoring the ossicular chain in a more physiologic way. Compared to standard ossiculoplasty techniques it is a faster and easier procedure. Audiometric results are good. In case of revision stapes surgery incus reconstruction with HA cement is safer than a more challenging malleovestibular prosthesis.

## References

1. Hoffmann KK, Kuhn JJ, Strasnick B. Bone cements as adjuvant techniques for ossicular chain reconstruction. *Otol Neurotol* 2003;24:24–8.
2. Babu S, Seidman MD. Ossicular reconstruction using bone cement. *Otol Neurotol* 2004;25:98–101.
3. Goebel JA, Jacob A. Use of Mimix hydroxyapatite bone cement for difficult ossicular reconstruction. *Otolaryngol Head Neck Surg* 2005;132:727–34.
4. Somers T, Van Rompaey V, Claes G et al. Ossicular reconstruction: hydroxyapatite bone cement versus incus remodelling: how to manage incudostapedial discontinuity. *Eur Arch Otorhinolaryngol* 2012;269:1095–101.
5. Elsheikh MN, Elsherief H, Elsherief S. Physiologic reestablishment of ossicular continuity during excision of retraction pockets: use of hydroxyapatite bone cement for rebridging the incus. *Arch Otolaryngol Head Neck Surg* 2006;132:196–9.
6. Galy-Bernadot C, Akkari M, Mathiolon C, Mondain M, Uziel A, Venail F. Comparison of early hearing outcomes of type 2 ossiculoplasty using hydroxyapatite bone cement versus other materials. *Eur Ann Otorhinolaryngol Head Neck Dis* 2014;131:289–92.
7. Gerard JM, De Bie G, Franceschi D, Deggouj N, Gersdorff M. Ossiculoplasty with hydroxyapatite bone cement: our reconstruction philosophy. *Eur Arch Otorhinolaryngol* 2015;272:1629–35.
8. Hato N, Okada M, Hakuba N, Hyodo M, Gyo K. Repair of a malleus-handle fracture using calcium phosphate bone cement. *Laryngoscope* 2007;117:361–3.
9. Delrue S, De Foer B, van Dinther J et al. Handling an Isolated Malleus Handle Fracture: Current Diagnostic Work-up and Treatment Options. *Ann Otol Rhinol Laryngol* 2015;124:244–9.
10. Van Rompaey V, Claes G, Somers T, Offeciers E. Erosion of the long process of the incus in revision stapes surgery: malleovestibular prosthesis or incus reconstruction with hydroxyapatite bone cement? *Otol Neurotol* 2011;32:914–8.

11. House JW, Lupo JE, Goddard JC. Management of incus necrosis in revision stapedectomy using hydroxyapatite bone cement. *Otol Neurotol* 2014;35:1312-6.
12. Hudson SK, Gurgel RK, Shelton C. Revision stapedectomy with bone cement: are results comparable to those of standard techniques? *Otol Neurotol* 2014;35:1501-3.





# 3D-CT ANALYSIS OF THE FMT ANGLE TO THE RW/OW AFTER VSB SURGERY

Katsumi Doi, Takeshi Fujita, Kazuya Saito, Kumi Kohama, Daisuke Nagatomi

*Department of Otolaryngology, Kindai University Graduate School of Medicine*

## 1. Introduction

In Japan, the clinical trial of VSB (Vibrant Soundbridge®, Med-El) implantation was completed in 2014, and the data concerning on the effectiveness and the safety of VSB surgery had already been published.<sup>1,2</sup> The VSB system was quickly approved by PMDA of the Ministry of Health, Labour and welfare in August 2015. In our institute, twelve cases underwent VSB implantation; round window vibroplasty (RWV) was completed in eleven cases and oval window vibroplasty (OWV) in one case.

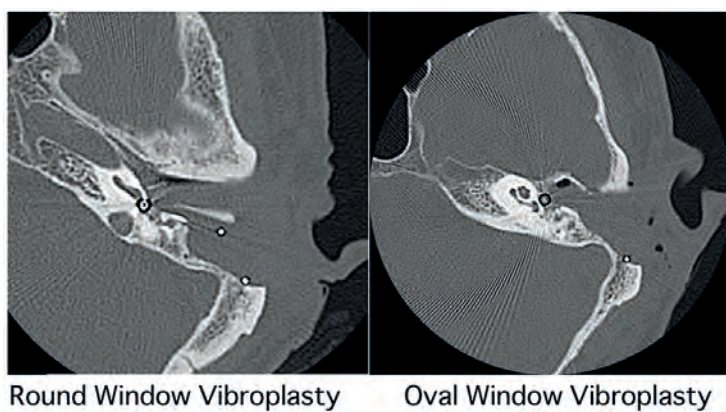


Fig. 1. Postoperative scans; 2D-CT images of the FMT in both RWV and OWV after VSB surgery

## 2. Materials and Methods

After VSB implantation, thin-sliced 2D-CT images (0.625 mm slice) with GE Discovery CT750 HD® (GE, USA) were collected (Fig. 1) and 3D-CT images were reconstructed with those 2D-CT images by using Zio station® (Amin, Japan).

The locations of round window (RW) and oval window (OW) were identified, the long-axis of FMT (Floating Mass Transducer) was strictly determined, and the angle of FMT to RW/OW (FMT angle) was measured. The difference in

threshold between open-field bone conduction (BC) and vibrogram (V) at each frequency was measured. This BC-V threshold should represent the efficacy in sound transmission with VSB system. The correlation between the FMT angle and the efficacy in sound transmission with VSB (BC-V threshold) was finally evaluated.

## 3. Case

The diagnosis of this case (64 years old, male) at his first visit was bilateral cholesteatoma otitis media and bilateral mixed hearing loss (Fig. 2). He underwent staged tympanoplasty (TP) with canal-wall-down (CWD) technique on both sides previously. Free-field PTA before and after the VSB surgery indicated that his hearing has been dramatically improved and stable at one year and two years after the surgery (Fig. 2).

Correspondence: Katsumi Doi, MD/PhD, 377-2, Oono-Higashi, Osaka-Sayama, 589-8511, Osaka, Japan.  
E-mail: kdoi@med.kindai.ac.jp

*Cholesteatoma and Ear Surgery – An Update 2017, pp. 93 -94*

*Edited by Matthew Yung*

*2017 © Kugler Publications, Amsterdam, The Netherlands*

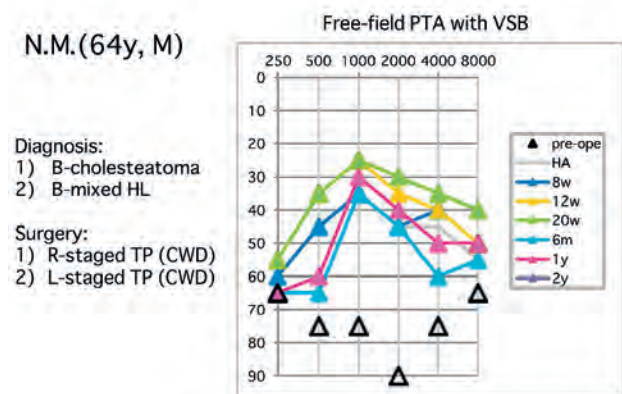


Fig. 2. Audiological evaluations of case N.M. before and after the VSB surgery.

N.M. (64y M, I-OWV)

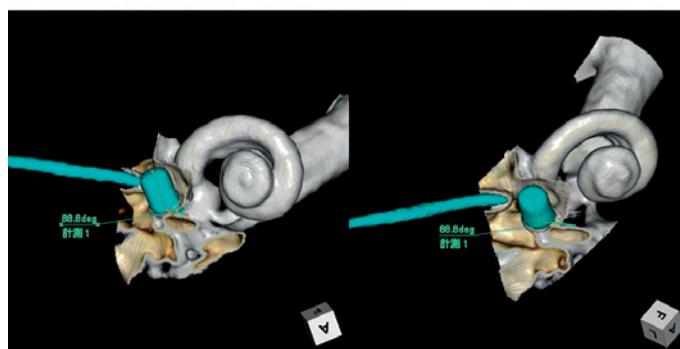


Fig. 3. 3D-CT images obtained from case N.M.

3D-CT images of the cochlea obtained from 2D-CT images from this case are shown in Figure 3. Since the OWV was performed in this case, due to a massive ossification in the RW area, the FMT was positioned on the OW on these images. The angle of the FMT to the OW could be determined as 88.8 degrees, which should indicate that the FMT was placed almost perfectly at the surgery.

#### 4. Correlation between the FMT angle and the BC-V threshold

The FMT angle was scattered from 36.9 degree to 83.9 degree ( $n = 11$ , RWV). The BC-V threshold (averaged at 1-4 kHz) was scattered from 15 to 31.7 dB ( $n = 11$ , RWV cases). The correlation between the FMT angle and the BC-V threshold did reach to a significant level ( $P = 0.049$ , Spearman rank correlation), indicating the negative correlation between them ( $y = -0.2494x + 38.21$ ,  $R^2 = 0.36322$ ).

#### 5. Discussion

The location of RW/OW and the long-axis of FMT were clearly identified with 3D-CT images reconstructed by using Zio station (Amin, Japan), and the angle of FMT to RW/OW (FMT angle) was successfully measured. The correlation between the FMT angle and the BC-V threshold (the efficacy in sound transmission with VSB) at 1-4 kHz was finally evaluated.

The efficacy in sound transmission with VSB was shown to be better as the FMT angle to the RW/OW became closer to 90 degree (more perpendicular to the surface of RW membrane). If the measurement of the FMT angle to the RW/OW during the VSB surgery could be possible in future, it might be helpful to achieve a better hearing performance with VSB.<sup>1,2</sup>

#### References

1. Doi K, Kanzaki S, Kumakawa K, et al. Evaluation of the effectiveness and safety in a multi-center clinical trial of VIBRANT SOUNDBRIDGE in Japan. *Nihon Jibiinkoka Gakkai Kaiho* 2015;118(12):1449-1458.
2. Kumakawa K, Kanzaki S, Usami S, et al. Multicenter clinical study of VIBRANT SOUNDBRIDGE in Japan: analysis of subjective questionnaires. *Nihon Jibiinkoka Gakkai Kaiho* 2015;118(11):1309-1318.

# HACETTEPE CARTILAGE SLICER: A NOVEL CARTILAGE SLICER AND ITS PERFORMANCE TESTS

Onur Ergun<sup>1</sup>, Munir Demir Bajin<sup>1</sup>, Mustafa Fevzi Sargon<sup>2</sup>, Levent Sennaroglu<sup>1</sup>

<sup>1</sup>Hacettepe University Faculty of Medicine, Otorhinolaryngology Head and Neck Surgery Department, Ankara, Turkey; <sup>2</sup>Hacettepe University Faculty of Medicine, Anatomy Department, Ankara, Turkey

Financial Disclosure: The authors have no financial disclosure to declare

Conflict Of Interest: The authors have no conflict of interest to declare

The preliminary results of this study was presented at 4th. National Otology Neurotology Congress, 21-24 April 2016, Antalya, Turkey and The 10th International Conference on Cholesteatoma and Ear Surgery, 5-8 June 2016, Edinburgh, United Kingdom as oral presentations.

## Abstract

**Objective:** This study investigates the performance of a cartilage slicer device, which is referred to as 'Hacettepe cartilage slicer' (HCS).

**Method:** Cartilage pieces were harvested from fresh frozen human ears and measured in thicknesses with a digital micrometer. Then, randomly sliced in four different thickness settings using two different types of blades. The thickness of the slices and remaining pieces were measured also.

**Results:** Thickness results showed a proportional increase with the increasing thickness setting with a  $\pm 0.1$  millimeter margin of error. The measurements proved that slices preserved over 95% of their structural integrity.

**Conclusion:** To our knowledge the current study is the first to evaluate the performance of a cartilage slicer device. When the thickness results were considered, HCS fulfilled its design goals, namely; consistently produced slices with a  $\pm 0.1$  mm tolerance and preserved over 95.3% of cartilage thickness which ensured undamaged strong cartilage slices.

## 1. Introduction

Cartilage has been preferred as a tympanic membrane (TM) graft material for its high success rate and good audiological results that are comparable to those of temporalis muscle fascia grafts.<sup>1,2</sup> Closure rates up to near 100% have been documented even at large perforations.<sup>3</sup>

Acoustic analysis of cartilage pieces at different thicknesses in an experimental setup using laser Doppler Interferometer estimated better acoustic gain if the cartilage graft was thinner than 0.5 mm.<sup>4</sup> Also, various tympanic membrane closure techniques need multiple overlapping thin cartilage pieces.<sup>5,6</sup> But hand-slicing a harvested cartilage into thin slices with a homogenous thickness is extremely difficult. This difficulty prompted surgeons to use devices for this purpose.

Correspondence: O. Ergun, Hacettepe Universitesi KBB ve BBC Anabilim Dalı, 06100, Sıhhiye, Çankaya, Ankara, Türkiye.  
E-mail: drergun@gmail.com

*Cholesteatoma and Ear Surgery – An Update 2017, pp. 95 -98*

*Edited by Matthew Yung*

*2017 © Kugler Publications, Amsterdam, The Netherlands*

Cartilage had become the graft material of choice in our institution for reconstruction of tympanic membrane perforations. The growing experience in cartilage tympanoplasty has led the way to design a cartilage slicer with some key features such as durable unibody design, ability to slice the cartilage without any damage, ease of use, adjustable cartilage thickness and ability to work with standard surgical blades.

## 2. Material and Methods

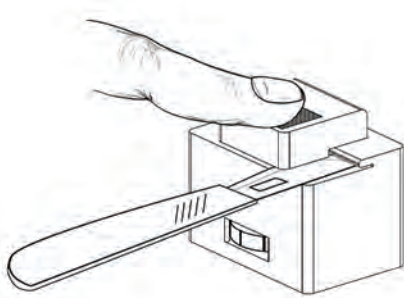


Fig. 1. Cutting a cartilage slice with a surgical scalpel.

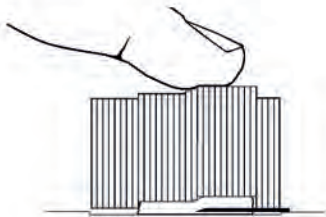


Fig. 2. The upward movement of the supporting pieces compensating the thickness of a single bevel blade.

HCS has an adjustable cartilage plate to determine the thickness of the slice. A wheel controls the height of the plate with 0.1-mm intervals (Fig. 1). Upper supporting plates of HCS protect the cartilage from being damaged during the pass of the blade. Vertical movements of the corresponding supporting plates also gave tactile feedback to the surgeon (Fig. 2). This system had been designed for single bevel blades but standard surgical scalpels with double bevel cutting edges could be used as well, although they are not perfect for HCS.

In order to objectively test the performance of HCS, a phase-0 clinical trial was planned and the approval of the Hacettepe University Non-Interventional Clinical Research Ethics Board was taken (GO16/19-07).

A professionally sharpened multi-use dermatome blade with a single bevel 'chisel type' cutting edge and No 20 disposable surgical scalpel blades (Aesculap, Tuttingen, Germany) with double bevel cutting edges were used during the experiment. During the experiment, disposable blades were changed after every four cuts. Four different thickness levels were tested for each blade type.

In order to measure the thickness of cartilage, a certified digital micrometer (Digimatic 0-25 mm digital micrometer, Mitutoyo, Kawasaki, Japan) was preferred with 0.001 mm claimed sensitivity. The micrometer had two circular measurement surfaces in eight mm of diameter and a torque limiter to apply a standard pressure to the specimen.

The harvested specimens were initially tagged with a code, measured in thickness then sliced randomly using one of the two blades and four thickness settings. Therefore, eight groups were created. After each slice, the thickness of the slice was measured by another researcher without any bias regarding the thickness setting and the result was recorded with a tag code. Following this step, the thickness of the remaining cartilage was also measured and recorded. After the experiment was completed, the results and thickness levels were matched using the tag codes and evaluated.

## 3. Results

The thickness results of the slices cut with the single bevel blade ranged between 0.15-0.66 mm and the average difference between the median values of the thickness levels was found to be 0.11 mm. The thickness results of the slices cut with the double bevel blade ranged between 0.33-0.71 mm and the average difference between the median values of the thickness levels were found out to be 0.06 mm. The median values of each thickness setting are given in Figure 3.

In order to assess whether undamaged slices could be cut with the HCS, the sum of the thickness of each slice



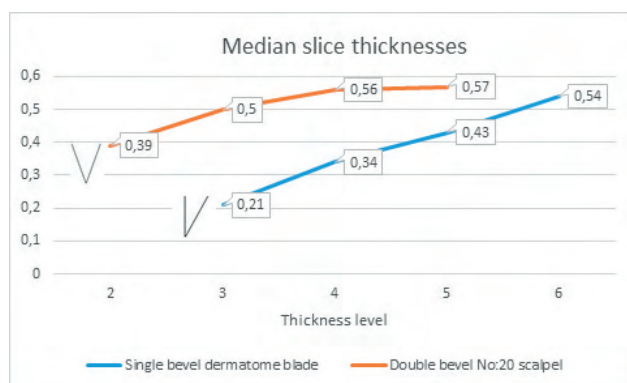


Fig. 3. Median value of slice thicknesses at different thickness levels and with different blades.

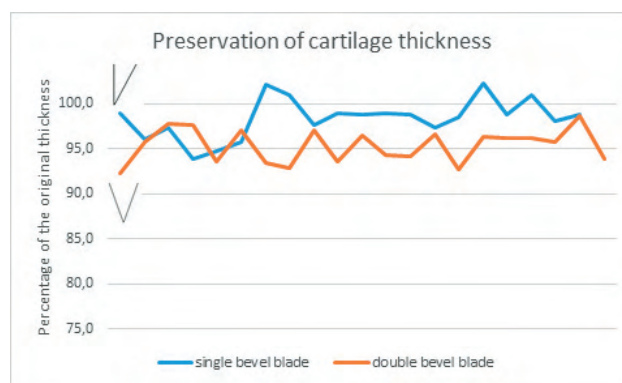


Fig. 4. Preservation of the cartilage thickness.

and its remaining part were compared to the thickness of the original harvested piece (Fig. 4). It was observed that the single bevel blade could preserve 98.4% of the original thickness in average, while the double bevel blade could preserve 95.3%.

#### 4. Discussion

Use of cartilage as a TM reconstruction material is not a new concept. It has been used since 1953,<sup>7</sup> but the use of cartilage has been increased in the last decade after high closure rates even with difficult cases such as Eustachian tube dysfunction has been documented. The audiological results of cartilage tympanoplasties are comparable to the results of temporalis muscle fascia tympanoplasties.<sup>1-3,8</sup>

Cartilage, as opposed to temporalis muscle fascia, has a higher structural strength and resistance against retraction and infection which makes it the graft material of choice for Eustachian tube dysfunction, atelectasis and chronic infected ears.<sup>1,5,8,9</sup> Its resistance against ischemia makes cartilage a good choice for smokers and revision cases where temporalis fascia may fail.<sup>8</sup> Although some chondrocyte degeneration occurs in time, especially towards the center of large perforations, the cartilage matrix remains intact and retains most of its structural support and elasticity.<sup>1</sup> Therefore, cartilage grafts may have higher closure rates than the temporalis fascia when the perforation is large.<sup>2,10</sup> Moreover, being an elastic and pliable material, cartilage is easier to shape and use.

With all these advantages, cartilage is a suitable graft material especially for revision cases, atelectasis, large perforations, cases with chronic Eustachian tube dysfunction, and smokers.

The only major pitfall of cartilage as TM reconstruction material is the possibility of hiding a cholesteatoma or a middle tympanic cavity pathology.<sup>6</sup> However, this risk is becoming insignificant thanks to the high sensitivity of rapidly developing imaging modalities such as non-echoplanar imaging sequences of MRI.<sup>11</sup>

The average tragal cartilage thickness was found to be between 0.879 and 1.432 mm depending on the age and sex of the patient, using a digital caliper.<sup>12</sup> A micrometer with wide circular measurement surfaces – instead of the sharp edges of a caliper – and a torque limiter to apply a standard pressure – instead of applying pressure manually – was considered to give more reliable results, and was therefore used in this study.

In order to enhance the devices performance, a 0.07-mm thick friction layer was added to the cartilage plate. Inevitably, that coating caused an misalignment and each thickness setting resulted in 0.07 mm thinner slices than their nominal values.

When a single bevel was used to slice, all the remaining cartilage was pushed upwards which was compensated by upper movable supporting pieces and a nice slice with equal thickness was left beneath the blade (Fig. 2). The average difference between the median values of each thickness level was 0.11 mm. This was concordant with our expectation because the adjustment wheel was set to elevate the cartilage plate 0.1 mm each time.



When a No 20 surgical blade (0.4 mm thick and double bevel) was used, the cutting edge met the cartilage 0.2 mm higher than a single bevel blade due to the half thickness of the blade. Taking the 0.07 mm thick friction coating in consideration, the 0.2 mm higher cutting edge should have given 0.13 mm thicker slices than the thickness setting. In fact, the median values of slices were 0.14 mm thicker than the thickness setting (Fig. 3), which was concordant with the expectations.

When the sum of thickness of each slice and its remaining counterpart was compared to the thickness of the original harvested piece, it was observed that 98.4% of cartilage thickness remained intact which fulfilled the design goal. This is considered to be a major advantage.

When the thickness results were considered, HCS fulfilled the design goal, namely, reliably producing consistent slices at the intended thickness with a  $\pm 0.1$  mm tolerance. A single-use single bevel blade would even offer better results.

## References

1. Khan MM, Parab SR. Comparative study of sliced tragal cartilage and temporalis fascia in type I tympanoplasty. *J Laryngol Otol* 2015;129(1):16-22.
2. Yung M. Cartilage tympanoplasty: literature review. *J Laryngol Otol* 2008;122(7):663-672.
3. Mundra RK, Sinha R, Agrawal R. Tympanoplasty in subtotal perforation with graft supported by a slice of cartilage: a study with near 100% results. *Indian J Otolaryngol Head Neck Surg* 2013;65(Suppl 3):631-635.
4. Murbe D, Zahnert T, Bornitz M, Huttenbrink KB. Acoustic properties of different cartilage reconstruction techniques of the tympanic membrane. *Laryngoscope* 2002;112(10):1769-1776.
5. Beutner D, Huttenbrink KB, Stumpf R, et al. Cartilage plate tympanoplasty. *Otol Neurotol* 2010;31(1):105-110.
6. Vashishth A, Mathur NN, Choudhary SR, Bhardwaj A. Clinical advantages of cartilage palisades over temporalis fascia in type I tympanoplasty. *Auris Nasus Larynx* 2014;41(5):422-427.
7. Wullstein H. [Technic and early results of tympanoplasty]. *Monatsschr Ohrenheilkd Laryngorhinol* 1953;87(4):308-311.
8. Kyrodimos E, Stamatiou GA, Margaritis E, Kikidis D, Sismanis A. Cartilage tympanoplasty: a reliable technique for smokers. *Eur Arch Otorhinolaryngol* 2014;271(2):255-260.
9. Sapci T, Almac S, Usta C, Karavus A, Mercangoz E, Evcimik MF. [Comparison between tympanoplasties with cartilage-perichondrium composite graft and temporal fascia graft in terms of hearing levels and healing]. *Kulak Burun Bogaz Ihtis Derg* 2006;16(6):255-260.
10. Cavaliere M, Panetti M, Iemma M. Tragal cartilage shield tympanoplasty: our technique and results in 612 cases. *Acta Otolaryngol* 2014;134(9):890-897.
11. Garrido L, Cenjor C, Montoya J, et al. Diagnostic capacity of non-echo planar diffusion-weighted MRI in the detection of primary and recurrent cholesteatoma. *Acta Otorrinolaryngol Esp* 2015;66(4):199-204.
12. Khan MM, Parab SR. Average thickness of tragal cartilage for slicing techniques in tympanoplasty. *J Laryngol Otol* 2015;129(5):435-439.

# MASTOID OBLITERATION WITH HOMOLOGOUS BONE GRAFT

Anna Carolina de Oliveira Fonseca<sup>1</sup>, José Celso Rodrigues de Souza<sup>1</sup>, Eloisa Maria Mello Santiago Gebrim<sup>2</sup>, Luiz Augusto Ubirajara Santos<sup>3</sup>, Ricardo Ferreira Bento<sup>1</sup>

<sup>1</sup>Otolaryngology Department, University of Sao Paulo School of Medicine, São Paulo, SP, Brasil; <sup>2</sup>Radiology Department, University of Sao Paulo School of Medicine, São Paulo, SP, Brasil; <sup>3</sup>Tissue Bank, Institute of Orthopedics and Traumatology of University of Sao Paulo School of Medicine, São Paulo, SP, Brasil

**Conflicts of interest and source of funding:** The authors have no conflicts of interest to declare. This research has no financial support.

## 1. Introduction

Mastoid obliteration was introduced to eliminate canal-wall-down (CWD) mastoidectomy-related problems, and it is currently the treatment of choice for chronic discharging mastoid cavities.<sup>1,2</sup>

A variety of techniques have been reported using different materials to fill the cavity. Autologous materials, such as muscle, fat, cartilage, bone chips, bone pâté, and musculoperiosteal flaps, were amongst the first to be used as fillers for mastoid obliteration. Nonetheless, high levels of reabsorption, loss of volume, and limited availability encouraged the continuous search for better alternatives.<sup>3</sup>

While there is no definitive evidence showing one particular filler material is superior to the others,<sup>2</sup> the current costs of synthetic materials may limit their widespread use, especially in developing countries.

In this study, we revisit the use of homologous bone for controlling suppuration after revision surgery with mastoid obliteration for chronic otitis media (COM). We use a particulated frozen allograft bone (PFAB), a low-cost filler material obtained from a tissue bank. Banked bone represents an almost unlimited supply of reconstructive material, absence of donor site morbidity and decreased operating time.<sup>4</sup> The main argument for reconsidering allografts for mastoid obliteration is the rigorous donor and tissue screening protocols and processing programs that now guarantee the safety and effectiveness of human bone allografts.<sup>5,6</sup>

## 2. Materials and Methods

This study was a prospective interventional case series conducted in a tertiary referral hospital. The study population (ten patients) was selected from patients who had undergone CWD or canal-wall-up (CWU) mastoidectomy for COM with cholesteatoma, and had an indication for revision surgery.

Each procedure was performed according to the technique described by Silvola,<sup>7</sup> using a retro-auricular approach and general anesthesia. Obliteration of the open cavity was performed with PFAB obtained from a tissue bank according to the process described below. Each particulated bone was 0.5 to 0.9 mm in size.

Correspondence: Anna Carolina de Oliveira Fonseca, MD, Department of Ophthalmology and Otolaryngology, University of São Paulo, School of Medicine, Av. Dr. Enéas de Carvalho Aguiar, 255, sala 6167, CEP 05403-000, São Paulo, SP, Brasil.  
E-mail: anna.fonseca@hc.fm.usp.br

*Cholesteatoma and Ear Surgery – An Update 2017, pp. 99 -102*

*Edited by Matthew Yung*

*2017 © Kugler Publications, Amsterdam, The Netherlands*



Fig. 1. Mechanical processing is carried out with removal of the adventitious tissues such as blood, periosteum, subcutaneous tissue, muscles, fasciae, and fibrotic tissue.

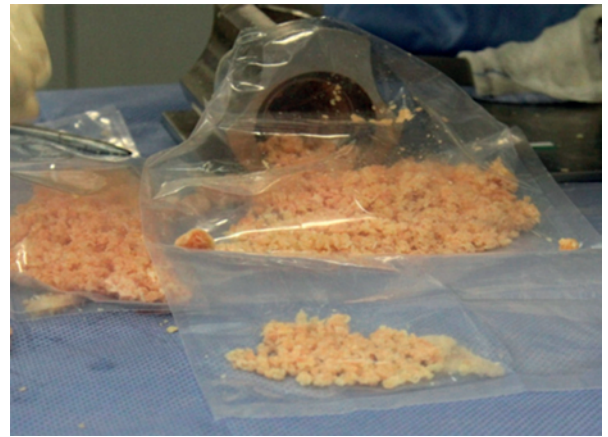


Fig. 2. To obtain the particulated bone, a special crushing machine is used.

At each follow-up visit, otomicroscopic examination was performed and control of suppuration was evaluated.

PFAB was provided by a Tissue Bank and processed according to Santos *et al.*<sup>8</sup> Figures 1, 2 and 3 show the methodology used for processing the musculoskeletal tissue. It must be stressed that the mechanical and chemical processing of the tissue removes all the organic matrix, leaving only inorganic matrix which does not cause immunogenic reaction.

Osteointegration of PFAB in the mastoid was assessed on CT according to the same parameters described by Franco Vidal *et al.*<sup>9</sup> CT images were obtained at six and 20 months postoperatively. Presence of recurrent or residual cholesteatoma was assessed clinically and on non-echo-planar imaging magnetic resonance imaging at one year postoperatively. Hearing was assessed preoperatively and at one year postoperatively according to pure-tone and speech audiometry and word recognition scores (WRS).



Fig. 3. The fragments are then submitted to chemical processing, where they are immersed in hydrogen peroxide-based emulsifying solutions and alcoholic solutions under ultrasound stirring.

### 3. Results

The patients included four men and six women with a mean age at surgery of 35.2 years. Mean follow-up was 30 months.

Seven patients achieved a dry ear at a mean of eight weeks postoperatively and remained dry during the follow-up period. Three patients developed bone graft exposure followed by infection and extrusion through the ear canal and required revision surgery to remove the obliteration material. All patients had undergone at least one previous mastoid surgery. Previous or current cholesteatoma was identified in all patients, and eight patients had a previous open cavity.

Mean bone density was 755.35 HU measured at the obliteration site at a mean of 31 months postoperatively. Percentage of mastoid volume obliterated was between 75% and 100% in six cases and between 50% and 75% in one case. In all seven patients, there was an increase in bone density postoperatively as shown in figure 4. One patient presented with recurrent cholesteatoma (0.5 cm) at one year postoperatively, but it was not in the obliteration area. No other cholesteatoma was identified in this series. At 12 months postoperatively, 80% of patients had preserved hearing.

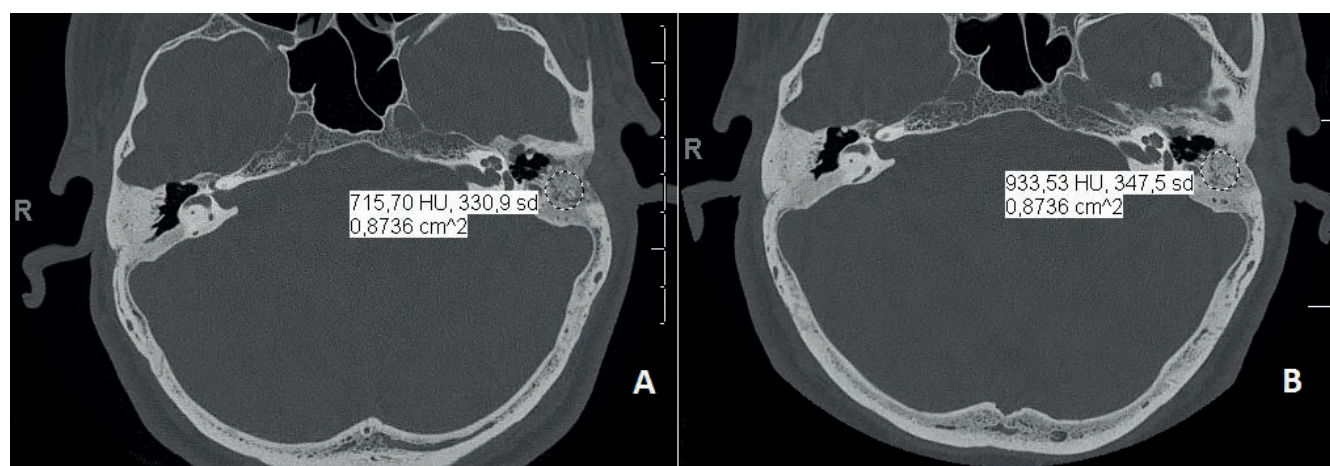


Fig. 4. Computed tomographic images at six (A) and 31 (B) months after obliteration surgery, showing an increase in bone graft density.

#### 4. Discussion

Over the past 30 years, some studies have described the use of homologous tissue to perform mastoid obliteration, specifically the use of cancellous bone chips from the iliac crest or knee cartilage.<sup>10</sup> However, despite the increase in bone transplantation in the last decade (specially in dentistry and orthopedic surgery), to our knowledge, there is no report on the use of homologous tissue from a bone bank to perform mastoid obliteration. This is the main breakthrough we provide in our study. In short, we argue that the concerns regarding infection and safety in the 1980s that led to the discontinuity of homograft techniques in mastoid obliteration have been addressed with rigorous donor and tissue screening protocols, and that graft material provided by a bone bank may be cost-effective, easy to obtain, and virtually unlimited for dealing with these open cavity problems.

A lower than ideal success rate was not due to the filler material employed, but to the failure in covering the material by the soft tissue flap that became necrotic or retracted, leading to the exposure of the bone graft. Improving the surgical technique, namely by ensuring that the filler material is not exposed, may prevent failures such as the ones we report in this study.

#### 5. Conclusion

This study shows that PFAB may be used to achieve a dry mastoid cavity with satisfactory osteointegration and density maintenance. PFAB is a safe material obtained from a certified bone bank and may be a more cost-effective filler compared to current synthetic materials, especially in developing countries. Further large multi-center studies may be important for confirming these findings.

#### References

1. Chhapola S, Matta I. Mastoid obliteration versus open cavity: a comparative study. *Indian J Otolaryngol Head Neck Surg* 2014;66 (Suppl 1):207-213. doi:10.1007/s12070-011-0429-x
2. Yung M, Bennett A. (2013) Use of mastoid obliteration techniques in cholesteatoma. *Curr Opin Otolaryngol Head Neck Surg* 2013;21(5):455-460. doi:10.1097/MOO.0b013e3283646521
3. Black B. Mastoidectomy elimination. *Laryngoscope* 1995;105(12 Pt 2 Suppl 76):1-30. doi:10.1288/00005537-199512000-00023
4. Hardin CK. Banked bone. *Otolaryngol Clin N Amer* 1994;27(5):911-925.
5. Boyce T, Edwards J, Scarborough N. Allograft bone. The influence of processing on safety and performance. *Orthopedic Clin N Amer* 1999;30(4):571-581.



6. Moucha CS, Renard RL, Gandhi A, Lin SS, Tuan RS. Bone Allograft Safety and Performance. In: Bronner F, Farach-Carson MC, Mikos AG (eds.), *Engineering of Functional Skeletal Tissues*, pp. 46-54. London: Springer 2007. doi:10.1007/978-1-84628-366-6\_3
7. Silvola JT. Mastoidectomy cavity obliteration with bioactive glass: a pilot study. *Otolaryngol Head Neck Surg* 2012;147(1):119-126. doi:10.1177/0194599812438168
8. Santos LAU, Croci AT, Armentano NR, et al. Cryopreserved musculoskeletal tissue bank in dentistry: state of the art and perspectives. In: Katkov II (ed.), *Current Frontiers in Cryopreservation*, pp. 37-68. Rijeka: InTech 2012.
9. Franco-Vidal V, Daculsi G, Bagot d'Arc M, et al. Tolerance and osteointegration of TricOs/MBCP(R) in association with fibrin sealant in mastoid obliteration after canal wall-down technique for cholesteatoma. *Acta Oto Laryngol* 2014. doi:10.3109/00016489.2013.859394
10. Wehrs R. Reconstructive mastoidectomy with homograft knee cartilage. *Laryngoscope* 1972;82(7):1177-1188. doi:10.1288/00005537-197207000-00006

# CADAVER DISSECTION AS A TEACHING TOOL IN EAR SURGERY

V. Franco-Vidal

*ENT and Skull Base Surgery Department, Bordeaux University, France*

Ear surgical techniques require progressive training. Cadaveric temporal bone drilling practice constitutes an essential stage in training for the surgical approach to these complex anatomic structures.

The resident in training must master the use of the surgical microscope, the burr, and fine drilling instruments used in otological dissection.

Training in otology is different from the Halstedian model, which is available in traditional open surgery because of the presence of the microscope. The senior does not have the vision of the reliefs nor the palpation feeling when observing in the lateral optics. Moreover, it is impossible for the senior to intervene or correct the movement of the student quickly because of the size of the ear and the presence of the microscope. For that reason practice on cadaver is safer.

This kind of practice is also necessary to learn anatomy of the temporal bone in surgical position, which is different from the imaging and the classical anatomical representation. It allows learning which anatomical areas can be accessed and which surgical procedure to use to reach them. It is also a good way to learn the different regions of the petrous bone, the position from one to each other, and to understand how to reach them.<sup>1,2</sup>

Since a few years, due to economic reasons, the duration of operations has to be more and more limited, and time spent for teaching in the operating room is dramatically reduced. Cadaveric temporal bone dissection is a good alternative teaching method.

Learning from its mistakes is necessary in surgical practice and it is of course safer on cadaveric specimens than on living beings. Finally, it is a safe way to develop self-confidence.

The pedagogic interest of this kind of teaching has been largely demonstrated, and is an additional tool, with virtual surgery and simulators increasing surgical practice acquisitions safely.<sup>3,4</sup>

## References

1. Naik SM, Naik MS, Bains NK. Cadaveric temporal bone dissection: is it obsolete today? *Int Arch Otorhinolaryngol* 2014;18(1):63-67.
2. Mowry SE, Hansen MR. Resident participation in cadaveric temporal bone dissection correlates with improved performance on a standardized skill assessment instrument. *Otol Neurotol* 2014;35(1):77-83.
3. Fennessy BG, O'Sullivan P. Establishing a temporal bone laboratory: considerations for ENT specialist training. *Ir J Med Sci* 2009;178(4):393-395.
4. Awad Z, Tornari C, Ahmed S, Tolley NS. Construct validity of cadaveric temporal bones for training and assessment in mastoidectomy. *Laryngoscope* 2015;125(10):2376-2381.

Correspondence: Pr Valérie Franco-Vidal, ENT and Skull Base Surgery Department, PELLEGRIN - Bordeaux University Hospital, Place Amelie Raba Leon, 33076 BORDEAUX CEDEX, France.  
E-mail: Valerie.vidal@chu-bordeaux.fr

*Cholesteatoma and Ear Surgery – An Update 2017, pp. 103 -104*

*Edited by Matthew Yung*

*2017 © Kugler Publications, Amsterdam, The Netherlands*





# TEN-YEAR OUTCOMES WITH THE SHAPE MEMORY NITINOL STAPES PROSTHESIS

Rebecca L. Heywood<sup>1,2</sup>, Mark E. Quick<sup>3</sup>, Marcus D. Atlas<sup>2,3</sup>

<sup>1</sup>*Ng Teng Fong General Hospital, Singapore;* <sup>2</sup>*Ear Science Institute Australia and Ear Sciences Centre, The University of Western Australia;* <sup>3</sup>*Department of Otolaryngology-Head & Neck Surgery, Sir Charles Gairdner Hospital, Perth, WA, Australia*

## 1. Introduction

Self-crimping pistons were introduced to remove the manual component of the crimping process during stapedectomy. Stapes prostheses made of the shape memory alloy, Nitinol, return to an original pre-set shape upon the application of heat above 45 degrees.<sup>1</sup> This produces a closed loop which theoretically maintains a closed shape in uniform contact around the incus.<sup>1</sup> Results from the senior author's previous publication demonstrated significantly reduced mean postoperative air bone gap (ABG) and inter-individual variation of the postoperative ABG using a Nitinol prosthesis as compared to a conventional titanium prosthesis and stable results up to two years postoperatively.<sup>2,3</sup> Other groups have found stable early and intermediate term hearing results equivalent to or better than those achieved using conventional prostheses.<sup>4-12</sup> In the long term, reports of stapes surgery using conventional prostheses demonstrate an average deterioration of 0.4-1.1 dB/year in air conduction (AC) thresholds.<sup>13-16</sup> The objective of this study was to assess the long-term clinical hearing outcomes and their stability following stapedectomy using a self-crimping shape memory prosthesis over a ten-year period.

## 2. Materials and methods

### 2.1. Study design and patient selection

Retrospective case note review was performed of 13 patients who underwent 14 stapedectomy procedures using the SMart shape memory prosthesis (Olympus America Inc., Center Valley, PA, USA) by the senior author (MA) between November 2003 and February 2005. There were seven male and six female patients. The mean age at surgery was 48 years (range 26-79). The procedures were performed on eight (57%) right ears and five (43%) left ears. All the patients had a minimum of ten years follow-up. One patient had bilateral stapedectomy procedures. One case was a revision procedure, referred from another institution after failed stapedectomy.

### 2.2. Surgical technique

A standardized approach to stapedectomy was performed under assisted local anaesthetic as described in our previous publications. Piston length was measured as the total length of the prosthesis, that is, from the end of the fluoroplastic shaft to the top of the Nitinol hook.

### 2.3. Audiometric assessment

Pure-tone audiometry displaying AC (125-8000 Hz) and bone conduction (BC) (250-4000 Hz) thresholds was performed preoperatively, at three monthly intervals up to two years and at five and ten years postoperatively.

Correspondence: Rebecca L Heywood, Suite 3, Ground Floor, 1 Salvado Road, Subiaco, WA 6008, Australia.  
E-mail: rebecca\_heywood@yahoo.com

*Cholesteatoma and Ear Surgery – An Update 2017, pp. 105 -108*

*Edited by Matthew Yung*

*2017 © Kugler Publications, Amsterdam, The Netherlands*

The ABG, ABG closure (ABGC) and change in high tone BC level were calculated as per the Committee on Hearing and Equilibrium guidelines.<sup>17</sup> Some thresholds at 3kHz were interpolated by averaging the thresholds at 2 and 4 kHz.

### 3. Results

The mean pre- and postoperative AC, BC, ABG (0.5, 1, 2 and 3kHz), ABGC and change in high tone BC level (1, 2 and 4 kHz) are shown in Table 1. The mean ABG at each frequency and time interval is demonstrated in Figure 1. Statistical analysis was not performed due to the small number of patients.

The ABG was  $\leq 10$  dB in 100% of patients at one year postoperatively and 93% of patients ten years postoperatively (Table 2).

Median piston length was 5.25 mm (range 4.5-5.75 mm).

One of the procedures was a revision case who developed hearing loss eight years after her initial stapedectomy at another institution. At surgery the prosthesis was found to have extruded from the footplate and dislodged from the long process of incus (LPI). A new stapedotomy was performed and a Nitinol piston sited.

Table 1. Audiometric outcomes at one and ten years.

		AC (0.5,1,2,3kHz)			ABG (0.5,1,2,3kHz)			ABG closure			Change in high tone BC level (1,2,4kHz)			BC (0.5,1,2,3kHz)		
	n	Mean	SD	Range	Mean	SD	Range	Mean	SD	Range	Mean	SD	Range	Mean	SD	Range
Preoperative	14	52.9	9.2	40 - 68	29	11.5	16 to 48	na	Na	na	na			23.9	11.5	10 to 51
1 year postop	14	24.4	8.3	11 to 43	5.5	3	0 to 10	23.3	12.6	11 to 47.5	5.4	6	15 to -2	18.6	8	10 to 40
10 yrs postop	14	29.6	11.2	14 to 61	4.8	3.9	0 to 15	24.2	9.9	11.3 to 43.5	-0.2	7	15 to -8	25	12	11 to 56

AC = air conduction; ABG = air bone gap; BC = bone conduction; SD = standard deviation.

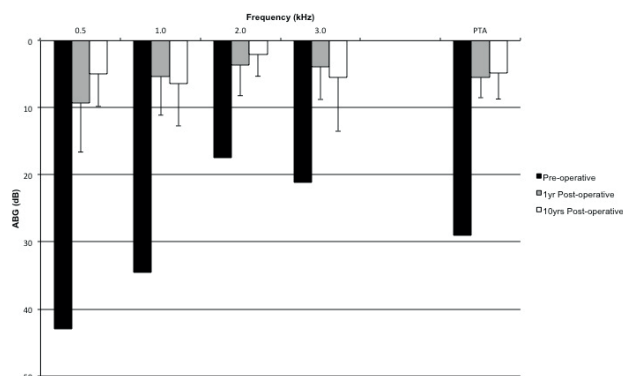


Fig 1. Air bone gap (ABG) by frequency over time. PTA = pure tone average.

Table 2. Number of cases in each air bone gap (ABG) category.

ABG (dB)	One year	Long-term
	n (%)	n (%)
$\leq 10$	14 (100%)	13 (93%)
11 - 20	0	1 (7%)
21 - 30	0	0
$\geq 31$	0	0

### 4. Discussion

The introduction of the Nitinol shape memory prosthesis has enabled better and more reproducible circumferential approximation of the piston loop to the LPI. Early postoperative results from the senior author's series indicated a significant reduction in the mean postoperative ABG in 16 patients with the shape memory prosthesis as compared

to a matched control group of 48 patients with a conventional manually crimped titanium piston (6.28 dB vs 14.13 dB,  $p = 0.03$ ).<sup>2</sup> The mean postoperative ABG remained stable in both groups up to two years postoperatively (5.15 dB vs 12.37 dB,  $p = 0.05$ ).<sup>3</sup> The inter-individual variation in the postoperative ABG was also greatly reduced in the shape memory prosthesis group in the early (2.89 vs 12.63 dB,  $p = 0.01$ ) and medium term (4.45 vs 11.23 dB,  $p = 0.01$ ), suggesting enhanced reproducibility of a firm incus-piston interface with the self-crimping prosthesis. Results from other institutions indicate early hearing outcomes comparable to<sup>5-7,9</sup> or better than<sup>4,10</sup> those acquired using conventional prostheses, with a mean postoperative ABG of between 4 and 8 dB. The ABG remained stable in the intermediate term in the small number of studies published.<sup>6,8,11</sup>

There have been concerns that closer circumferential approximation of the Nitinol hook to the LPI could lead to erosion through pressure necrosis, heat trauma during activation of the self-crimp mechanism or chemical inflammation.<sup>4,6,9,18</sup> Ying *et al.*<sup>19</sup> performed revision surgery on 21 of 190 patients (11%) following initial stapedectomy using a shape memory prosthesis. The most common causes of revision surgery were displacement of the prosthesis from the fenestra (12/21 cases) and lateral displacement of the prosthesis off the incus (13/21 cases). There was notching of the incus in three patients, but no reported necrosis of the LPI.

This study of outcome of stapedectomy using a self-crimping Nitinol shape memory prosthesis is small and precluded statistical analysis of the results. Nevertheless, it is the first long-term report to our knowledge and the results are therefore important. Excellent closure of the ABG is evident and it can be seen to remain stable up to ten years postoperatively. There was a recurrent conductive hearing loss in the patient who had a revision procedure; ABG increased from 4 dB at one year to 15 dB at ten years. The patient did not want to have further intervention to explore the reason behind this.

## 5. Conclusion

This study reports the long-term hearing results achieved with a self-crimping shape memory Nitinol prosthesis for the first time. Although the patient group is small, it is evident that excellent closure of the ABG is achieved and that it remains stable over at least ten years. There is no evidence that circumferential firm fixation of the hook around the LPI has a detrimental effect in the long term.

## References

1. Knox GW, Reitan H. Shape-memory stapes prosthesis for otosclerosis surgery. *Laryngoscope* 2005;115:1340-1346.
2. Rajan GP, Atlas MD, Subramaniam K, Eikelboom RH. Eliminating the limitations of manual crimping in stapes surgery? A preliminary trial with the shape memory Nitinol stapes piston. *Laryngoscope* 2005;115:366-369.
3. Rajan GP, Diaz J, Blackham R, et al. Eliminating the limitations of manual crimping in stapes surgery: Mid-term results of 90 patients in the Nitinol stapes piston multicenter trial. *Laryngoscope* 2007;117:1236-1239.
4. Huber AM, Veraguth D, Schmid S, Roth T, Eiber A. Tight stapes prosthesis fixation leads to better functional results in otosclerosis surgery. *Otol Neurotol* 2008;29:893-899.
5. Fayad JN, Semaan MT, Meier JC, House JW. Hearing results using the SMart piston prosthesis. *Otol Neurotol* 2009;30:1122-1127.
6. Sorom AJ, Driscoll CLW, Beatty CW, Lundy L. Retrospective analysis of outcomes after stapedotomy with implantation of a self-crimping Nitinol stapes prosthesis. *Otolaryngol Head Neck Surg* 2007;137:65-69.
7. Brown KD, Gantz BJ. Hearing results after stapedotomy with a Nitinol piston prosthesis. *Arch Otolaryngol Head Neck Surg* 2007;133:758-762.
8. Lavy J, Khalil S. Five year hearing results with the shape memory Nitinol stapes prosthesis. *Laryngoscope* 2014;124:2591-2593.
9. Harris JP, Gong S. Comparison of hearing results of Nitinol SMART stapes piston prosthesis with conventional piston prostheses: postoperative results of Nitinol stapes prosthesis. *Otol Neurotol* 2007;28:692-695.

10. Tenney J, Arriaga MA, Chen DA, Arriaga R. Enhanced hearing in heat-activated-crimping prosthesis stapedectomy. *Otolaryngol Head Neck Surg* 2008;138:513-517.
11. Gerlinger I, Bakó P, Piski Z, et al. KTP laser stapedotomy with a self-crimping, thermal shape memory Nitinol piston: follow-up study reporting intermediate-term hearing. *Eur Arch Otorhinolaryngol* 2014;271:3171-3177.
12. Pudel EI, Briggs RJS. Laser-assisted stapedotomy with a Nitinol heat-crimping prosthesis: Outcomes compared with a platinum fluoroplastic prosthesis. *Otolaryngol Head Neck Surg* 2008;139:51-54.
13. Aarnisalo AA, Vasama JP, Hopsu E, Ramsay H. Long-term hearing results after stapes surgery: a 20-year follow-up. *Otol Neurotol* 2003;24:567-571.
14. Langman AW, Jackler RK, Sooy FA. Stapedectomy: Long-term hearing results. *Laryngoscope* 1991;101:810-814.
15. Vincent R, Sperling NM, Oates J, Jindal M. Surgical findings and long-term hearing results in 3050 stapedotomies for primary otosclerosis: A prospective study with the otology-neurotology database. *Otol Neurotol* 2006;27:S25-S47.
16. Birch L, Elbrond O, Pedersen U. Hearing improvement after stapedectomy: up to 19 years' follow-up period. *J Laryngol Otol* 1986;100:1-7.
17. Committee on Hearing and Equilibrium guidelines for the evaluation of results of treatment of conductive hearing loss. *Otolaryngol Head Neck Surg* 1995;113:186-187.
18. Kasano F, Morimitsu T. Utilization of nickel-titanium shape memory alloy for stapes prosthesis. *Auris Nasus Larynx* 1997;24:137-142.
19. Ying YLM, Hillman TA, Chen DA. Patterns of failure in heat-activated crimping prosthesis in stapedotomy. *Otol Neurotol* 2010;32:21-28.

# REMOVAL OF CHOLESTEATOMA MATRIX FROM INNER EAR FISTULA

Harukazu Hiraumi

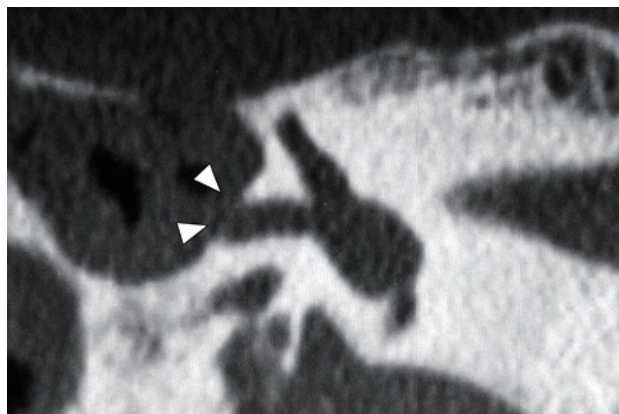
*Iwate Medical University, Japan*

## 1. Introduction

Removal of a cholesteatoma matrix from the inner ear fistula is a clinical challenge. Inner ear fistulae are usually classified according to the Dornhoffer and Milewski classification.<sup>1</sup> In this classification, type I is an erosion of the bony labyrinth with an intact endosteum. Type II is a fistula with an open perilymphatic space. A type-III fistula is defined as an open perilymphatic space with involvement of the membranous labyrinth. A problem of this classification is, that the type may change according to the surgical procedure, especially in cases with large fistulae. An endosteum of a type-I fistula can be damaged surgically and the fistula may be judged as type II. We preserve the endosteum by using a small knife in elevating the cholesteatoma matrix. This technique is important, especially in cases with cochlear fistulae.

## 2. Surgical technique

The cholesteatoma matrix over the fistula is removed separately from those in the other area. A cleavage plane is created between the cholesteatoma matrix and the periosteum of the temporal bone. It is very important to avoid exposing the cortical bone. The periosteal layer provides us with a smooth and continuous cleavage plane through the fistula. By preserving the periosteum, the matrix is easily elevated and the endosteum at the inner ear fistula is preserved. A small knife (Sato corneal knife or Beaver needle blade) is used in making a cleavage plane and in elevating the cholesteatoma matrix. In cases of cochlear fistulae, the cleavage plane is created between the matrix and the perimatrix, so as not to cause accidental rupture of the endosteum.



*Fig. 1.* The coronal CT scan clearly showed the inner ear fistula in the lateral semicircular canal (arrow head).

## 3. Clinical cases

### 3.1. Case 1

A 71-year-old male presented with recurrent episodes of right otorrhea for several years. He had been suffering from right hearing loss for several decades. Recently, he noticed dizziness when he touched the ear. The otoscopic examination revealed a bone defect in the attic and a polyp formation in the pars flaccida. The preoperative CT scan revealed that he had a large fistula in the lateral semicircular canal (Fig. 1). He underwent tympanoplasty with

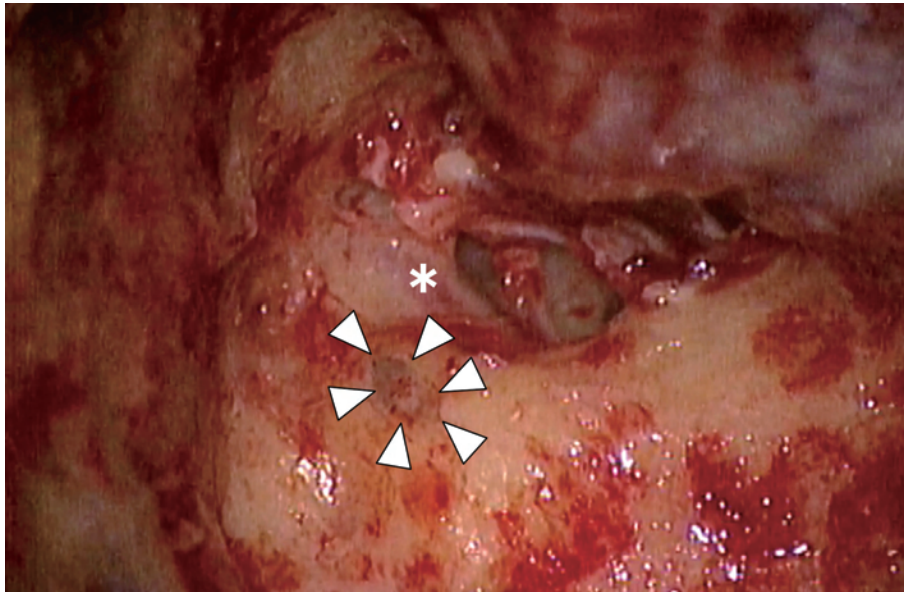
Correspondence: Harukazu Hiraumi M.D., Ph.D., Department of Otolaryngology-Head and Neck Surgery, Iwate Medical University, School of Medicine, 19-1, Uchimarui, Morioka, Iwate, 020-8505, Japan.  
E-mail: hhiraumi@iwate-med.ac.jp

*Cholesteatoma and Ear Surgery – An Update 2017, pp. 109 -112*

*Edited by Matthew Yung*

*2017 © Kugler Publications, Amsterdam, The Netherlands*





*Fig. 2.* The cholesteatoma matrix was totally removed. The endosteum of the lateral semicircular canal fistula (arrow head) was totally preserved. See that the periosteum around the fistula was also preserved. \*: tympanic portion of the facial nerve

canal-wall reconstruction technique. The cholesteatoma matrix was totally removed except for the part covering the lateral semicircular canal fistula. The periosteum around the fistula was carefully preserved, and a cleavage plane was made between the cholesteatoma matrix and the periosteum. Only the matrix was sharply dissected from the periosteum with a Sato corneal knife. Finally, the cholesteatoma matrix was totally removed without opening the perilymphatic space (Fig. 2). The fistula was 2.5 mm in length. The postoperative course was uneventful, and the hearing threshold was preserved after the surgery.

## 2.2. Case 2

An 81-year-old female presented with persisting right otorrhea and otalgia for several weeks. She underwent tympanoplasty several years ago, and did not receive regular follow-up after the surgery. The otoscopic examination revealed that the mastoid cavity was full of infected debris. The ear drum adhered to the promontory. Careful manipulation of the eardrum caused mild dizziness. The CT scan showed that she had a fistula in the cochlea (Fig. 3). Even after the conservative treatment, the infection was not controlled. She needed to wear a hearing aid on her right ear, but the hearing aid worsened the infection. She was subjected to tympanoplasty with canal-wall reconstruction technique. The cholesteatoma matrix in the attic and mastoid was totally removed. With a Beaver needle blade, the cholesteatoma matrix covering the cochlear fistula was sharply dissected. Meticulous care was taken not to expose the lumen of the cochlea. To accomplish this, a cleavage plane was made between the matrix and the perimatrix (Fig. 4). The postoperative course was uneventful and the average bone conduction level improved from 68.3 dBHL to 58.3 dBHL.

## 3. Discussion

How to manage the inner ear fistula is still controversial. In cases with a small fistula in the semicircular canal, the bone conduction hearing level does not change in most patients.<sup>2</sup> In cases with a large fistula or a fistula in the cochlea, however, the postoperative profound hearing loss is frequent. Modified radical mastoidectomy can be used instead of total removal of the cholesteatoma. This technique is safe and useful in most cases; nevertheless, the fistula symptoms and persistent otorrhea can be problematic after surgery, especially in cases with need of hearing aids. Recent development in surgical technique promotes most surgeons to remove the cholesteatoma matrix from the inner ear fistula, and encouraging results have been reported.<sup>3</sup> Even in that case, the precise technique about

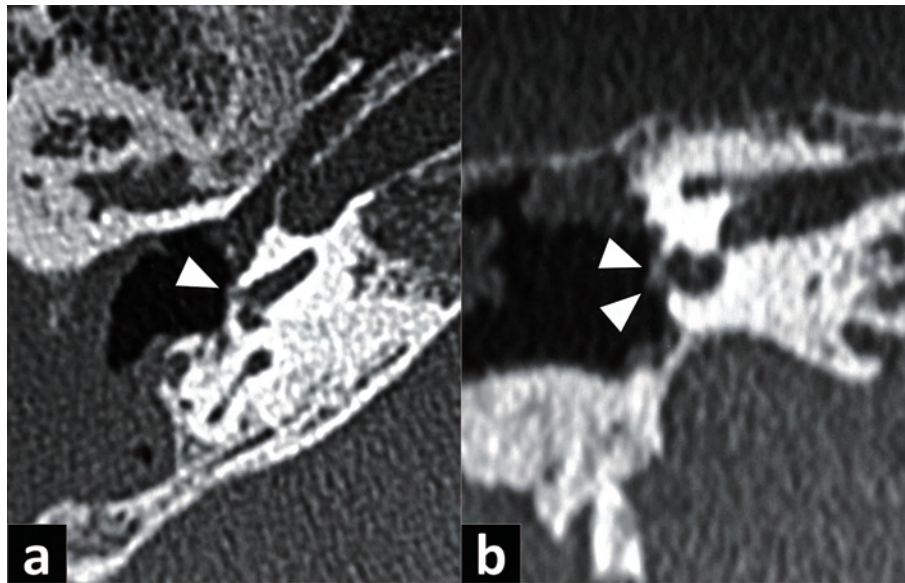


Fig. 3. The axial (a) and the coronal (b) CT scan clearly showed the fistula in the cochlea (arrow head).

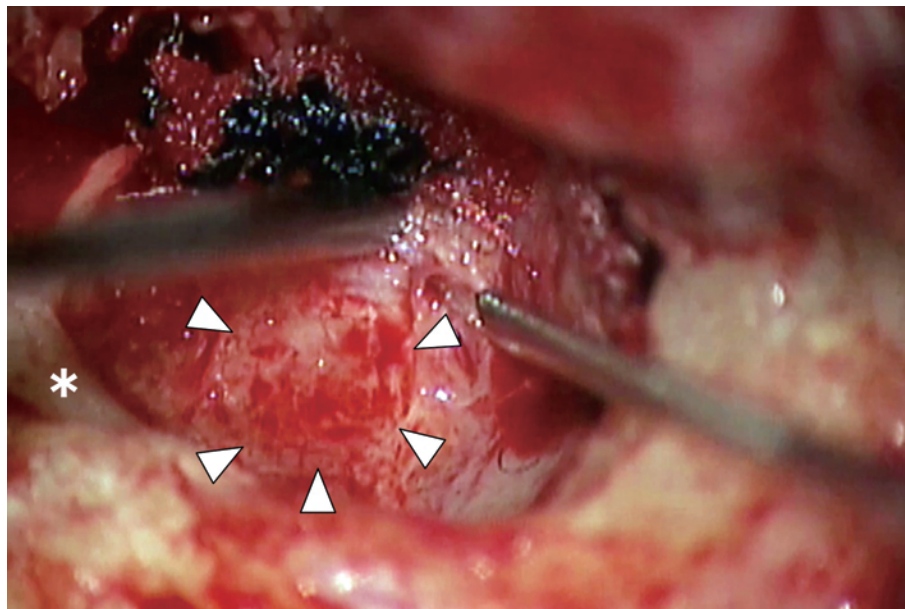


Fig. 4. The cholesteatoma matrix was elevated from the promontory. The cleavage plane was created between the cholesteatoma matrix and the perimatrix, and thus the perilymphatic space was kept unopened (arrow head). \*: tympanic portion of the facial nerve

how to remove the cholesteatoma matrix from the inner ear fistula is barely mentioned. In the eradication of the cholesteatoma, the matrix is usually elevated with all the soft tissue behind it. With this technique, however, the endosteum is often damaged because the cortical bone and the endosteum belong to different layers. By following the cortical bone, the cleavage plane encounters a gap between the cortical bone and the endosteum at the edge of the fistula, resulting in the opening of the perilymphatic space. We make a cleavage plane between the periosteum and the perimatrix, or between the perimatrix and the matrix of a cholesteatoma. By following this plane, we can elevate the cholesteatoma matrix without encountering any gaps at the edge of the fistula. Some soft tissues are left over the fistula, but the risk of residual cholesteatoma is low.<sup>4</sup> This technique is especially important in cases with a cochlear fistula, because the opening of the cochlear lumen usually lead to total loss of hearing.<sup>5</sup> In cases with cochlear fistula and residual hearing, the popular surgical procedure is modified radical mastoidectomy with preservation of cholesteatoma matrix above the fistula. With this kind of surgery, however, the patient cannot wear a hearing aid on the affected side because of a persistent dizziness and otorrhea. Our present technique is highly recommended for such patients. A drawback of our technique is that this technique can be very challenging in

cases with a very thin matrix. Except for such rare cases, our present technique is worth trying in the eradication of cholesteatoma matrix from the inner ear fistula.

## References

1. Dornhoffer JL, Milewski C. Management of the open labyrinth. *Otolaryngol Head Neck Surg* 1995;112(3):410-414.
2. Yamamoto N, Fujimura S, Ogino E, et al. Management of the labyrinth fistula in Kyoto University Hospital. *Acta Otolaryngol* 2010;130:16-19.
3. Carlson ML, Latuska RF, Pelosi S, et al. Evolving considerations in the surgical management of cholesteatoma in the only hearing ear. *Otol Neurotol* 2014;35(1):84-90.
4. Hiraumi H, Kanemaru SI, Miura M, et al. Histopathological evaluation and long-term results of soft tissue preservation technique in cholesteatoma surgery. *Eur Arch Otorhinolaryngol* 2016 Oct 3. DOI: 10.1007/s00405-016-4328-3.
5. Chao YH, Yun SH, Shin JO, Yoon JY, Lee DM. Cochlear fistula in chronic otitis media with cholesteatoma. *Am J Otol* 1996;17(1):15-18.

# WHICH DEVICE – WHEN AND WHY? THE CONTROVERSIAL ROLE OF BONE CONDUCTION HEARING DEVICES IN THE REHABILITATION OF UNILATERAL SENSORINEURAL HEARING LOSS

W. Hodgetts<sup>1</sup>, D.P. Morris<sup>2</sup>, J. Ray<sup>3</sup>, M.K.S. Hol<sup>4</sup>

<sup>1</sup>*Institute for Reconstructive Sciences in Medicine (iRSM), Edmonton, Alberta, Canada;* <sup>2</sup>*Dalhousie University, Halifax, Nova Scotia, Canada;* <sup>3</sup>*Sheffield Teaching Hospitals & Sheffield Children's Hospital, England, UK;* <sup>4</sup>*Radboud University Medical Centre, Nijmegen, The Netherlands*

## Abstract

This is a summarized transcript of a lively, one-hour round-table session which took place at CHOLE 2016 held on June 8th 2016 in Edinburgh, Scotland. The moderator was invited to convene a panel of colleagues from experienced auditory implant programs. The panel was instructed to share their experience with a range of bone conduction hearing devices now used to rehabilitate patients with unilateral sensorineural hearing loss often referred to simply as single sided deafness or SSD.

The panelists were selected for their experience with particular devices or for their expertise in audiometric assessment. After a brief introduction, invited panelists offered their views on a number of contentious topics in order to see how much consensus, common ground or controversy existed between the different programs and the different devices under consideration.

This proceedings document represents a combination of what is known in the literature and a summary of our personal opinions, based upon years of combined experience working with this diverse group of patients.

Panelists were asked to consider the following key areas as a guide to our discussions:

### *Selection criteria*

Is there an age limit to consider at presentation, and if so, how relevant is the state of contralateral cochlea? Pre-operative trials – short and in-office or a more prolonged, pre-directed home trial? Is there a place for headband testing with some other surrogate device for the transcutaneous implant candidates?

### *Ease of surgical placement*

Have the panel experienced any notable and / or avoidable complications?

### *Device tolerance*

Are the devices practical to wear day to day?

### *Post-operative limitations*

How relevant are imaging restrictions and removability?

Correspondence: Prof. Bill Hodgetts, Program Director, Bone Conduction Amplification, Institute for Reconstructive Sciences in Medicine (iRSM), Edmonton, Alberta, Canada.  
E-mail: bill.hodgetts@ualberta.ca.

*Cholesteatoma and Ear Surgery – An Update 2017, pp. 113 -120*

*Edited by Matthew Yung*

*2017 © Kugler Publications, Amsterdam, The Netherlands*



*Costs*

Are there any major cost differences between the devices and the resources needed to implant them?

*Performance and benefit*

How do we begin to determine patient benefit let alone compare the performance of different devices?

*Best of breed – one vote – which device and why?*

Each of the three invited surgeons was permitted a limited number of slides in which to convey their thoughts on these questions. The session closed with a thoughtful and cautionary, audiological and philosophical consideration of the challenges faced when we attempt to compare the performance of different bone conduction hearing devices.

## 1. General introduction to the session

In our discussions regarding single-sided deafness (SSD) we will limit our considerations to unilateral sensorineural hearing loss (USHL). This single diagnosis covers a highly heterogeneous population. Not only are there diverse diagnoses including those arising as a consequence of chronic infection, ototoxicity, surgical interventions and a large idiopathic group, the population also contains diversity with regard to the onset of deafness, be it sudden or progressive and in consequence the duration for which the loss has been present when rehabilitation is first proposed.

Whatever the cause, whenever the onset and no matter how long the duration, to some extent, many with SSD will share the same triad of challenges. Hearing in background noise requires increased effort, directional hearing is impaired and listening to a speaker seated on the deafened side is difficult.

All bone conduction devices now used to rehabilitate SSD share the same common ground. They are all placed ipsilateral to the SSD. In simple terms, sound vibrations cross the skull to the contra-lateral ‘better-hearing’ cochlea. Performance is dependent on how well sound crosses the skull, the power of the device and the quality of remaining cochlear function as indicated by the bone curve.

We acknowledge that there is a price to be paid in crossing the skull which varies between individuals but is most noticeable in the transmission of higher frequencies. We also accept that with age our cochlear reserve diminishes with each decade of life, usually with the higher frequencies affected first. When these two observations are considered together, there are more than theoretical reasons why bone conduction as a life-long means of rehabilitating hearing loss might prove to be problematic as the years pass by. Are we truly serving our patients well by offering bone conduction hearing devices for the patients with SSD?

There is an increasing number of devices on the market. Devices are broadly classified as percutaneous with a skin-penetrating abutment or transcutaneous where and implanted device is connected to an external component through intact skin. The latter group may be passive with an external driver or may actively drive the bone from within.

There are a number of stakeholders involved when it comes to making a decision regarding which device to choose. Primary care physicians, audiologists, nurses, other patients (peers) and otolaryngologists will have their own opinions, attitudes and experience while industry partners compete to differentiate the often nuanced virtues of their particular product.

Do such diverse and potentially conflicting messages leave the patient spoilt for choice or just simply more confused than ever?

If these opinions are in conflict, how can we decide upon the best preoperative tests to aid our choice and ultimately allow a reliable comparison of device performance once fitted?

## 1. Introduction

Since 1977, titanium temporal bone-anchored hearing implants (BAHIs) have been used for hearing rehabilitation by means of bone conduction hearing. The indications for their use have been established for a variety of unilateral and bilateral types of hearing loss, including acquired and congenital conductive hearing loss, mixed hearing loss, and profound unilateral sensorineural hearing loss. The latter is also known as single-sided deafness (SSD). Strictly this is defined as sensorineural hearing loss in one ear, with (near) normal contralateral hearing function. Typically, patients with SSD have sufficient hearing for communication in quiet environments, but they experience difficulties with specific listening situations and directional hearing when the sound source is positioned on the impaired side and speech intelligibility in noise.<sup>1,2</sup>

In the past, the audiological rehabilitation of individuals with SSD was limited to the use of conventional air-conduction contralateral routing of offside signal (CROS) hearing aids.<sup>3,4</sup> Over the years, conventional CROS devices have been improved, and the treatment options for patients with SSD have expanded. Not only due to the introduction of a bone conduction device attached to an osseointegrated implant, working as a transcranial CROS device, but also cochlear implantation has been recommended in the recent years. Long-term follow-up, however, shows around 17% of discontinuation.<sup>5</sup> Is this related to age, gender, state of the contralateral ear? Studies so far have not been able to show a clear answer to these questions. In addition, the effectiveness of such a transcranial CROS device might be difficult to assess because the perception of any type of disability might vary widely among patients.<sup>6</sup> The perceived communication and psychosocial disabilities cannot be easily accessed from an audiogram alone. These audiological objective outcomes are of great importance in evaluating whether or not an intervention is successful from a technical point of view, however, the ability to hear pure tones in quiet or speech in noise seldom reflects the overall impact of that hearing loss on the life of a patient, nor does it act as a comprehensive measure of the therapeutic effect of any intervention to rehabilitate their hearing loss. Disability- and handicap-specific instruments, which are specific enough to capture the effect of hearing loss on quality of life, might be helpful in assessing the degree of disability and the benefits of rehabilitating SSD using any type of hearing device. Distinct outcomes for assessing these perceived benefits in SSD patients are not well defined. Next, they are often clinician-centered, measuring aspects that are deemed important primarily to healthcare professionals, instead of patients' well-being. It should be noted that patient-centered outcomes are distinct from patient-reported outcome measures; these are outcome measures scored by patients such as questionnaires, which may not necessarily be asking for information important from the patients' perspective (patient-centered).

In order to create realistic expectations, in SSD patients, a one to two-week trial of a headband version of the bone conduction device is recommended before the intervention.<sup>7</sup> It is important to realize this device should be powerful enough to overcome attenuation from the band and the skin and should be set to have more high frequency audibility to compensate for this.<sup>8</sup> To guide patients in this decision-making process, the clinicians nowadays are obliged to be able to communicate effectively, be aware of all available options in relation to cost-benefit and each draw-backs and merits and be able to judge the impact of these interventions on the lives of our patients.

Available options (based upon Figure 1) for patients with SSD will be described in random order, to help clinicians in this decision making process. Of course, the patients need to have had a trial period with a conventional CROS device (conservative treatment) on beforehand. Next, suggestions how to judge the patient and the impact of a certain intervention on a patients' life will be shared with the readers.

### 1.1. Percutaneous BAHA

#### *Selection criteria*

In case of a congenital SSD with (near) normal hearing in the contralateral ear a bone conduction device can be fitted on a softband from the age of six months. There is no upper age limit. In children it is recommended to closely



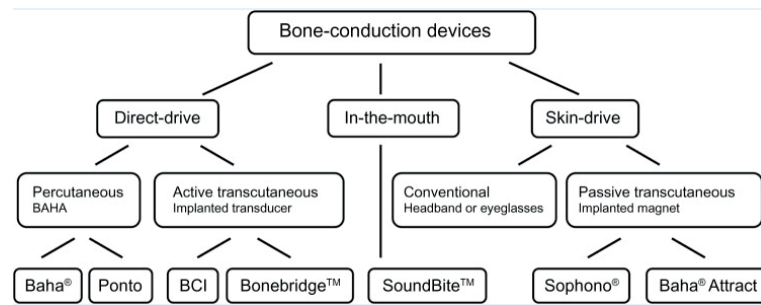


Fig. 1. Available options in bone conduction hearing anno 2005  
(From: see Ref. 9.)

follow-up on patients with unilateral hearing loss and provide conservative treatment options like preferential seating. One challenge to be aware of in children is their ability to adjust the device according to the environment is limited compared to adults. Adults may end up in a noisy environment and determine that the device is making hearing more difficult and may choose to reduce the volume or turn it off. If problems arise, these can be relatively small and sometimes difficult to detect, a trial with a softband for several weeks is recommended and frequent follow-up with the family is strongly encouraged.

#### *Ease of surgical placement*

Bone-anchored hearing implant surgery is meticulous but simple, safe and straightforward. The recommended surgical technique to be used nowadays is the Nijmegen linear incision with tissue preservation.<sup>10-12</sup> In adults, local anesthetics are most often used and the results are in general esthetically nice. Children remain more challenging since higher implant losses and more skin reactions have been reported in this specific group. It is advised to consider referral to specialized centers especially in case of concomitant comorbidities. The current generation implants are safe and stable over time. After three years of follow-up, a 4% implant loss and 2% adverse skin reactions (*i.e.*, Holgers grade  $\geq 2$ ) have been reported.<sup>13</sup>

#### *Device tolerance*

Daily use rates in hours is very high for these specific type of devices as  $\geq 14$  hours/day are reported. The devices can be used for six to eight years in general. The devices are easy to handle in children and adults, including the elderly people. Sometimes, battery changing is experienced as difficult. On the other hand, the digital devices are extremely easy to use with apps, streamers, etc. Postoperative care of the implant site has to be strict and meticulous.

#### *Postoperative limitations*

There are no imaging restrictions in the postoperative phase, as the implant is MRI conditional for three Tesla field strength. The implant can be placed in bone as thin as one mm, however, it is recommend to place an implant from four years of age in order to have generally more bone. The softband alternative is sufficient and effective enough in those first four years.

The implant can be removed in total (in local anesthetics), for instance in case of pain (which is sometimes described  $\leq 1\%$ ) or partially, by removing only the abutment (non-use or recurrent infections) and skin will close over the implant. The longevity is good, few revision surgeries needed in adults as long as bone conduction thresholds in the contralateral ear are not declining significantly. Again: children are different.

#### *Costs*

Insurance, resources and prices differ amongst countries, in general the newest devices get more expensive. The percutaneous devices are still the least expensive.

### *Performance and benefit*

How do we begin to determine patient benefit, let alone compare the performance of different devices? Since currently available quality of life instruments are generally not specific enough to capture hearing benefit/difficulties. In SSD, the patients are satisfied (after on average five years: 83%). This means 17% of non-use. It has been described benefit declines over the years.<sup>5,14</sup> Is training an effective method in order to prevent non-usage? Is a longer trial period needed? Better counseling? Adjustments to the settings over time? Or is the device not powerful enough anymore? These questions need to be answered in the future, especially in this specific group of patients.

In general we believe devices with the highest MPO (headroom), *i.e.*, power or superpower devices, should be chosen for patients with SSD and the performance should be measured and verified. For more technical information, please read [www.snikiimplants.nl](http://www.snikiimplants.nl).

## **1.2. Passive transcutaneous BAHA**

### *Selection criteria*

We have chosen to implant patients with near-normal bone conduction thresholds in the good ear. All patients are loaned a device mounted on a headband for a minimum of two weeks and asked to complete a self-reported diary of usage and benefits. Patients are offered a full range of bone conduction devices from active to passive (percutaneous and transcutaneous). The final decision is taken after an informed and joint decision-making process. Patients like the forward and backward compatibility between the percutaneous and passive transcutaneous devices.

### *Ease of surgical placement*

The procedure can be undertaken either under local or general anaesthetic. Surgical placement is facilitated by appropriate planning. The implant magnet needs to be placed at least five cm behind the external auditory canal with the fixture preferably along the temporal line (such that the external processor does not touch the pinna). It is best to palpate the post-aural region for an area where the bone is relatively flat and even. This allows the implant magnet to sit flat on the skull without the need for bone polishing. Bone polishing had been required in 4% of cases.

The incision is usually a curvilinear one with the aim of raising a semicircular scalp flap the rim of which is concentric with the rim of the implant magnet. Although the manufacturers recommend a posteriorly facing 'C'-shaped incision placed in the post-aural region, most experienced centers have always used an inferiorly facing 'C'-shaped incision as this is less visible, has less chance scar tenderness from overriding spectacle frames and produces a smaller area of numbness.

The recommended skin thickness needed to be less than six mm. This is done using the special skin thickness gauge provided by the manufacturer. Skin thinning was needed in 10% of cases where the thickness was above recommendation.

### *Device tolerance*

In over one hundred cases so far there has been good acceptance and device tolerance overall. Four patients experienced pain at the site of the implant in the early stages. In all cases this was due to prolonged use of the device without any gaps. Two of the paediatric patients also had some redness and tenderness of the scalp over the implant but this resolved with conservative management.

### *Postoperative limitations*

The scalp flap usually settles down rapidly after the surgery and it is felt that any residual oedema dissipates by four weeks when the external processor is usually loaded.

However, there is an increasing demand for conversion recently from percutaneous to transcutaneous devices for various reasons (skin problems with the percutaneous abutments, cosmesis, avoidance of daily aftercare,

dexterity in the elderly, etc.). Skin attenuation does not seem to affect the decision to convert from a percutaneous to a transcutaneous device at this time point. In general, the process is staged. The abutment is first removed in clinic and four weeks is allowed to elapse before the conversion procedure. It is best to avoid conversions at a site where the dermatome was used to create a split thickness skin flap as was common in the earlier generations of BAHA surgery. Considerations is also given to any skin thinning undertaken in the initial surgery, the generation of the existing fixture and it's compatibility with the new implant screw, siting of the new fixture if needed and its relationship with the incision and the old fixture.

### *Costs*

The current pricing of the passive transcutaneous device is comparable to the percutaneous ones and lower than the active transcutaneous devices. All devices are currently fully reimbursed under the National Health Service as long as fitting the existing commissioning guidelines.

### *Performance and benefit*

The device performance is satisfactory with respect to the sound quality, amplification, retention and comfort. The average magnet strength used in the adult population was four and three for the children. Some patients use a range of magnets reserving a higher strength for more active periods, *e.g.*, active work, sports, etcetera and a weaker one when less active. Many users like the wide range of connectivity with other devices like the mobile phones, television streamer, lapel microphone, etcetera. Early reports have shown that application of a passive transcutaneous device result in skin dampening and a significant threshold difference of 5-20 dB for frequencies 1-4 kHz. When discussing different bone conduction options with the patient, the less favorable MRI-compatibility compared to percutaneous devices should additionally be taken into consideration.

## **1.3. Patients' perspective**

As we alluded to earlier, measurement of outcomes is not trivial with this patient group. First, consider that many of these people have gone their entire lives hearing normally from both ears. Hearing loss was often not a concern from birth. Then suddenly they realize their hearing handicap, or slowly over a period of weeks of months lose their hearing on one side. Of course this has an immediate and tremendous impact on their hearing. But it also makes them a slightly different group compared to the individuals with, say, lifelong bilateral chronic ear disease or congenital SSD. It is important to consider that many acquired SSD patients often feel quite desperate to be returned to a state of 'normal hearing' and, as such, may present with extremely high expectations of the treatment and the devices. They may, for example, hope that sound localization will be returned or that hearing in background noise (the biggest complaint) will be returned to a reasonable level for them after treatment. It is critical that the clinician and the patient form a trusting alliance and manage these expectations carefully together. A related issue that we need to pay close attention to in the SSD group is their readiness to handle the treatment and whether they have had sufficient time to adjust to their new hearing reality. We believe that people need to have had a significant time to come to terms with their hearing loss before they should be treated. And as said above, patients should be given a one- to two-week trial with a sufficiently powerful device on a headband before a surgical decision is made.

## **2. Outcome measurement**

When considering outcome measures, we want measurement tools that show a high degree of sensitivity to the treatment so that we can measure change. One example, often used in bone conduction and cochlear implant research, is the aided sound field threshold or aided audiogram. This tool is meant to demonstrate that hearing has improved in the aided condition. However, it has very low ecological validity (nobody ever walks into the clinic

and says ‘I’d really like to be able to hear soft warble tones in quiet better’). It can also be significantly misleading, especially when the patient has only one good ear available with which to hear. In a quiet room, listening to warble tones, the good ear would need to be plugged in order to show the effects of the bone conduction (BC) device. However, this creates an occlusion effect that artificially improves the BC thresholds and makes the device look like it is potentially more effective than it is in reality.<sup>15</sup> Additionally, the test is known to have poor test-retest reliability, on the order of about 15 dB at most frequencies. In other words, if you tested someone on Monday and got an aided threshold of 20 dB and if you tested them again on Tuesday (after making adjustments to the aid), the threshold differences would have to be  $> 35$  or  $< 5$  dB in order to be considered clinically different.<sup>16</sup> So the measure has significant limitations with respect to reliability and hence the sensitivity to detect which device is better than the next. Newer approaches for assessing the output of the devices are now available using the skull simulator and should be used when possible, as these measures are highly sensitive to device differences.<sup>17</sup>

The general recommended approach to assessing performance, then, should strive to involve a electromechanical evaluation of the device output in comparison to the individual’s thresholds (sensation level assessment) and then validation should include measures that are known to be sensitive to device changes. These include speech in noise tests such as the Hearing in Noise Test (HINT) and the QuickSIN for objective measures.<sup>18,19</sup> Patient-reported questionnaires like the Speech Spatial Qualities questionnaire are also beneficial to this population as they allow for correlations to be made between measured speech in noise and self-reported speech in noise.<sup>20</sup> Additionally, the spatial questions are quite helpful in assessing localization challenges for this group and can provide a good tool for follow up counseling. In our clinic, we always start each appointment with the Client-Oriented Scale of Improvement.<sup>21</sup> This tool allows us to set individual goals for each patient and prioritize them. If there are any unrealistic goals (*e.g.*, ‘I want to be able to locate where a sound is coming from’) then we can work together on clarifying that right up front with the patient.

It has been our experience that the SSD group is a slightly more challenging group to manage in the BAH world.<sup>22</sup> However, given sufficient time to adjust to the loss, a trial with a CROS hearing aid or a headband with a powerful enough device, and careful management of expectations and readiness, this group can be helped.

## References

1. Wazen JJ, Spitzer JB, Ghossaini SN, et al. Transcranial contralateral cochlear stimulation in unilateral deafness. *J Otolaryngol Head Neck Surg* 2003;129:248-254.
2. Lin LM, Bowditch S, Anderson MJ, et al. Amplification in the rehabilitation of unilateral deafness: speech in noise and directional hearing effects with bone-anchored hearing and contralateral routing of signal amplification. *Otol Neurotol* 2006;27:172-182.
3. Hol MK, Kunst SJ, Snik AF, et al. Pilot study on the effectiveness of the conventional CROS, the transcranial CROS and the BAHA transcranial CROS in adults with unilateral inner ear deafness. *Eur Arch ORL* 2010;267:889-896.
4. Harford E, Dodds E. The clinical application of CROS. A hearing aid for unilateral deafness. *Arch Otolaryngol* 1966;83:455-464.
5. Faber HT, Nelissen RC, Kramer SE, et al. Bone-anchored hearing implants in single-sided deafness patients: Long-term use and satisfaction by gender. *Laryngoscope* 2015;125:2790-2795.
6. Baguley DM, Bird J, Humphriss RL, et al. The evidence base for the application of contralateral bone anchored hearing aids in acquired unilateral sensorineural hearing loss in adults. *Clin Otolaryngol* 2006;31:6-14.
7. Faber HT, Kievit H, de Wolf MJ, et al. Analysis of factors predicting the success of the bone conduction device headband trial in patients with single-sided deafness. *Arch Otolaryngol Head Neck Surgery* 2012;138:1129-1135.
8. Verstraeten N, Zarowski AJ, Somers T, et al. Comparison of the audiologic results obtained with the bone-anchored hearing aid attached to the headband, the testband, and to the “snap” abutment. *Otol Neurotol* 2009;30:70-75.
9. Reinfeldt S, Håkansson B, Taghavi H, Eeg-Olofsson M. New developments in bone-conduction hearing implants: a review. *Med Devices (Auckl)*. 2015 Jan 16;8:79-93. doi: 10.2147/MDER.S39691. eCollection 2015.

10. den Besten CA, Bosman AJ, Nelissen RC, et al. Controlled Clinical Trial on Bone-anchored Hearing Implants and a Surgical Technique With Soft-tissue Preservation. *Otol Neurotol* 2016;37:504-512.
11. Husseman J, Szudek J, Monksfield P, et al. Simplified bone-anchored hearing aid insertion using a linear incision without soft tissue reduction. *J Laryngol Otol* 2013;127 Suppl 2:S33-38.
12. Martinez P, Lopez F, Gomez JR. Cutaneous complications in osseointegrated implants: comparison between classic and tissue preservation techniques. *Acta ORL Esp* 2015;66:148-153.
13. Nelissen RC, Stalfors J, de Wolf MJ, et al. Long-term stability, survival, and tolerability of a novel osseointegrated implant for bone conduction hearing: 3-year data from a multicenter, randomized, controlled, clinical investigation. *Otol Neurotol* 2014;35:1486-1491.
14. Desmet J, Wouters K, De Bodt M, et al. Long-term subjective benefit with a bone conduction implant sound processor in 44 patients with single-sided deafness. *Otol Neurotol* 2014;35:1017-1025.
15. Stenfelt S, Reinfeldt S. A model of the occlusion effect with bone-conducted stimulation. *Int J Audiol* 2007;46:595-608.
16. Hawkins DB. Limitations and Uses of the Aided Audiogram. *Semin Hear* 2004;25:51-62.
17. Hodgetts WE, Scollie SD. DSL prescriptive targets for bone conduction devices: adaptation and comparison to clinical fittings. *Int J Audiol* 2017 Mar 27:1-10. doi: 10.1080/14992027.2017.1302605. [Epub ahead of print]
18. Nilsson M, Soli SD, Sullivan JA. Development of the Hearing in Noise Test for the measurement of speech reception thresholds in quiet and in noise. *J Acoust Soc Am* 1994;95:1085-1099.
19. Killion MC, Niquette PA, Gudmundsen GI, et al. Development of a quick speech-in-noise test for measuring signal-to-noise ratio loss in normal-hearing and hearing-impaired listeners. *J Acoust Soc Am* 2004;116:2395-2405.
20. Gatehouse S, Noble W. The Speech, Spatial and Qualities of Hearing Scale (SSQ). *Int J Audiol* 2004;43:85-99.
21. Dillon H, James A, Ginis J. Client Oriented Scale of Improvement (COSI) and its relationship to several other measures of benefit and satisfaction provided by hearing aids. *J Am Acad Audiol* 1997;8:27-43.
22. Dumper J, Hodgetts B, Liu R, et al. Indications for bone-anchored hearing AIDS: a functional outcomes study. *J Otolaryngol Head Neck Surg* 2009;38:96-105.

# TURNER SYNDROME: TRANSLATIONAL RESEARCH CONCERNING EAR AND HEARING. A SUMMERY FROM RECENT YEARS

Malou Hultcrantz

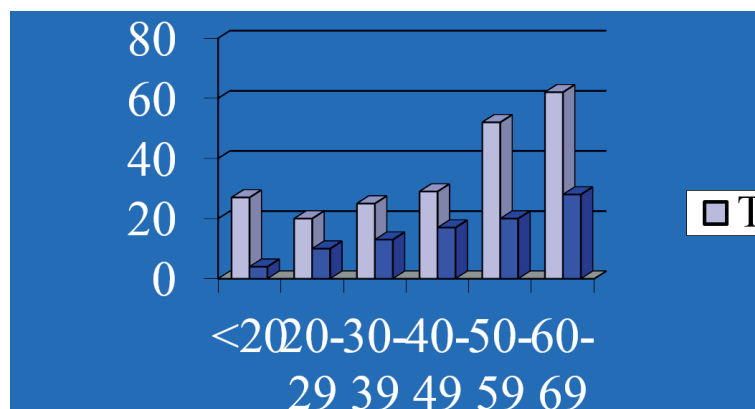
*Department of Otorhinolaryngology, Karolinska University Hospital, Stockholm, Sweden*

## 1. Introduction

When genetically losing one X-chromosome, no or very low levels of estrogen is produced due to the loss of ovaries. This is found in Turner syndrome (TS), in which hearing problems have been found to be frequent and have therefore been added to the occurring symptoms. Because estrogen is missing, there are indications that estrogens may have an effect on the ear and hearing. Also, the research concerning human and experimental research, *i.e.*, translational research, over the years is described and summarized.

Studies suggest that sex-steroid hormones may be involved in the hearing process and it is known that females in general, up to the menopause, have better hearing than men.<sup>1</sup> After the age of 60, the female hearing loss becomes more like the loss seen in males. Estrogen might have a protective effect.<sup>2,3</sup> Findings are seen in women with TS, who lack an X-chromosome and are biologically estrogen-deficient. These women have severe ear and hearing problems as compared to other women (Fig. 1):<sup>4,5</sup> extensive otitis media and otitis media with effusion in the early years, a sensory neural dip in the mid frequencies and an early onset of 'presbycusis' (at > 35 years of age).

The syndrome is defined as a total or partial loss of the second sex chromosome in girls or women.<sup>6</sup> Cardinal features of TS include short stature, failure to enter puberty spontaneously and infertility due to ovarian insufficiency and other associated findings that occur to a varying degree.<sup>6</sup> The source for estrogen production is the female ovaries, the adipose tissue and brain as well as adrenal cortex in both genders. Estrogen is known to reduce cell death, increase axonal sprouting, increase regeneration and affect synaptic transmission.<sup>3,7</sup>



*Fig. 1. Hearing decline over time in normal ageing women (dark blue) as compared to women with TS (light blue). A 60-year-old woman in the Turner cohort presented with the same hearing as a 40-year-old woman in the normal population. (From: see ref. 5.)*

Correspondence: Malou Hultcrantz, M.D., Professor, Department of Otorhinolaryngology Head and Neck Surgery, Karolinska University Hospital, 171 76 Stockholm, Sweden.  
E-mail: malou.hultcrantz@sl.se

*Cholesteatoma and Ear Surgery – An Update 2017, pp. 121 -126*

*Edited by Matthew Yung*

*2017 © Kugler Publications, Amsterdam, The Netherlands*



## 2. Experimental studies

### 2.1. Estrogen receptors

To try to prove that estrogen can have a direct effect on the ear, estrogen receptors must be present. Animal models could immunohistochemically show two receptors: estrogen receptor alfa (ERa) and beta (ERb)(Fig. 2), in places where hearing pathways are located.<sup>8</sup> In the inner ear, ERs were detected in the stria vascularis, the inner hair cells and outer as well as in the spiral ganglion. This has been proven for species like rats, pigs and also in humans. The number of receptors varies during the development of the inner ear.<sup>9</sup>

### 2.2. The Turner mouse

To further strengthen the connection between sex hormones and hearing a ‘Turner mouse’ was created. Hearing was tested with auditory brainstem recordings (ABR) and the results indicate that hearing problems in the Turner mouse seem to be of cochlear origin, with an eight-nerve component.<sup>10</sup> These mice do have estrogen receptors in the inner ear when performing immunohistochemistry but lack circulating estrogen.

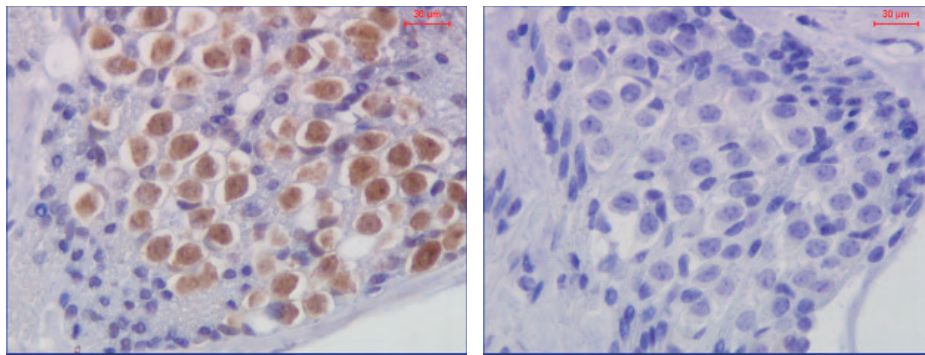


Fig. 2. Estrogen receptor beta in the spiral ganglion shown as a brownish staining in the ganglion cells (left) as compared to a negative control (right). (From: see ref. 8.)

### 2.3. Receptor beta knock-out mice

Is one estrogen receptor more important than the other? When using knock-out mice, in which the receptors – one at a time (ERa and ERb) – were knocked out, it could be detected that the ERb seems to be more significant for hearing. The ERb knock-out mouse was deaf at the age of one year. Morphological analysis showed absence of hair cells and loss of the whole organ of Corti, initiated in the basal turn of the cochlea (Fig. 3).<sup>11</sup> This was not seen to the same extent when knocking out the ERa. It is concluded that ERb could be important for the prevention of age-related hearing loss.

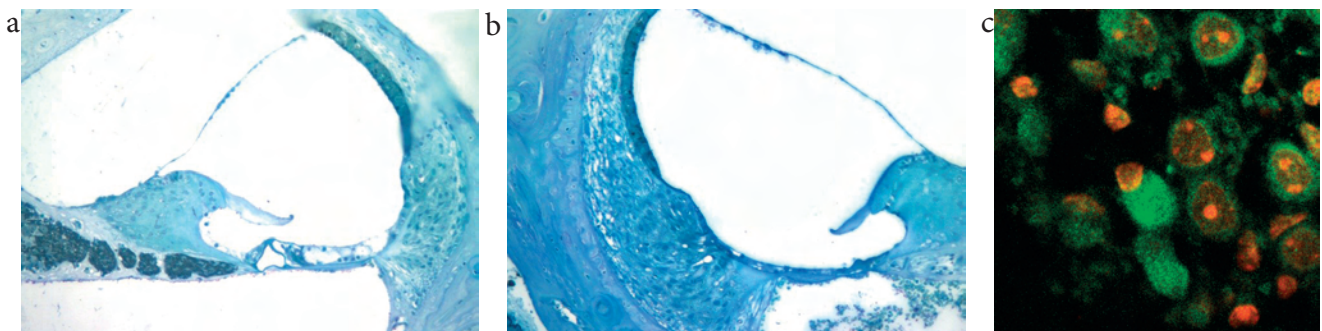


Fig. 3. The ERb knock-out mouse showed from birth a normal organ of Corti (a), but after one year, the whole organ is missing (b) and in ganglion cells only ER alfa is present (c; green staining). (From: see ref. 11.)

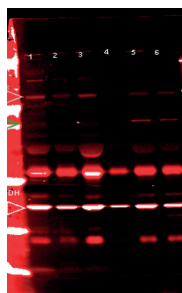


Fig. 4. Clear white line for PR-B (Western blot, white arrow, 120 bp) but no PR-A in both male rat cochlea (lane 1 and 2) and female rat (lane 3 and 4). (From: see ref. 13)

## 2.4. Androgen and progesterone receptors in the inner ear of mice

Many studies indicate an effect of progesterone on the inner ear by alteration of hearing thresholds. Guimaraes *et al.* concluded that the presence of progestin in hormone replacement therapy is the cause of poor hearing in aged women.<sup>12</sup> If that is the case, progesterone receptors should be detected and localized in the inner ear in areas responsible for hearing. However, this could never be confirmed (Fig. 4),<sup>13</sup> which leads us to suspect that the negative effect of progestin may not be a direct, but rather an indirect effect. Progestin may influence the estrogen pathways

(i.e., by interacting with the estrogen receptors which are known to be present in the inner ear).

Androgen receptors could likewise not be detected in the mouse inner ear.

## 3. Human studies

### 3.1. Turner syndrome

#### 3.1.1. Immunohistological findings

Aborted human fetuses (from Austria according to their ethical protocol) with the chromosome content of Turner syndrome (X,0) could be compared to aborted fetuses with a normal chromosome content. It could be shown that there are mostly E $\alpha$  receptors in the inner ear seen during early development in the human Turner fetus. The conclusions drawn were that it is not the lack of receptors, at least not the E $\alpha$ , in the syndrome that have an impact on hearing but more probably the estrogen deficiency.<sup>14</sup>

#### 3.1.2. Hearing and ageing among the Turner females

The features of the sensorineural hearing loss were studied in a group of 30 TS women, aged 40-67, with a battery of peripheral and central auditory tests. All tests show that the sensorineural hearing loss seems to be of a cochlear origin in TS, which is in accordance with the animal studies. Mild disturbances of sound localization are seen in TS women who have not been substituted with estrogens during puberty which adds an auditory-spatial dysfunction in the field of neurocognition.<sup>15</sup>

#### 3.1.3. Deterioration of hearing among Turner women

Women with TS often develop a sensorineural mid-frequency dip in their teens or in early adult age. This is usually not a clinical problem as long as the high-frequency region is intact. However, it could be shown in a ten-year follow-up study that hearing decline is much faster among the TS women and that the rate of decline is especially high in the high frequency region. The rate of hearing decline is comparable to a level seen in 70-90-year-old women in the normal population (Fig. 5). The presence of a dip is a strong predictor for future high rate of hearing deterioration. The hearing decline seems to consist of two patterns, one a genetic mid-frequency dip and the other a high-frequency, possibly estrogen-associated, loss resembling age related hearing impairment.<sup>16</sup>

### 3.2. Menopause and hearing in the normal population

#### 3.2.1 Menopause triggers hearing decline

Hearing decline in women coincides with the menopausal transition.<sup>18</sup> Healthy females with a known starting point of menopause were tested with pure-tone audiometry twice, with an average interval of 7.5 years. Hearing decline for individual frequencies in dB/year was calculated. Women with a recent menopause had a lower rate of hearing decline compared to those with a longer time since the final menstrual period. High-frequency hearing

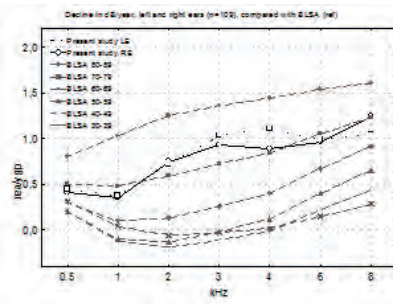


Fig. 5. Mean annual rate of hearing decline in dB/year for the left and right ears followed over a period of 7.5 years. Six different aged cohorts from the Baltimore Longitudinal study of ageing were used in the comparison. (From: see ref. 18.)

decline in peri-menopausal women is relatively rapid; at 3-8 kHz the rate of decline is close to 1 dB/year, which is close to the pace in a 70-79 year old woman. The present study shows that the menopausal transition, rather than age alone, sets off a period of accelerated hearing decline in healthy middle-aged women.<sup>19</sup> The process of hearing decline is still going on ten years after menopause transition.<sup>20</sup>

#### 4. Conclusion

Estrogen and hearing seem to have a connection. There are estrogen receptors in the inner ear which may indicate a direct effect of estrogen in the circulation fluids. Also, animal experiments could show that ER $\beta$  seems to be the most important receptor for the hearing. Clinical studies showed that menopause – the time for deterioration of estrogen in the normal population – seems to trigger the hearing decline and that it happens in a faster pace during this period in the female life. Based on these studies, guidelines for clinical counseling of Turner syndrome and hearing have been formulated.<sup>21</sup>

#### References

1. Jönsson R, Rosenhall U, Gause-Nilsson I, Steen B. Auditory function in 70- and 75-year-olds of four age cohorts. A cross-sectional and time-lag study of presbycusis. *Scand Audiol* 1998;27(2):81-93.
2. Coleman JR, Campbell , Cooper WA, Welsh, MG, Moyer J. Auditory brainstem responses after ovariectomy and estrogen replacement in rat. *Hear Res* 1994;80:209-215.
3. Brann DW, Dhandapani K, Wakade C, Mahesh VB, Khan MM. Neurotrophic and neuroprotective actions of estrogen: basic mechanisms and clinical implications. *Steroids* 2007;72(5):381-405.
4. Gungor N, Boke B, Belgin E, Tuncbilek E. High frequency hearing loss in Ullrich-Turner syndrome. *Eur J Pediatr* 2000;159(10):740-744.
5. Hultcrantz M, Simonoska R, Stenberg AE. Estrogen and hearing: a summary of recent investigations. *Acta Otolaryngol* 2006;126(1):10-14.
6. Saenger P. Turner's syndrome. *N Engl J Med* 1996;335(23):1749-1754.
7. Wang L, Andersson S, Warner M, Gustafsson JA. Estrogen actions in the brain. *Sci STKE* 2002, PE29.
8. Stenberg AE, Wang H, Sahlin L, Hultcrantz M. Mapping of estrogen receptors alpha and beta in the inner ear of mouse and rat. *Hear Res* 1999;136:29-34.
9. Simonoska R, Stenberg A, Masironi B, Sahlin L, Hultcrantz M. Estrogen receptors in the inner ear during different stages of pregnancy and development in the rat. *Acta Otolaryngol* 2009;129(11):1175-1181.
10. Stenberg AE, Wang H, Sahlin L, et al. Estrogen receptors alpha and beta in the inner ear of the 'Turner mouse' and an estrogen receptor beta knockout mouse. *Hear Res* 2002;166(1-2): 1-8.
11. Simonoska R, Stenberg A, Duan M, et al. Severe progressive hearing loss and inner ear pathology in estrogen receptor beta deficient mice. *J Endocrinol* 2009;201(3):397-406.

12. Guimaraes P, Frisina ST, Mapes F, et al. Progesterone negatively affects hearing in aged women. *Proc Natl Acad Sci U S A* 2006;103:14246-14249.
13. Bonnard Å, Sahlin L, Hultcrantz M, Simonoska R. No direct effect of progesterone in the inner ear: other possible pathways? *Acta Otolaryngol* 2013;133(12):1250-1257.
14. Stenberg A, Wang H, Fish J, Schrott-Fischer A, Sahlin L, Hultcrantz M. Estrogen receptors in the normal adult and developing human inner ear and in Turner syndrome. *Hear Res* 2001;157:87-92.
15. Hederstierna C, Hultcrantz M, Rosenhall U. Estrogen and hearing from a clinical point of view; characteristics of auditory function in women with Turner syndrome. *Hear Res* 2009;252(1-2):3-8.
16. Hederstierna C, Hultcrantz M, Rosenhall U. A longitudinal study of hearing in women with Turner syndrome. *Acta Otolaryngol* 2009;129(12):1434-1441.
17. Wharton JA, Church G. Influence of Menopause on the Auditory Brainstem Response. *J Audiol* 1990;29:196-201.
18. Hederstierna C, Hultcrantz M, Collins A, Rosenhall U. The menopause triggers hearing decline in healthy women. *Hear Res* 2010;259(1-2):31-35.
19. Svedbrant J, Bark R, Hultcrantz M, Hederstierna C. Hearing-decline in menopausal women – A 10-year follow-up. *Acta Otolaryngol* 2015;135(8):807-813.
20. Saenger P, Albertsson-Wikland K, Conway G, et al. New recommendations for the diagnosis, treatment and management of Turner syndrome. *J Clin Endocrinol Metab* 2001;86:3061-3069.



# PREDICTIVE FACTORS FOR RECURRENT CHOLESTEATOMA IN CHILDREN

Adrian James

*Department of ORL-HNS, Hospital for Sick Children, University of Toronto, Canada*

## Key points

- Careful recording and analysis of surgical intervention and outcome provides valuable insight into the effectiveness of otologic intervention for cholesteatoma;
- Recurrent cholesteatoma differs from residual cholesteatoma and must be evaluated separately;
- Survival analysis is required to control for the increasing incidence of recurrence with longer follow-up;
- Extent of cholesteatoma at the time of initial surgery is the single most important predictor of recurrent disease;
- Understanding of the risk of recurrence is confounded by selection of surgical technique according to the extent of disease;
- ‘Bad ears do badly and good ears do well’ it is arguably most important to maximize strategies to prevent recurrent disease in those thought to be most at risk.

## 1. Introduction

Recurrent cholesteatoma is a disease that is acquired from new growth of skin into the middle ear or mastoid after previous surgical removal. This cause of recidivism differs from residual cholesteatoma which grows from remnants of squamous epithelium that were left in situ because of incomplete removal at prior surgery. In order that strategies may be developed to reduce cholesteatoma recidivism, it is important to distinguish between recurrent and residual disease: clearly the causes differ and so preventative strategies will differ.

This manuscript investigates factors associated with recurrent cholesteatoma in children (*i.e.*, not residual cholesteatoma). Typically recurrent disease forms from retraction of the tympanic membrane into the mesotympanum or epitympanum from where it may extend more deeply into the mastoid or elsewhere. After canal-wall-up (CWU) surgery, cholesteatoma occasionally recurs from retraction between the bony and cartilaginous meatus. The latter may result from lowering of the canal wall during cortical mastoidectomy which opens up the potential route of in-growth.

Recurrent cholesteatoma is widely considered to be less common, or even prevented, by canal-wall-down (CWD) surgery. When achievable, complete exenteration of mastoid air cells and the creation of a mastoid cavity with solid bony limits removes spaces into which recurrent disease could spread. Nevertheless, recurrent cholesteatoma can occur after CWD surgery, for example by retraction of the pars tensa into a deep sinus tympani, or into persistent mastoid air cells after a small-cavity atticotomy.

Perhaps especially in growing children, bone of the mastoid cortex can grow across the lateral aspect of a mastoid cavity. In CWD surgery, this will narrow the meatoplasty which is typically fashioned as part of modified

Correspondence: A.L. James, MD, Department of Otolaryngology Head & Neck Surgery, University of Toronto, Hospital for Sick Children, 555 University Avenue, Toronto, M5G 1X8, Canada.

E-mail: Adrian Lewis James <adr.james@utoronto.ca>

*Cholesteatoma and Ear Surgery – An Update 2017, pp. 127 -132*

*Edited by Matthew Yung*

*2017 © Kugler Publications, Amsterdam, The Netherlands*



radical mastoidectomy to facilitate cavity maintenance. When this happens, access to the posterior and inferior limits of the cavity for debridement becomes impeded, and keratin debris may begin to collect in these inaccessible recesses. When infected, this produces troublesome otorrhoea that is likely to require surgical revision to achieve resolution. By definition, keratinizing squamous epithelium producing keratin that cannot be removed from the ear is cholesteatoma. As this form of cholesteatoma has arisen after previous surgery, it can to some extent be considered recurrent disease. Of course the mechanism is very different from the recurrent retraction disease found after CWU surgery, but for the child and family, the outcome is the same when revision surgery is required to remove a skin collection to achieve a healthy ear.

A clear understanding of factors that predispose to recurrent disease might help selection of optimal surgical technique for disease control for example guiding the choice between CWU or CWD surgery and mastoid preservation or obliteration. This manuscript investigates the relationships between patient, disease and surgery in the development of recurrent cholesteatoma in children. The objectives of this study were to determine whether we can predict which cases will recur from status of the ear at the time of surgery and whether we can modify surgical approach or technique to prevent recurrence.

## 2. Method

The Hospital for Sick Children Research Ethics Board granted approval for this study.

A single-surgeon prospective database of consecutive pediatric cholesteatoma surgeries was maintained since 2005, recording details of patient demographics, disease extent, surgical intervention and outcome. Data were extracted from this database that were considered relevant to the study of recurrent cholesteatoma. These factors included status at the time of surgery: age, gender, source of cholesteatoma (acquired from pars tensa or flaccida retraction or congenital), extent of cholesteatoma (using Mill's stage or number of sub-sites involved out of middle ear, attic, antrum, mastoid<sup>1</sup>). Surgical factors extracted and analyzed included: type of surgery (*e.g.*, CWU or CWD; whether a cortical mastoidectomy was required or solely a tympanoplasty approach was used for CWU; use of cartilage or fascia for reconstruction) and years of experience of surgeon. Inclusion criteria for the study were age < 18 years and no prior history of cholesteatoma surgery. The database included 40 cases of 'pre-cholesteatoma' defined as atelectasis with progression, keratin accumulation or granulation tissue in which surgery was indicated by failure of clinic based management.

The surgical techniques used in this study and criteria for selecting CWU or CWD have been described previously.<sup>2-5</sup> In this study, CWU includes removal of cholesteatoma by tympanoplasty approach, atticotomy with scutum reconstruction, combined approach tympanomastoidectomy. CWD includes atticantrostomy with soft canal wall reconstruction (*i.e.*, fascia, not cartilage) or modified radical mastoidectomy with or without obliteration.

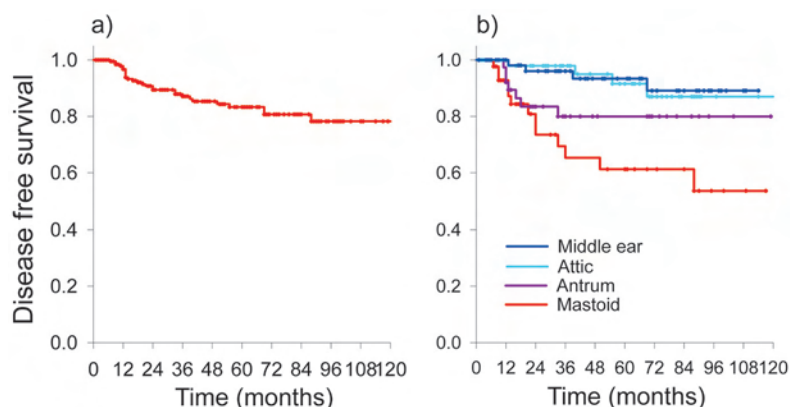


Fig.1. Kaplan Meier survival curves to show time to recurrence of cholesteatoma. (a) All cases under 13 years of age at time of surgery (excluding pre-cholesteatoma and implantation cholesteatoma from previous surgery); (b) Extent of cholesteatoma defined by location, *i.e.*, in middle ear, in epitympanum, in antrum, in mastoid, showing significantly higher rate with more extensive disease.

The primary outcome measure was proportion of cases with recurrent cholesteatoma at five years. Data were analyzed by Kaplan-Meier survival analysis to control for variable length of follow-up using log rank statistic to compare significance of dependent variables. As care or patients in this pediatric series was referred on to outside institutions at age 18 years, analysis was repeated for patients under 13 years of age at time of surgery to allow the prospect of five-year follow-up. Multiple logistical regression analysis was used to compare the relative contribution of factors found to be significant with survival analysis. Selected subgroup analyses were conducted post hoc in an attempt to control for the effect of other variables shown by the initial analysis to alter the rate of recurrence. Analysis was completed and graphs prepared using SigmaPlot 11.<sup>1</sup> software.

### 3. Results

The database included records of 700 consecutive operations for cholesteatoma in children on 450 ears. Of these 332 were excluded as being revision surgeries, leaving 368 cases for assessment. The average age at the time of surgery was 10.0 years. Two thirds of cases were boys. The origin of cholesteatoma was thought to be congenital in 12% cases; most acquired cases arose from retraction of the pars tensa, which was twice as common as from the pars flaccida. Cholesteatoma was found to be present in the middle ear in 227 cases, in the attic in 227 cases, in the antrum in 137 cases and the mastoid in 69 cases. 40 cases were described as pre-cholesteatoma.

Recurrent cholesteatoma occurred in 35 cases, an overall recurrence proportion of 9.5% cases. Controlling for the effect of time with Kaplan Meier analysis, the recurrence rate at five years was 12% and 17% at ten years. When restricting the analysis to children < 13 years of age and excluding cases with cholesteatoma secondary to surgical implantation or cases of pre-cholesteatoma, 17% recurred at five years and 22% at ten years (Fig. 1a).

Comparison of five-year Kaplan-Meier survival data for different subgroups is shown in Table 1. Although boys are more at risk of cholesteatoma than girls, the rate of recurrence was the same regardless of gender. There was no significant difference in recurrence between congenital and acquired cholesteatoma. Overall, recurrence of cholesteatoma did not appear to be associated with young or older age at time of surgery, but subgroup analysis suggests a greater risk for the youngest children with acquired cholesteatoma.

As shown in Figure 1b, the extent of cholesteatoma at the time of initial surgery has a significant effect on the risk of subsequently developing recurrent cholesteatoma. The data are also summarized in Table 1 and it can be seen that when cholesteatoma extends deeper into the mastoid than the antrum, recurrent disease is three or four times more likely than when it is confined to one sub-site in the ear with the rate depending to some extent on how the extent of disease is classified ( $p < 0.003$  Kaplan-Meier log rank analysis). A subgroup analysis is included to show the effect of excluding children > 13 years of age (*i.e.*, those with no prospect of achieving five years follow-up).

The effect of surgical approach on recurrence rate is also shown in Table 1. It was found that there was no difference in five-year recurrence rate for CWU or CWD, even when controlling for the confounding effect of extent of cholesteatoma by subgroup analysis of cases with spread beyond the antrum into the mastoid. With CWU surgery, cases having a mastoid sparing approach (tympanoplasty or atticotomy with scutum reconstruction) had less recurrence than those having a combined approach tympanomastoidectomy, but this finding is obviously confounded by the extent of disease. Overall cartilage did not alter recurrence rates, but subgroup analysis of CWU cases with a scutum defect showed a benefit from using cartilage.

Multivariate analysis (which does not account for duration of follow-up) showed that extent of cholesteatoma (using Mill's stage) was the most significant predictor of recurrent cholesteatoma (Odds Ratio 1.6 (95% CI: 1.1-2.1)  $p = 0.002$ ; multiple logistical regression). Age was also, but less strongly, associated with recurrence (OR 0.9 (0.8-0.98)  $p = 0.02$ ). Other patient or disease factors were not independently associated with recurrence in multivariate. Choice of surgical approach was determined by extent of disease.

Table 1. Cholesteatoma recurrence rate at five years according to patient, disease and surgical factors.

Factor	Comparators	Number of cases		Recurrence at 5 years	
		n	%age	%age	Significance
<b>Overall</b>		368	100%	13%	
<b>Gender: all cases</b>					
	Boys	234	64%	12%	NS
	Girls	134	36%	14%	
<b>Age: all cases (dichotomised above or below average age)</b>					
	≤10 years age	158	43%	15%	NS
	10 - ≤18 years age	210	57%	11%	
<b>Age: subgroup ≤13 years age (excluding congenital)</b>					
	≤9 years age	82	27%	20%	p = 0.04
	9 - 13 years age	225	73%	10%	
<b>Origin: all cases</b>					
	Congenital	42	12%	9%	NS
	Primary Acquired	309	88%	13%	
	(Implantation )	17			
<b>Extent: (Mills stage) all cases (except surgical implantation)</b>					
	Precholesteatoma	40	11%	7%	p < 0.003
	Stage 1	105	30%	9%	
	Stage 2	89	25%	11%	
	Stage 3	61	17%	13%	
	Stage 4	56	16%	30%	
<b>Extent: (subsite involvement) subgroup ≤13 years age</b>					
	a: Middle ear (ME) only	67	31%	7%	p < 0.001
	b: Attic (At) & ME	60	28%	10%	
	c: Antrum (An) & ME & At	43	20%	20%	
	d: Mastoid & ME & At & An	46	21%	40%	
<b>Canal wall up or down: all cases</b>					
	Canal wall up (CWU)	327	89%	12%	NS
	Canal wall down (CWD)	39	11%	14%	
<b>Tympanomastoidectomy: subgroup disease into mastoid (i.e. matched for extent)</b>					
	Canal wall up (CWU)	51	74%	28%	NS
	Canal wall down (CWD)	18	26%	30%	
<b>Canal wall up: all cases (i.e. not matched for extent)</b>					
	No cortical mastoidectomy	102	54%	10%	p = 0.03
	Tympanomastoidectomy	87	46%	20%	
<b>Use of cartilage: all CWU cases (i.e. not matched for extent)</b>					
	No cartilage	155	47%	15%	NS
	Cartilage reconstruction	172	53%	11%	
<b>Use of cartilage: CWU subgroup, disease in antrum +/- mastoid (i.e. matched for extent)</b>					
	No cartilage	37	33%	25%	NS
	Cartilage reconstruction	74	67%	24%	
<b>Scutum reconstruction: CWU subgroup, atticotomy or tympanomastoidectomy</b>					
	No cartilage	97	54%	22%	0.02
	Cartilage reconstruction	81	46%	11%	
<b>Surgeon's years of experience: all cases</b>					
	< 5 years	152	48%	15%	NS
	> 5 years	167	52%	11%	



#### 4. Conclusions

Many factors are associated with increasing the likelihood of cholesteatoma recurrence. The most obvious of these is time. Even without reviewing data, it will be clear to most otologists that their rate of recurrent cholesteatoma is zero at two months after surgery. It is also evident that without longer-term follow-up no cases of cholesteatoma will be seen. It is essential, indeed in my opinion should be mandatory, that length of follow up should be stated when reporting recurrence rates – indeed the term ‘rate’ implies change per unit of time. Similarly, it is also important that attrition (*i.e.*, loss to follow-up) is accounted for. Kaplan-Meier survival analysis was used to control for these variables in this study showing that with 35 recurrences from 368 cholesteatoma surgeries, the overall rate of recurrence increased from 12% at five years to 17% at ten years.

Subgroup analysis was used in an attempt to glean further information about patient, disease and surgical factors that contribute to the risk of recurrence. Such analysis is complex because many of these variables are co-dependent: for example the variables of young age, congenital origin, small size, tympanoplasty approach without mastoidectomy and without cartilage reconstruction are likely to segregate together. While we might make assumptions about the factors that determine outcome, our preconceptions may not be well founded. This study suggests from multivariate analysis that small size of cholesteatoma is the principle determinant of outcome: extension of cholesteatoma beyond the mastoid antrum was the most significant predictor of recurrence with survival and multivariate analysis.

Surprisingly perhaps for some readers of this manuscript, the rate of recurrence is shown to be the same for congenital and acquired cholesteatoma in children. Other authors have also shown a high risk of retraction and development of acquired cholesteatoma after removal of congenital cholesteatoma.<sup>6</sup> Extensive congenital cholesteatoma should be managed as being at high risk for development of a subsequent acquired cholesteatoma.

Young age may or may not influence recurrence: overall age did not make a difference in this series, but subgroup analysis suggests a possibility that young children with acquired cholesteatoma may be at greater risk. At five years, the rate of recurrence was 20% for the youngest cases ( $\leq$  nine years) and only 10% for those in the middle of the age range (nine to 13 years). There is a risk of introducing selection bias when excluding cases from analysis. The justification for selecting this particular age range is that follow up was discontinued at age 18 years in this series, so all children  $> 13$  years do not have any prospect of completing five years follow-up: inclusion of the oldest children would disproportionately increase the denominator. As stated above, there is no overall difference in recurrence rate with congenital or acquired cholesteatoma. However, congenital cholesteatoma is excluded from this analysis of the effect of age on outcome on the basis that the youngest children typically have small cholesteatomas, and multivariate analysis shows that small size is associated with better outcome. Inclusion of young children with small congenital cholesteatoma in analysis of the effect of age masks the worse prognosis seen in young children with acquired cholesteatoma.

Understanding of the impact of surgical technique is most difficult to understand by uncontrolled analysis as allocation to treatment type is not randomized but based entirely upon current status (of patient, disease and surgeon's perspective) at the time of surgery. In this regard it was interesting (and disappointing) to note that while the author considers that years of experience have lead him to greater surgical insight and technical proficiency, Kaplan-Meier analysis shows no difference in recurrence rate at five years between cases performed in the first half of the study period compared with the second half. It is assumed, but not proven, that there was no change in non-surgical variables (*i.e.*, patient or disease factors) over the study period that could have biased this finding. This finding does suggest that patient/disease factors may be more significant determinants of outcome than surgical experience.

It will again surprise some readers that the five-year rate of recurrence seems to be the same for CWU as for CWD mastoid surgery even when controlling for the extent of cholesteatoma (*i.e.*, analyzing cases extending into or beyond mastoid antrum). To clarify this finding, it is important to reiterate the explanation given in the introduction that recurrence was defined in this study as the requirement for revision surgery to treat an accumulation of

keratin from squamous epithelium that is in continuity with the surface of the tympanic membrane and that could not be kept clean in clinic. While this broad definition goes beyond the more standard mechanistic definition of recurrent retraction from drum or canal skin, and is less helpful for understanding mechanisms of disease, it is a valid patient-focused outcome measure: the child cares only that surgery is required, not the scientist's explanation. Regardless of definitions, it is, at the least, important to recognize that CWD surgery requires revision in children (e.g., because of cortical bone growth across the meatoplasty) at a similar rate to the requirement for recurrence after CWU surgery.

It is widely believed that cartilage reconstruction helps to prevent recurrence of cholesteatoma, yet the current analysis shows that overall, there was no difference in five-year recurrence rate between cases with cartilage reconstruction and no cartilage reconstruction. Post-hoc analysis of a subgroup of cases in whom cartilage was felt more likely to be beneficial (*i.e.*, those with a scutum defect) does seem to show benefit from cartilage. However, there is a risk of selection bias in this analysis and it must be recognized that cartilage does not necessarily prevent recurrence in patients at risk.

## 5. Summary

Recurrent cholesteatoma is different from residual cholesteatoma: the two must not be confused in the study of cholesteatoma outcome. Many factors contribute to the development of recurrent cholesteatoma. It is difficult to control for the co-dependence of these factors when analyzing their relative contributions. Prospective and comprehensive collection of data allows the opportunity to study the impact of some of these factors on outcome. It is clear that the rate of cholesteatoma recurrence increases with time, and that survival analysis must be used when reporting this outcome. This study finds that extent of cholesteatoma is the single largest determinant of the rate of developing recurrent disease, regardless of surgical technique. In particular, extension of cholesteatoma beyond the antrum deeper into the mastoid is the single most important predictor of disease recurrence.

It is suggested that cholesteatoma extent as well as length of follow-up be stated when reporting recurrent disease rates. This finding supports initiatives to develop an internationally accepted staging system for evaluation of cholesteatoma.

## References

1. Saleh HA, Mills RP. Classification and staging of cholesteatoma. *Clin Otolaryngol Allied Sci* 1999;24:355-359.
2. James AL. Approaches to cholesteatoma with an intact ossicular chain: Combined use of microscope, endoscope and laser. In: Takahashi H (ed.), *Cholesteatoma and Ear Surgery – An Update*, pp. 333-336. Amsterdam, The Netherlands: Kugler Publications 2013.
3. James AL. Endoscopic middle ear surgery in children. *Otolaryngol Clin North Am* 2013;46:233-244.
4. James AL, Cushing S, Papsin BC. Residual Cholesteatoma After Endoscope-guided Surgery in Children. *Otol Neurotol* 2016;37:196-201.
5. Osborn AJ, Papsin BC, James AL. Clinical indications for canal wall-down mastoidectomy in a pediatric population. *Otolaryngol Head Neck Surg* 2012;147:316-322.
6. Lazard DS, Roger G, Denoyelle F, Chauvin P, Garabedian EN. Congenital cholesteatoma: risk factors for residual disease and retraction pockets – a report on 117 cases. *Laryngoscope* 2007;117:634-637.

# TYMPANOPLASTY USING MEDIO-LATERAL GRAFT FOR ANTERIOR OR SUBTOTAL TYMPANIC MEMBRANE PERFORATION

Timothy T. K. Jung

*Department of Otolaryngology-Head and Neck Surgery, Loma Linda University, Loma Linda, CA and Jerry L. Pettis Veterans Medical Center, Loma Linda, CA, USA and Inland Ear, Head & Neck Clinic, Riverside, CA, USA*

## Abstract

**Objective:** To describe and evaluate the medio-lateral graft tympanoplasty for the reconstruction of anterior or subtotal tympanic membrane (TM) perforation.

**Methods:** Method of surgical steps are described in detail. All patients underwent preoperative and postoperative audiograms. In the medio-lateral graft technique, the posterior tympanomeatal flap is elevated first. The anterior-medial canal skin is elevated down to the annulus. At the annulus, only the squamous epithelial layer of TM is elevated up to the anterior half of the TM perforation. Temporalis fascia or cartilage and perichondrium is grafted *medial* to the posterior half of the perforation and *lateral* to the anterior half of the de-epithelialized TM perforation up to the annulus. The anterior canal skin is rotated to cover the fascia or perichondria graft and TM perforation as a second layer closure. Patients were followed for at least six months. The outcome was considered successful if TM was healed and intact.

**Conclusion:** The medio-lateral graft method is an excellent method for the reconstruction of large anterior or subtotal TM perforation. This method should help otologic surgeons to improve the outcome of tympanoplasty for anterior or subtotal TM perforation.

## 1. Introduction

One of the common sequelae of chronic otitis media is tympanic membrane (TM) perforation, which can cause hearing loss and otorrhea. The two traditional methods for reconstruction of TM perforation have been medial (underlay) or lateral (overlay) graft techniques. In the underlay technique, the graft is placed entirely medial to the remaining TM and annulus, which is perhaps the most common and easiest technique. It is typically used for posterior or central TM perforations. In the overlay technique, the graft is placed lateral to the annulus, and any remaining fibrous middle layer after the squamous layer has been carefully removed. The anterior canal wall is widened with a drill to minimize blunting, and the graft is placed lateral to the remaining TM but medial to the manubrium of the malleus to prevent lateralization. The canal skin is placed back as a free graft. Each of these techniques has its advantages and disadvantages.<sup>1,2</sup> We have developed a new medio-lateral graft tympanoplasty technique which seems to be superior to the traditional methods for repairing anterior or subtotal TM perforation.<sup>3,4</sup>

The anterior or subtotal TM perforation is difficult to repair because it has less vascularity than the posterior tympanic membrane<sup>4</sup> and because of the anterior bony overhang that blocks visualization. Because of reduced vascularity in the anterior tympanic membrane, there is a greater risk of necrosis and re-absorption of the fascia graft.<sup>5</sup> When the medial graft technique is used to repair an anterior or subtotal TM perforation, the anterior

Correspondence: Timothy T.K. Jung, MD, PhD, 11790 Pecan Way, Loma Linda, CA 92354, USA.  
E-mail: ttjung@gmail.com

*Cholesteatoma and Ear Surgery – An Update 2017, pp. 133 -136*

*Edited by Matthew Yung*

*2017 © Kugler Publications, Amsterdam, The Netherlands*



portion of the fascia graft may fall away, resulting in re-perforation and obliteration of anterior part of middle ear cavity.<sup>6</sup> Although the lateral graft technique has a higher success rate for the reconstruction of anterior or subtotal TM perforation, lateralization of graft may occur, especially when the malleus is absent.

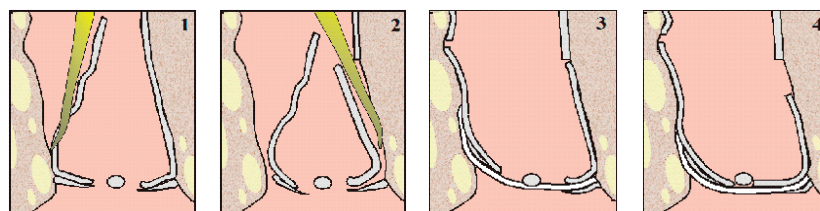
During the past 17 years, we have developed and used the medio-lateral graft tympanoplasty for repair of anterior or subtotal TM perforation. In the medio-lateral graft technique, the fascia graft is placed medially to the posterior half of the TM perforation and laterally to the anterior half of the perforation.<sup>3,4</sup> This method is a hybrid of the medial and lateral graft techniques and includes the advantages of both methods.

## 2. Materials and Methods

### 2.1. Surgical technique

The procedure is usually performed under general anesthesia. Depending on the anatomy and clinical findings, transcanal, endaural, or postauricular approaches are used. A rim of tissue is removed from the perforation edge to de-epithelialize and encourage migration of the mucosal layer and epithelium. Vertical canal incisions are made at the 12- and 6-o'clock positions. The 6-o'clock incision can be extended right up to the annulus. The 12-o'clock incision is made down to a few millimeters above the annulus close to the short process of malleus to preserve blood supply when anterior canal skin is used as the superiorly based flap. A posterior tympanomeatal flap is elevated, and ossicles are evaluated (Fig. 1-1). Mastoidectomy or ossiculoplasty are performed at the appropriate time if needed.

In medio-lateral tympanoplasty, after the tympanomeatal flap is elevated similar to the medial graft technique, a horizontal incision is made in the anterior canal skin with a curved round knife. The distance of the anterior-horizontal canal incision from the anterior annulus should be about the same or slightly longer than the diameter of the perforation. After the incision, the anterior canal skin is elevated (Fig. 1-2), then canalplasty is performed by drilling the anterior bony overhang with diamond burrs while using a suction irrigator until a full view of the anterior annulus is possible. The antero-medial canal skin flap is elevated up to the annulus or margin of the TM. At the annulus, only the squamous epithelial layer of the TM is carefully elevated to the anterior half of the perforation edge, leaving the anterior annulus intact. The middle ear cavity is packed with Gelfoam soaked in non-ototoxic antibiotic (usually fluoroquinolone) otic drops. Unlike in the case of usual medial graft technique, the middle ear packing does not have to be tight because the graft is supported by the intact annulus. In medial graft tympanoplasty, since the temporalis fascia is grafted medially in relation to the manubrium of the malleus and under the TM perforation and annulus, packing in the middle ear has to be tight to support graft and to prevent fascia fall-away. In medio-lateral tympanoplasty, the temporalis fascia is grafted medially for the posterior half of the perforation and is grafted laterally over the remnant de-epithelialized TM and annulus for the anterior half of the perforation (Fig. 1-3). To avoid anterior blunting, the fascia graft is brought only to the anterior sulcus on the annulus not passing beyond the anterior annular sulcus. As a second layer of closure, antero-medial canal



*Fig. 1.* Surgical steps of medio-lateral graft tympanoplasty for anterior or subtotal TM perforation. (1) A posterior tympanomeatal flap is elevated and ossicles are evaluated. (2) Antero-medial canal skin is elevated along with epithelial layer of TM up to anterior half of the perforation. (3) The temporalis fascia or perichondrium is placed medially (underlay) posterior half of the perforation and laterally (overlay) anterior half of the perforation up to the annulus. (4) Antero-medial canal skin is rotated as a superiorly based flap to cover perforation and fascia or perichondrium graft as a second layer. If necessary, posterior canal skin can be rotated and cover posterior part of graft and perforation especially for the subtotal TM perforation.

skin is rotated to cover perforation and fascia as a superiorly based flap (Fig. 1-4). The antero-lateral canal skin is replaced, and packings are placed. Traditional rosebud packing is inserted by using otosilk strips with small to medium-sized cotton ball inside, soaked in the antibiotic otic drops. The rest of the ear canal is packed with a gauze strip soaked in antibiotic ointment or Xerofoam gauze. The incision site is closed in the usual manner.

### 3. Discussion

Over the years, various techniques have been attempted to improve tympanoplasty results. These include overlay tympanoplasty,<sup>7</sup> underlay tympanoplasty,<sup>8</sup> Gelfilm sandwich tympanoplasty,<sup>9</sup> Crowncork tympanoplasty,<sup>10</sup> swinging-door tympanoplasty,<sup>12</sup> and the palisade cartilage technique.<sup>13</sup> Among them, underlay and overlay techniques are most commonly used. The advantages of medial (underlay) graft include ease of learning the technique, avoidance of the risk of lateralization and blunting of the anterior sulcus, and a high success rate, especially for the posterior perforation. The disadvantages of medial graft are poor visualization of the anterior tympanum, possible anterior graft fall-away when used for anterior perforation, reduction of middle ear space with consequently increased risk of adhesions, and less suitability for reconstruction of anterior TM perforation.<sup>1,2</sup> The lateral (overlay) graft provides superior exposure, suitable for all perforations, and minimizes reduction of the middle ear space. This technique has a high success rate and has been particularly effective for large or anterior perforations. The disadvantages of lateral graft include anterior blunting, possible lateralization of graft especially with absent malleus, tendency to create more epithelial pearls, need for malleus manipulation, longer healing time, increased operation time, and complexity for repair of small posterior perforations.

One of the most serious complications of the overlay graft techniques is lateralization of graft. Lateralization of TM is a condition in which the visible surface of the TM is located to either at the bony annular ring or lateral to it and loses contact with the conducting mechanism of the middle ear. Lateralization of TM may be associated with considerable morbidity, including hearing loss and cholesteatoma. Surgical repair is often necessary for significant underlying disease, but re-establishment of a normal TM can be challenging.<sup>12</sup> Medio-lateral graft tympanoplasty avoids lateralization of the graft by placing fascia medially to the posterior half of the TM and perforation, as well as the manubrium of malleus, and laterally to the anterior half of the perforation to prevent lateralization. In our study, there was no lateralization of graft or reconstructed TM.<sup>3,4</sup>

The medio-lateral graft tympanoplasty is a hybrid between medial and lateral graft methods taking advantages of both methods. It has many advantages over traditional medial or lateral graft: (1) prevention of anterior fall-away of fascia; (2) stability of the graft, like 'a button in a button hole'; (3) no need for tight Gelfoam packing to support the graft; (4) prevention of lateralization of graft; (5) better blood supply and faster healing because anterior canal skin is rotated as a rotational flap rather than free graft; (6) easier because the epithelial layer of only the anterior half of the TM remnant is elevated rather than the entire TM; and (7) less malleus manipulation.

### 5. Conclusion

The medio-lateral graft method has been developed and used for reconstruction of the large anterior or subtotal TM perforation. The success rate is high (97%) since it takes advantages of both the medial and lateral grafting methods while avoiding their pitfalls.<sup>4</sup> This method should help otologic surgeons to improve outcome of tympanoplasty for anterior or subtotal TM perforation.

## References

1. Rizer F. Overlay versus underlay tympanoplasty. Part I: historical review of the literature; Part II: the study. *Laryngoscope* 1997;107:1-36.
2. Wehrs R. Grafting techniques. *Otolaryngol Clin North Am* 1999;32(3):443-455.
3. Jung T, Park S. Mediolateral graft tympanoplasty for anterior or subtotal tympanic membrane perforation. *Otolaryngol Head Neck Surg* 2005;132:532-536.
4. Jung T, Kim Youhyun, Kim Yoonhwan, Park S, Martin D. Medial or medio-lateral graft tympanoplasty for repair of tympanic membrane perforation. *International J Ped Otorhinolaryngol* 2009;73:941-943.
5. Applebaum E, Deutsch E. An endoscopic method of tympanic membrane fluorescein angiography. *Ann Otol Rhinol Laryngol* 1986;95:439-443.
6. Schraff S, Dash N, Strasnick B. "Window shade" tympanoplasty for anterior marginal perforations. *Laryngoscope* 2005;115:1655-1659.
7. House W. Myringoplasty. *Arch Otolaryngol* 1960;71:399-404.
8. Shea J. Vein graft closure of eardrum perforation. *J Laryngol Otol* 1960;74:358-362.
9. Karlan M. Gelatin film sandwich in tympanoplasty. *Otolaryngol Head Neck Surg* 1979;87:84-86.
10. Harwein J, Leuwer R, Kehrl W. The total reconstruction of the tympanic membrane by the Crowncork technique. *Am J Otolaryngol* 1992;13:172-175.
11. Schwaber M. Postauricular undersurface tympanic membrane grafting: some modification of the "swinging door" technique. *Otolaryngol Head Neck Surg* 1986;95:182-187.
12. Sperling N, Kay D. Diagnosis and management of the lateralized tympanic membrane. *Laryngoscope* 2000;110:1987-1993.
13. Neumann A, Schultz-Coulon H, Jahnke K. Type III tympanoplasty applying the palisade cartilage technique: a study of 61 cases. *Otol Neurotol* 2003;24:33-37.

# OVERVIEW OF BIOFILMS AND OTITIS

Romain Kania<sup>1,2</sup>

<sup>1</sup>Head & Neck Surgery, Lariboisière University Hospital, Paris, France; <sup>2</sup>Paris Diderot University, University Paris Sorbonne Cité

Biofilms are composed of communities of bacteria which are encased in a glycocalyx mainly composed of exopolysaccharides and water. They form by adherence of some planktonic bacteria on a surface. Based upon quorum sensing, *i.e.*, exchange of information between bacteria, the formation of glycocalyx can start from these colonies of bacteria and become a biofilm.

Biofilms are ubiquitous. In medicine, the main problem generated by biofilms is resistance against the host and the antibiotics. Bacteria organized in biofilms can be up to 1000 times more resistant to antibiotics than the bacteria of the same species living in the state of free-swimming cells.

The presence of biofilms in otitis media has been demonstrated. Since the publication of the study by Hall-Stoodley *et al.*,<sup>1</sup> biofilms have been found in 92% of biopsies taken from the mucosa of 26 children with chronic otitis media (COM). Using the FISH technique, it has been found that bacteria found in those biofilms are mainly those which are found during acute otitis media: *Streptococcus pneumoniae*, *Haemophilus influenza*, *Moraxella catarrhalis*.

When addressing the presence of biofilms inside the middle ear cavity, Kania and Herman found the presence of biofilm in samples of effusion in children with serous otitis media.<sup>2</sup> This demonstration has been made using a double-staining technique which makes it possible to visualize both the bacteria and the glycocalyx encasing the bacteria. Whereas biofilms exist on the surface of an epithelium, the presence of biofilms in a middle ear cavity

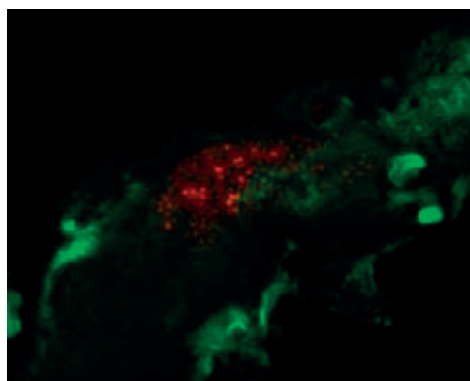


Fig. 1. Biofilm found into a sample of effusion of otitis media which was taken into the lumen of the middle ear.

question the way biofilm can form. Biofilms may use the scaffold of neutrophil extracellular traps (NETs) which are formed by activated neutrophils and consist of a DNA backbone embedded with antimicrobial peptides. Biofilms may exploit the release of NETs in the middle ear fluid to develop.

Thornton and coworkers found that bacteria in otitis are also capable of invading and persisting within cells.<sup>3</sup> Intracellular persistence may help explain the ineffectiveness of current treatment strategies *Streptococcus pneumoniae*, non-typeable *Haemophilus influenzae* (NTHi), *Moraxella catarrhalis*, *Pseudomonas aeruginosa* and *Staphylococcus aureus* were all found capable of intracellular persistence. Once inside the epithelial cells, bacteria are also protected against certain classes of antibiotics.

Therefore, when summarizing the different states by which bacteria may exist and persist in the middle ear, various mechanisms were listed and schematically represented by Coates and Thornton:<sup>4</sup> (a) mucosally associated multi-species biofilm; (b) single-species intracellular biofilm pods; (c) intercellular biofilm formations extending into the basal layer of cells; (d) multi-species biofilms associated with neutrophil extracellular traps in viscous middle ear effusion; (e) planktonic bacteria associated with neutrophil extracellular traps within the middle ear effusion.

Correspondence: Romain Kania, MD, Department of Otorhinolaryngology, Head & Neck Surgery, Lariboisière University Hospital, 2 rue Ambroise Paré, 75010 Paris, France.  
E-mail: romain.kania@gmail.com

*Cholesteatoma and Ear Surgery – An Update 2017, pp. 137 -138*

*Edited by Matthew Yung*

*2017 © Kugler Publications, Amsterdam, The Netherlands*

Of course, the presence of biofilms in otitis is not meaningless. Biofilms definitively play not only a role but likely many roles in otitis media. Bacterial biofilm can mask bacterial antigens and toxins. Bacterial biofilms can escape from certain types of host immune response by the mechanism of intracellular persistence. The enhancement of biofilm establishment can be the result of using NETs. Further research is needed to help understand the range of different roles in which biofilms are involved. Biofilms were also demonstrated in adenoids.<sup>5</sup> The existence of bacterial biofilms within adenoids may act as a reservoir for the persistence of otopathogens that can give rise to chronic otitis media.

Furthermore, bacterial biofilms were found to exist in cholesteatoma and in the mastoid of non-cholesteatomatous COM.<sup>6</sup> In cholesteatoma, bacterial biofilms were found within the matrix.

The understanding of the mechanisms involved in otitis media is determinant for the development of targeted treatments. The delivery of highly concentrated antibiotics in the middle ear is an interesting option. Reduction of the biomass of the human bacterial biofilm during mastoidectomy or adenoidectomy is very likely to interfere with the change of the presence and functions in which biofilms are involved in otitis media.<sup>7</sup>

## References

1. Hall-Stoodley L, Hu FZ, Gieseke A, et al. Direct detection of bacterial biofilms on the middle-ear mucosa of children with chronic otitis media. *JAMA* 2006;296(2):202-211.
2. Kania R, Herman, P. The middle ear: a gas pocket containing biofilms. In: Kania R, Ars B (eds.), *Biofilms in Otitis*, pp. 201-228. 1st ed. Amsterdam, The Netherlands: Kugler Publications 2015.
3. Thornton RB, Rigby PJ, Wiertsema SP, et al. Multi-species bacterial biofilm and intracellular infection in otitis media. *BMC Pediatr* 2011;11:94.
4. Thornton RB, Coates HL. Biofilms, intracellular bacteria and neutrophil extracellular traps in otitis media. In: Kania R, Ars B (eds.), *Biofilms in Otitis*, pp. 57-84. 1st ed. Amsterdam, The Netherlands: Kugler Publications 2015.
5. Kania RE, Lamers GE, Vonk MJ, et al. Characterization of mucosal biofilms on human adenoid tissues. *Laryngoscope* 2008;118(1):128-134.
6. Lampikoski H, Aarnisalo AA, Jero J, Kinnari TJ. Mastoid biofilm in chronic otitis media. *Otol Neurotol* 2012;33(5):785-788.
7. Belfield K, Bayston R, Birchall JP, Daniel M. Future perspectives in biofilm treatment in the middle ear. In: Kania R, Ars B (eds.), *Biofilms in Otitis*, pp. 333-362. 1st ed. Amsterdam, The Netherlands: Kugler Publications 2015.

# HEARING RECONSTRUCTION: HOW I DO IT. A STEP-BY-STEP OSSICULAR CHAIN RECONSTRUCTION

Romain Kania, Benjamin Verillaud, Philippe Herman

*Lariboisière University Hospital, Paris, France; Paris Diderot University, University Paris Sorbonne Cité*

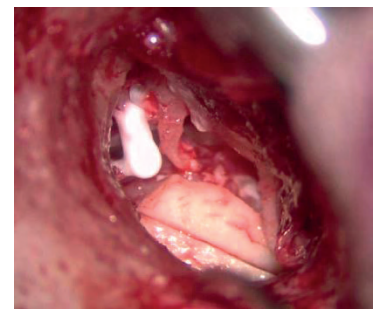
## 1. Introduction

Hearing reconstruction can be addressed in a four-steps strategy. The four steps that can cope with the vast majority of cases needing hearing reconstruction are:

- Bone cement;
- Incus interposition;
- Partial adjustable prosthesis;
- Total adjustable prosthesis.

## 2. Bone cement

Bone cement is good alternative for minimal bone gaps between the incus and the stapes with good hearing outcomes.<sup>1</sup> It is commonly seen in cases of lysis of the long process of the incus. Bone cement is commonly made intraoperatively by mixing a powder and a solution. Ossicular chain continuity can be easily restored by adding few drops of cement. Alternatively, a small piece of resorbable stich can be put to connect a more extended lysis of the incus to the stapes. Bone surfaces on which bone cement is added must be very dry to allow the cement to adhere to the bone surfaces. It is important to note that one should wait until the bone cement has hardened enough before testing mobility of the reconstruction (Fig. 1).



*Fig. 1. Bone cement used to restore continuity of the ossicular chain in a case of a lysis of the long process of the incus (right ear).*

## 3. Incus interposition

Incus interposition is the cheapest way of performing hearing reconstruction because only autologous material is used. Incus interposition is advocated any time there is a defect in the long process of the incus or any incus-stapedial luxation.<sup>2</sup> The aim of this ossicular chain reconstruction is to connect the malleus with the stapes. In most of the cases, incus interposition is realized by drilling the short process of the incus to get a flat surface which will be used to connect the stapes and the malleus. By drilling into the long process of the incus with a one-mm diamond burr in order to obtain a hole that will be able to encase the top of the stapes, incus interposition can be set. One must carefully drill the body of the incus in order to avoid any contact between the externa acoustic meatus and the incus interposition for optimal movement of the chain. The short process of the incus is connected to the malleus

Correspondence: Romain Kania, MD, Department of Otorhinolaryngology, Head & Neck Surgery, Lariboisière University Hospital, 2 rue Ambroise Paré, 75010 Paris, France.  
E-mail: romain.kania@gmail.com

*Cholesteatoma and Ear Surgery – An Update 2017, pp. 139 -142*

*Edited by Matthew Yung*

*2017 © Kugler Publications, Amsterdam, The Netherlands*



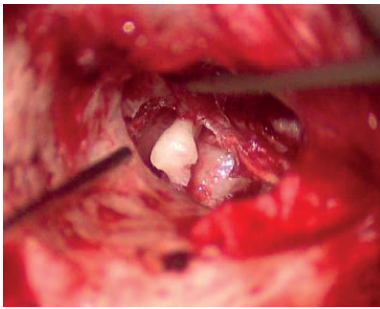


Fig. 2. Incus interposition (right ear).

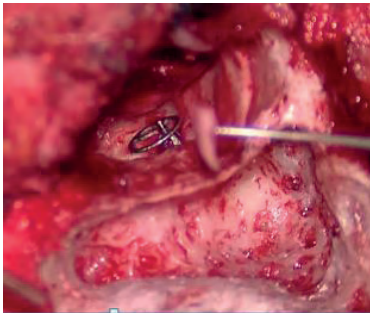


Fig. 3. Partial prosthesis placed on the stapes through the external auditory canal. The slice of cartilage is going to be interposed between the plateau of the prosthesis and the tympanic membrane (left ear).

either by putting the incus interposition below or above the umbo. When putting it above, the tympanic membrane must be a little bit elevated from the umbo. When putting it below, the surgeon should drill the short process of the incus with a small depression to encroach the umbo. Adding bone cement may be considered as a complementary procedure to seal the incus interposition.<sup>1</sup> Mobility of the chain should be checked before closure. There is no need of adding a piece of cartilage between the incus interposition and the tympanoplasty (Fig. 2).

#### 4. Partial adjustable prosthesis

Partial prosthesis aims at reconstructing the ossicular chain between the tympanic membrane and the stapes. Different types of prosthesis may be used.<sup>3</sup> Some of them are adjustable in height to adapt the reconstruction between the tympanic membrane and the stapes. A sham is first used in order to determine the height of reconstruction. One must consider that the partial prosthesis will be transmitting acoustic energy from the tympanic membrane to the stapes with a plateau that needs to be covered by a thin slice of cartilage. Therefore, the thickness of the cartilage covering the prosthesis' plateau should be considered in the height of the reconstruction. Once the height of the prosthesis is determined; the partial prosthesis is prepared with dedicated instruments and clipped on the stapes. The partial prosthesis could be inserted either through a

facial recess approach or through a transcanal approach (Fig. 3). A small and thin piece of cartilage is placed on the plateau to prevent any perforation of the partial prosthesis through the tympanic membrane. One of the advantages of the facial recess approach is the possibility to check the ossicular chain reconstruction once the dressing of the external acoustic meatus is done.

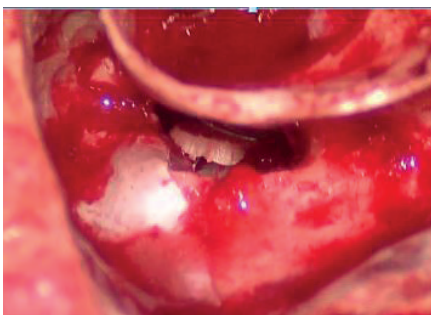


Fig. 4. Total prosthesis placed through a facial recess approach. Note the cartilage horse shoe used to stabilize the prosthesis into the oval window niche (right ear).

#### 5. Total adjustable prosthesis

Total adjustable prosthesis aims at reconstructing the ossicular chain between the tympanic membrane and the foot plate. The steps of reconstruction are similar to that of a partial prosthesis: calculation of the height needed for the shaft using one or various sham prosthesis, integration of the thickness of the cartilage covering the prosthesis plateau into the height of the prosthesis, insertion through facial recess approach or transcanal approach, coverage by the cartilage, checking of the mobility and dressing (Fig. 4). One issue of the positioning of the total prosthesis is how to avoid any displacement of the shaft of the prosthesis. Some resorbing biomaterial commonly used as dressing can fix the prosthesis,

or a small piece of cartilage over the oval window can be used as a horse shoe<sup>4</sup> or multiple small pieces of cartilage aggregated around the shaft of the prosthesis are able to assure stability of the total prosthesis.

## References

1. Somers T, Van Rompaey V, Claes G, et al. Ossicular reconstruction: hydroxyapatite bone cement versus incus remodelling: how to manage incudostapedial discontinuity. *Eur Arch Otorhinolaryngol* 2012;269(4):1095-1101.
2. O'Reilly RC, Cass SP, Hirsch BE, et al. Ossiculoplasty using incus interposition: hearing results and analysis of the middle ear risk index. *Otol Neurotol* 2005;26(5):853-858.
3. Neudert M, Zahnert T, Lasurashvili N, et al. Partial ossicular reconstruction: comparison of three different prostheses in clinical and experimental studies. *Otol Neurotol* 2009;30(3):332-338.
4. Kumar G, Andreou Z, Virk JS, Owa A. An innovative way of stabilising a titanium total ossicular replacement prosthesis. *Ann R Coll Surg Engl* 2014;96(8):625.



# REGULATION OF OSTEOCLASTS IS REQUIRED TO MAINTAIN MORPHOLOGY AND FUNCTION OF OSSICLES IN MIDDLE EAR; CLINICAL IMPLICATION OF CHOLESTATOMA

Sho Kanzaki<sup>1</sup>, Kaoru Ogawa<sup>1</sup>, Koichi Matsuo<sup>2</sup>

<sup>1</sup>Department of Otolaryngology Head and Neck Surgery; <sup>2</sup>Laboratory of Cell and Tissue Biology, School of Medicine, Keio University, 35 Shinanomachi, Shinjuku-ku, Tokyo

## Abstract

Recent studies clarified by using an osteoporosis animal model how osteoclasts play a role in the vibration of auditory ossicles. This review summaries that the morphological change of auditory ossicles and hearing function when osteoclasts decrease. It is still controversial issue whether the osteoclasts are involved in cholesteatoma. Prevention of bone resorption may be implicated with clinical application of middle-ear diseases including cholesteatoma.

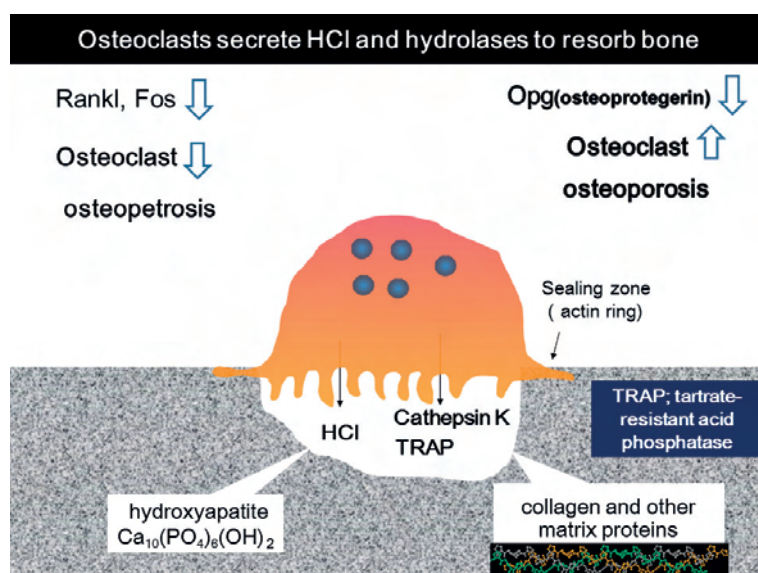


Fig. 1. Osteoclasts are multinucleated macrophages that resorb bone by secretion of proteases and hydrochloric acid. Bone is a composite material made of (1) Hydroxyapatite/an inorganic mineral composed of calcium phosphate and water/rigid material; (2) Collagen/the organic part of the bone/flexible.

## 1. Introduction

Bone remodeling is maintained by a balance in activity between bone-resorbing osteoclasts and bone-forming osteoblasts. Osteoclasts are specialized multinuclear macrophages that secrete HCL and hydrolases causing bone resorption. Osteoclasts are upregulated after inflammation, and ossicles are eroded by repeated otitis media. Therefore, regulation of the number of osteoclasts is critical for maintaining the shape and size of auditory ossicles. For bone remodeling to occur, receptor activator of nuclear factor- $\kappa\text{B}$  (NF- $\kappa\text{B}$ ) ligand (RANKL) must bind with its receptor (RANK), located on osteoclasts. The potentially continuous bone loss is mitigated by the decoy receptor osteoprotegerin (OPG) which competitively binds RANKL and

blocks the interaction of RANKL-RANK. The osteoclastic bone resorption in adults is balanced by osteoblastic bone formation through 'coupling' mechanisms, which maintain bone integrity (bone remodeling) (Fig.1).<sup>1</sup>

We reviewed the role of osteoclasts in the maintenance of the ossicular structure and how hearing function is impaired in knock-out mice with increased or decreased osteoclast numbers.

Correspondence: Sho Kanzaki MD PhD, department of otorhinolaryngology Head and Neck Surgery, School of Medicine, Keio University, 2 Chome-15-45 Mita, Minato-ku, Tōkyō-to 108-8345, Japan.  
E-mail: skan@keio.jp

*Cholesteatoma and Ear Surgery – An Update 2017*, pp. 143 -146

Edited by Matthew Yung

2017 © Kugler Publications, Amsterdam, The Netherlands

## 2. Excessive numbers of osteoclasts in ossicles

The shape of ossicles and hearing were also degraded when the numbers of osteoclasts were increased. Mice lacking OPG (*Opg*<sup>-/-</sup>mice), also known as a model for juvenile Paget's disease, exhibited excessive numbers of osteoclasts resulting in abnormal bone remodeling of the otic capsule.<sup>2,3</sup> Auditory ossicles in *Opg*<sup>-/-</sup>mice are massively resorbed by the abundant osteoclasts which may also result in impaired hearing function. In *Opg*<sup>-/-</sup>mice, the ligament at the junction of the stapes and the otic capsule is lost by bony ankylosis (fusion).<sup>2,3</sup>

## 3. Bisphosphonate therapy in otosclerosis

*Opg*<sup>-/-</sup>mice were intraperitoneally injected with risedronate, one of the widely-used bisphosphonates, for five days/week over nine weeks. The treatment significantly inhibited bone loss in auditory ossicles as well as in long bones of *Opg*<sup>-/-</sup>mice compared to untreated control mice.<sup>4</sup> Thinning of the malleus handle and bony fusion of the junction between the stapes and the otic capsule were reduced by the treatment. In addition, hearing loss in *Opg*<sup>-/-</sup>mice was significantly reduced by risedronate treatment.<sup>4</sup>

## 4. Controversial on osteoclasts involving in cholesteatoma

Bone destruction caused by cholesteatoma in the middle ear. A few studies reported a model for inducing cholesteatoma osteoclastogenesis in mice. This study demonstrated that intercellular communication between keratinocytes and fibroblasts is involved in the differentiation and function of osteoclasts.<sup>5</sup> Triggering receptor expressed on myeloid cells (TREM)-2 might enhance acquired cholesteatoma-induced bone destruction by amplifying the inflammatory response via TLR4 signaling pathways and promoting MMP secretion and osteoclast activation.<sup>6,7</sup> On the other hand, the expression of RANK and RANKL was significantly lower in the cholesteatomatous bone powder than in the non-cholesteatomatous bone powder. The RANKL mRNA/OPG mRNA ratio did not differ among the three samples. These results indicate that osteoclasts are unlikely to be activated in cholesteatomas in patients.<sup>8</sup> We speculate osteoclasts are expressed in limited time in cholesteatoma and middle ear diseases. The further studies of osteoclast biology in cholesteatoma are necessary.

## 5. Conclusions

We have shown that osteoporosis impacts the structure of the middle-ear ossicles and impairs the hearing function. The osteoporotic animal model can provide us with information on how osteoclasts play a role in the middle ear function and morphology. There is still controversy concerning how osteoclasts involve in cholesteatoma.

## Acknowledgements

This work was supported by Grants-in-Aid for Young Scientists B (17791198, 21791643 to S.K.), for Scientific Research C (23592495 to S.K.), and Grants-in-Aid for Scientific Research B (17390420 and 21390425 to K.M.) from JSPS; and a Keio University Special Grant-in-Aid for Innovative Collaborative Research Projects.

## References

1. Zhao C, Irie N, Takada Y, et al. Bidirectional ephrinB2-EphB4 signaling controls bone homeostasis. *Cell Metab* 2006;4:111-121.
2. Kanzaki S, Ito M, Takada Y, Ogawa K, Matsuo K. Resorption of auditory ossicles and hearing loss in mice lacking osteoprotegerin. *Bone* 2006;39:414-419. Kanzaki S, Takada Y, Niida S, et al. Impaired vibration of auditory ossicles in osteopetrotic mice. *Am J Pathol* 2011;178:1270-1278.
3. Zehnder AF, Kristiansen AG, Adams JC, et al. Osteoprotegerin knockout mice demonstrate abnormal remodeling of the otic capsule and progressive hearing loss. *Laryngoscope* 2006;116:201-206.
4. Kanzaki S, Takada Y, Ogawa K, Matsuo K. Bisphosphonate therapy ameliorates hearing loss in mice lacking osteoprotegerin. *J Bone Miner Res* 2009;24:43-49.
5. Iwamoto Y, Nishikawa K, Imai R, et al. Intercellular Communication between Keratinocytes and Fibroblasts Induces Local Osteoclast Differentiation: a Mechanism Underlying Cholesteatoma-Induced Bone Destruction. *Mol Cell Biol* 2016;36(11):1610-1620.
6. Jiang H, Si Y, Li Z, et al. TREM-2 promotes acquired cholesteatoma-induced bone destruction by modulating TLR4 signaling pathway and osteoclasts activation. *Sci Rep* 2016;6 (e-pub ahead of publication).
7. Si Y, Chen YB, Chen SJ, et al. TLR4 drives the pathogenesis of acquired cholesteatoma by promoting local inflammation and bone destruction. *Sci Rep* 2015:16683.
8. Koizumi H, Suzuki H, Ikezaki S, et al. Osteoclasts are not activated in middle ear cholesteatoma. *J Bone Miner Metab* 2016;34(2):193-200.





# WHERE IS IT SAFE TO LEAVE RESIDUAL VESTIBULAR SCHWANNOMA DURING SURGERY?

Anand V. Kasbekar<sup>1,2</sup>, Guleed H Adan<sup>2</sup>, Alaina Beacall<sup>2</sup>, Ahmed M. Youssef<sup>2,3</sup>, Catherine E. Gilkes<sup>4</sup>, Tristram H. Lesser<sup>2</sup>

<sup>1</sup>Department of Otorhinolaryngology, Nottingham University Hospitals, Nottingham, UK; <sup>2</sup>Department of Otolaryngology, Head & Neck Surgery, Aintree University Hospital, Liverpool, UK; <sup>3</sup>Ain Shams University, Cairo, Egypt; <sup>4</sup>Department of Neurosurgery, The Walton Centre, Liverpool, UK

## 1. Introduction

There has been a trend towards leaving more tumor behind on the facial nerve and on other vital intracranial structures in order to improve functional outcomes during vestibular schwannoma (VS) surgery. The location of these tumor fragments, however, and how this predisposes to regrowth has not been adequately investigated.

In the Liverpool Skull Base Unit we followed the trend to leave more tumor behind to preserve function and this paper reviews the time when this was practiced to a greater degree than it currently is. We aimed to examine our residual VS preoperatively from growing tumors and ascertain a pattern of growth from a time when we left behind larger VS residual than we would do currently. The primary questions we wanted to answer were: (a) is there was any correlation between the risk of regrowth and the amount of tumor left behind at surgery?; and (b) is there a difference in growth risk depending on where residual tumor is left behind?

## 2. Methods

A retrospective review of case notes and magnetic resonance (MR) scans was undertaken of patients treated between 2006 and 2009 with medium- to large-sized sporadic VS who had not had prior active treatment. These we defined as tumors greater than or equal to 20 mm in maximum intracranial diameter. Only growing tumors that underwent surgery were included in the study. Patients who underwent surgery were identified from the operating theatre database.

The extent of tumor excision varied between patients. Two groups were identified from the operative notes; over 95% of tumor excision and less than 95% of tumor. This can be defined as subtotal or near total excision,<sup>1-3</sup> however, as there is no internationally accepted definition of these terms we report the size of tumor left behind, *i.e.*, more or less than 5%.

The MR scans were studied to document the size of the VS remnant and also the location within the internal acoustic canal (IAC) and/or the cerebellopontine angle (CPA). Measurement methods conformed to those proposed by Kanzaki *et al.* at the 2003-consensus meeting on VS reporting.<sup>4</sup> Residual tumor size was recorded at four sites (CPA, porus, meatus, fundus). The time taken from surgery to last MR measurement of the residual tumor was used to calculate the rate of any growth in mm per year.

Correspondence: Anand V. Kasbekar, Consultant ENT Surgeon & Neurotologist, Department of Otolaryngology, Head & Neck Surgery, Nottingham University Hospitals, NHS Trust, Queen's Medical Centre, Nottingham NG7 2UH, UK.  
E-mail: Anand.kasbekar@nhs.net

*Cholesteatoma and Ear Surgery – An Update 2017, pp. 147 -150*

*Edited by Matthew Yung*

*2017 © Kugler Publications, Amsterdam, The Netherlands*

*Table 1.* Table showing the proportion of growing and non-growing residual VS in relation to the extent of primary tumor resection. Chi<sup>2</sup> testing was significant at  $p < 0.01$ , indicating a greater risk of residuum growth with sub-total excision.

	More than 95% excision	Less than 95% excision	Total
Non-growing residual tumours	16	16	32
Growing residual tumours	4	16	20

*Table 2.* Demonstrating the four locations VS remnant could be left behind. Forty-seven cases had multiple sites of residual tumor and therefore the total number of residua are greater than 52. One tumor could have residuum at all four locations. The median rate of growth at each site calculated as mm per year (mm/year) is also provided. Fisher's exact test showed that there was no difference in the risk of growth comparing all four sites ( $p = 0.09$ ).

Site of residual VS	Non-growing	Growing	Number of residua at each site	Median growth rate mm/year
CPA	27	21 (44%)	48	2 mm (1-7)
Porus	36	11 (23%)	47	2 mm (1-3)
Meatus	28	14 (33%)	42	1 mm (1-3)
Fundus	12	2 (14%)	14	1 mm

### 3. Results

Between 2006 and 2009, 52 medium and large growing sporadic VS had primary surgical treatment and had visible tumor left at surgery or on postoperative MR scan. The average preoperative size was 27 mm (range 20-42 mm). The surgical approach comprised of 45 cases via the retrosigmoid route and seven via the translabrynthine route. Of the 52 residual VS, 20 grew (38%). See Table 1 for a breakdown of less or greater than 5% excision and growth of residual tumor. Growing residual tumors were compared between the two groups and Chi<sup>2</sup> testing was significant at  $p < 0.01$  indicating a greater risk of residual tumor growth with less than 95% excision. All patients underwent postoperative MR scanning. Follow-up of patients ranged from 4.5 to 8.1 years (mean 6.4 years). Time to growth varied from one year to 5.5 years (mean 2.8 years). Overall, 17 of the 20 growing residual tumors required retreatment.

Table 2 demonstrates the four locations VS remnants were left behind. Most (47/52) cases had multiple sites of residual tumor and therefore one tumor may have residual tumor at all four sites. Table 2 also provides the median rate of growth at each site calculated in mm per year (mm/year). Fisher's exact test showed that there was no difference comparing all four sites for residual regrowth ( $p=0.09$ ). There was also no significant difference in the growth behaviour of tumour within the IAC as a whole (porus, meatus and fundus) and the CPA. ( $p=0.158$ , Chi<sup>2</sup> test). Residual tumour at the fundus did show a lower percentage of regrowth rate although the numbers were too small to perform statistical analysis on.

### 4. Discussion

The difference in our regrowth rates between less than and greater than 95% resections was statistically significant ( $p < 0.01$ ), and is similar to those results previously documented in the literature.<sup>5-7</sup> We found preoperative VS size to be significant for growth of a residual tumor. For every one mm increase in preoperative VS size, there was an 11% increase in odds of the residual VS growing if tumor was left behind at surgery. Our findings add to

the compelling body of evidence that the size of a tumor being operated on has direct consequences on whether residual tumor will regrow. Our data shows that growth can occur 5.5 years after surgery and therefore an adequate follow-up period is essential.

The distribution of residual tumor left behind at surgery illustrate that the majority are at the CPA (92%), along the brainstem where the tumor is likely to be adherent to critical structures. 90% of cases had tumor at more than one site.

Although there have been reports that tumour remnants in the IAC are less likely to grow, the data is limited.<sup>5</sup> Table 2 displays in our series whether residual VS was growing or not at a particular site and also the rate of residual VS growth in mm/year. This did not show any difference in growth rate in relation to residual tumour site. The fundus showed the lowest growth rate at 14% but the number of tumours studied were too small to base conclusions on. The rate of expansion however in growing residual tumour suggests that CPA fragments are more likely to grow at a faster rate compared to the meatus and fundus (2mm/year versus 1mm/year). This difference in growth rate is not significant given the number of cases we have included in our study and we acknowledge that there are other factors that may limit the growth within the IAC.

We have demonstrated high (50%) growth rates in residual tumours following subtotal resection which are significantly reduced by a more aggressive resection. We would advocate that the aim of surgery should remain as complete a resection as possible with preservation of the facial nerve. Patients with residual VS following surgery should be monitored closely for an indefinite period of time. The size of the tumour should be borne in mind when deciding on the surgical strategy and potential post-operative treatment in patients with growing tumours. Our data shows that tumour growth occurs at all sites and that the preoperative size of the tumour positively influences whether residual tumour fragments grow. There is a need for standardized reporting of residual tumor outcomes, which will allow accurate comparison, and pooling of data.

## References

1. Angeli RD, Piccirillo E, Di Trapani G, et al. Enlarged translabyrinthine approach with transapical extension in the management of giant vestibular schwannomas: personal experience and review of literature. *Otol Neurotol* 2011;32(1):125-131.
2. Zhao X, Wang Z, Ji Y, et al. Long-term facial nerve function evaluation following surgery for large acoustic neuromas via retrosigmoid transmeatal approach. *Acta Neurochir (Wien)* 2010;152(10):1647-1652.
3. Lalwani AK, Butt FY, Jackler RK, Pitts LH, Yingling CD. Facial nerve outcome after acoustic neuroma surgery: a study from the era of cranial nerve monitoring. *Otolaryngol Head Neck Surg* 1994;111(5):561-570.
4. Kanzaki J, Tos M, Sanna M, et al. New and modified reporting systems from the consensus meeting on systems for reporting results in vestibular schwannoma. *Otol Neurotol* 2003;24(4):642-648.
5. Bloch DC, Oghalai JS, Jackler RK, Osofsky M, Pitts LH. The fate of the tumor remnant after less-than-complete acoustic neuroma resection. *Otolaryngol Head Neck Surg* 2004;130(1):104-112.
6. Monfared A, Corrales E, Theodosopoulos P, et al. Facial Nerve Outcome and Tumor Control Rate as a Function of Degree of Resection in Treatment of Large Acoustic Neuromas: Preliminary Report of the Acoustic Neuroma Subtotal Resection Study. *Neurosurgery* 2016;79(2):194-203.
7. Spielmann PM, Sillars H. Assessing the threshold for vestibular schwannoma resection and the behavior of residual tumor. *Otol Neurotol* 2013;34(5):935-938.



# BONY OBLITERATION TECHNIQUE (BOT) SURGERY IN PAEDIATRIC CHOLESTEATOMA CASES

Gabor Katona

*Heim Pál Children's Hospital, Budapest, Hungary*

## 1. Introduction and Methods

Paediatric cholesteatoma is an aggressive, destructive disease to all surrounding tissues. It has a high recurrence tendency even after careful removal. The complication rate is high, severe, sometimes life-threatening complications can occur. Hearing deterioration is characteristic. Main goals of therapy are:

- Complete eradication of the disease (no residual disease);
- Prevention of recurrent disease, prevention of complications;
- Improvement of the hygienic status of the ear;
- Preservation or improvement of hearing.

The classic operations are the canal-wall-up (CWU) and the canal-wall-down (CWD) techniques. CWU has the advantage of providing preservation of the anatomical structures, close to the physiological status, ideally providing a waterproof, dry, good hearing ear. There are some drawbacks in this method: less visualization during the operation, a high residual and recurrence rate, and usability in only small, mesotympanal and/or epitympanal cases. CWD's advantages are the good visualization, accessibility of the whole middle ear cleft, with large meatoplasty it gives a safe ear, and protection against intracranial complications. Disadvantages are that the ear is not waterproof, discharge is frequent, and hearing results are poor. Formerly, operations were performed mostly in two sessions: about one year after the first operation – enough time to grow a 'spider-egg', residual disease could be removed and reconstruction could be carried out.

Today, the method of choice in cases of invagination cholesteatoma is CWU/CWD with BOT, with a complete removal of the matrix and keratin and primary reconstruction of the ear. This method combines the advantages of both other methods, avoiding their disadvantages. In careful and extensive surgery (removal of cholesteatoma from the whole middle ear cleft and reconstruction with bone pâté and mid-temporal pericranial and inferiorly based periosteal flaps) the second look could be avoided. This method is especially recommended in ears with bad aeration. The obliteration adjusts the gas exchange mucosal surface to the less pressure equilibration capacity of the Eustachian tube. For control of recurrent/residual cholesteatoma, non-epi DW MRI is recommended.

## 2. Results

In the last five years, we had 53 cholesteatoma cases, four congenital, 49 epitympanic and invagination-type. In the first two years, two-stage surgeries with secondary reconstruction and without obliteration have been done, in the last three years the BOT surgery has been introduced. In non-obliteration cases (n = 32) the recurrent/residual rate was 37.5% (12), in obliteration cases (n = 17) it was 5.9% (one). Hearing results in the obliteration group were better than in the non-obliteration group (average ABG improvement was 5.3 dB vs 12.5 dB).

Correspondence: Gabor Katona, MD, PhD. Gabor Katona, Heim Pál Children's Hospital, Üllői u. 86.; 1089 Budapest, Hungary.  
E-mail: katonagbor@gmail.com.

*Cholesteatoma and Ear Surgery – An Update 2017, pp. 151 -152*

*Edited by Matthew Yung*

*2017 © Kugler Publications, Amsterdam, The Netherlands*



### **3. Conclusion**

After a learning curve, BOT surgery seems to be the method of choice in paediatric invagination cholesteatoma cases.

# ENDOSCOPIC MANAGEMENT OF CHOLESTEATOMA WITH KHAN'S ENDOHOLDER

Department Of Otorhinolaryngology, M.I.M.E.R. Medical College, Pune, India

*Department of Otorhinolaryngology – East Avenue Medical Center; <sup>6</sup>Department of Otorhinolaryngology – St Luke's Global Medical Center; <sup>7</sup>Department of Otorhinolaryngology – University of Santo Tomas Faculty of Medicine and Surgery*

## Abstract

We describe our technique of two-handed endoscopic cholesteatoma surgery with Justtach®. along with the design of the Endoholder; Justtach®.

*Materials & Methods:* One hundred twenty-nine consecutive two-handed endoscopic cholesteatoma surgeries with Khan's Endoholder operated with the inside-out technique were included in the study.

*Results:* The preoperative air bone gap was  $35.68 \pm 5.69$  dB and the postoperative air bone gap at one and two years was  $15.14 \pm 5.27$  dB and  $16.76 \pm 5.39$  dB respectively.

*Conclusion:* Justtach® is a good option for two-handed endoscopic cholesteatoma surgery.

## 1. Introduction

The transcanal endoscopic approach provides a new way of looking at the anatomy of the tympanic cavity and more specifically at cholesteatoma-bearing areas. The endoscope allows a better understanding of ligaments and folds and ventilation of the middle ear. The panoramic view offered by the endoscope allows seeing all around the corners of the middle ear. Endoscope in cholesteatoma surgery allows a transcanal approach, functional reconstruction and minimal bone removal while preserving as much of the bone with access to hidden sites (sinus tympani, the anterior epitympanic space, and the protympanic space) in order to perform cholesteatoma surgery successfully. It reduces the extent of surgical invasion and it widens the scope of treatment.<sup>1-3</sup>

The only disadvantage of endoscopic ear surgery is the one-handed surgical technique, as the non-dominant hand of the surgeon is used to hold the endoscope. This problem is more evident during haemorrhage and drilling, as it becomes difficult to use suction and instruments both along with the endoscope. Even during fogging, one needs to remove the endoscope again and again for lens cleaning.<sup>4-6</sup>

This created the need for the development of an endoscope holder which would allow both hands of the surgeon to be free for surgical manipulation and also allow alternate use of the microscope during endoscopic ear surgery.<sup>4</sup> Surgical microscopes have an adequate range and they enable the surgeon to focus on the desired object for magnification. This can be applied for driving the endoscope smoothly in any biological cavities once an endoscope-holding attachment is fixed to the optical system of any surgical microscope (Patent Application No. 3300-mum-2014).<sup>4</sup>

The purpose of this study was to report our experience with two-handed endoscopic cholesteatoma surgery with our Endoscope Holder: Justtach®.

Correspondence: Dr. Mubarak M Khan, Department Of Otorhinolaryngology, M.I.M.E.R. Medical College, Pune, INDIA – 410507.  
E-mail: drmubarakkhan@yahoo.co.in, ent.khan@gmail.com, www.drkhan.in

*Cholesteatoma and Ear Surgery – An Update 2017, pp. 153 -156*

*Edited by Matthew Yung*

*2017 © Kugler Publications, Amsterdam, The Netherlands*

## 2. Methods and Materials

### 2.1. Design of Justtach®

Justtach® is a metallic plate of 170 x 70 x 12 mm with a circular slot measuring 16 x 16 mm in diameter and a square slot to hold a rigid endoscope. It can be affixed to the optical system of any operating ENT microscope with tightening screws.<sup>4</sup>

### 2.2. Procedure of endoscopic two-handed cholesteatoma surgery with Justtach®

After all aseptic precautions, Justtach® (Fig. 1) is fixed onto the microscope. The endoscope with the camera is then mounted on the Endoholder. A transcanal incision is made. Tragal cartilage is harvested and sliced<sup>7,8</sup> with Khan's Slice !t® (Dr. Khan's Creations, India). The tympanomeatal flap is elevated. The disease is approached with the inside-out mastoidectomy technique. Simultaneous drilling and suctioning is possible as the endoscope is fixed onto the Endoholder (Fig. 2). During the procedure, the suction device is held in the left hand to avoid fogging and also to achieve cooling of the endoscope. Intermittent irrigation is done for cooling of the endoscope and cleaning of the endoscope lens. In this technique, the disease is followed from where the disease starts by atticoantrostomy and ventilation blocks are removed. The bone is drilled and the end of the cholesteatoma sac is followed. Then the bony wall defect is reconstructed with tragal cartilage.

A total of 129 cholesteatoma surgeries were performed with the two-handed endoscopic inside-out technique with Justtach® from November 2013 to June 2015, with a follow-up period ranging from 12 to 31 months. The patients ranged from eight to 59 years. There were 58 males and 71 females in the study group.

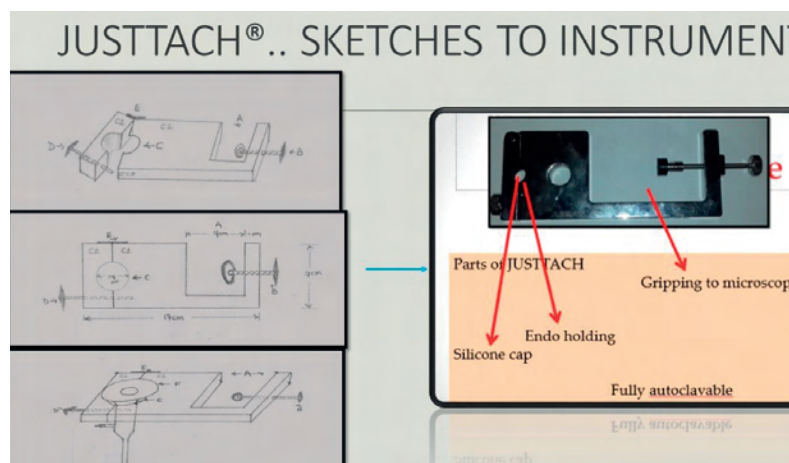


Fig 1. Justtach® and its parts.

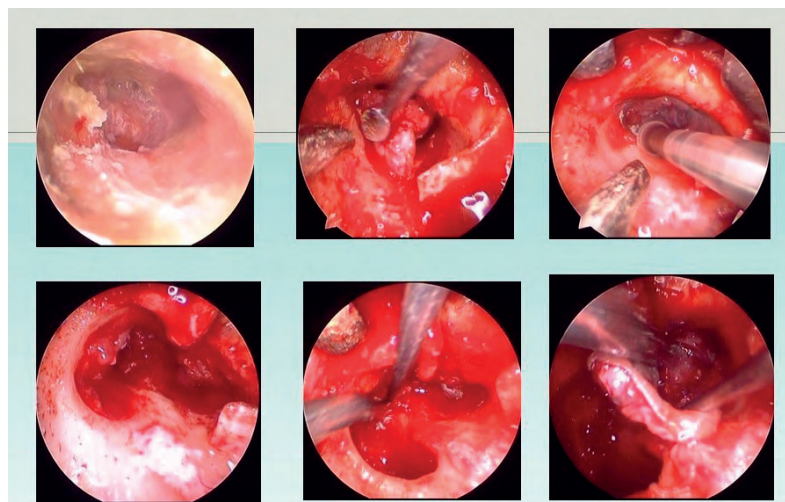


Fig. 2. Two-handed atticoantrostomy with Justtach®.

Table 1. Pre- and postoperative air bone gap.

Average preop AB Gap (dB)	Postop ABG 6 months (dB)	Postop ABG 1 year (dB)	Postop ABG 2 years (dB)
35.68 ± 5.69	15.65 ± 5.65	15.14 ± 5.27	16.76 ± 5.39

### 3. Results

A total of 129 consecutive cholesteatoma surgeries were performed with Justtach®. The preoperative air bone gap was 35.68 ± 5.69 dB and the postoperative air bone gap at one and two years was 15.14 ± 5.27 dB and 16.76 ± 5.39 dB respectively (Table 1).

### 4. Discussion

Although it has been more than two decades since endoscopy was first used to explore mastoid cavities, the endoscope is not used frequently for surgical management of ear disease.<sup>1-3</sup> At present, the scenario of the endoscopic ear surgery is a single-handed procedure with the endoscope held in the non-dominant hand of the surgeon and the instrumentation in the dominant hand.

#### 4.1. Is the endoscope holder needed in ear surgery?<sup>4-6</sup>

The answer is definitely yes. The use of the endoscope holder:

- Will allow the surgeon to use both hands for surgery;
- Will allow the surgeon to apply all movements (not functions) of the microscope optical body to endoscope movement;
- With our Endoscope Holders, the endoscope can be moved more or less like using the left hand which is important for any surgery;
- Every ENT surgeon uses a microscope for ear surgery. Now by using our Justtach®, he or she will be able to do endoscopic ear surgery with two hands (at present nobody in the world is doing this);
- All ENT surgeons are familiar with the two-handed technique of microscopic ear surgery, hence incorporating the skills of two-handed EES is not difficult.

We are in a transition phase and endoscopic ear surgery is still in an early stage.

#### 4.2. Advantages of Justtach®

- Both hands free for surgical manipulation;
- With angled endoscope (30, 45, 70 degrees) better visualization of sinus tympani and facial recess;
- Use is similar to microscope. All movements of the microscope stand can be used;
- The fine focus of the microscopic stand can be utilized for additional manipulation/advancing into the external auditory canal;
- Drilling and suctioning is possible simultaneously;
- Irrigation and suction is sufficient in cases of fogging or for lens cleaning without taking out the endoscope from the operative field;
- Stability of the endoscope, camera and image on the monitor is ensured throughout the surgery;
- Minimizes the need for assistance;
- No need to purchase the whole endoscope holder stand, thus economical;
- No surgeon fatigue;
- Lesser duration of the EES;
- Combined endo-microscopic work;
- Universal attachment to any microscope of any make.

#### 4.3. Problems with Justtach®

- System is bulkier (microscope + endoscope);
- Horizontal arm balancing;
- Chances of uncontrolled up-down movement;
- If a low-quality microscope is used, then the movements may be sluggish and rough;
- Optical system obstructs instrumentation.

With our technique of endoscopic cholesteatoma surgery, functional reconstruction and minimal bone removal while preserving as much of the normal anatomy as possible.

#### 5. Conclusion

Our endoscope holder is useful and economic device for two-handed endoscopic cholesteatoma surgery. It has a different learning curve and training is mandatory in endoscopic two-handed ear surgery to allow more familiarity and comfort with the technique.

#### References

1. Tarabichi M. Endoscopic management of cholesteatoma: long-term results. *Otolaryngology--Head and Neck Surgery* 2000;122(6):874-881.
2. Tarabichi M, Nogueira JF, Marchioni D, et al. Transcanal endoscopic management of cholesteatoma. *Otolaryngol Clin N Am* 2013;46(2):107-130.
3. Tarabichi, M. Endoscopic middle ear surgery. *Ann Otol Rhinol Laryngol* 1999;108(1):39-46.
4. Khan MM, Parab SR. Novel Concept of Attaching Endoscope Holder to Microscope for Two Handed Endoscopic Tympanoplasty. *Indian J Otolaryngol Head Neck Surg* 2016;68(2):230-240.
5. Khan MM, Parab SR. Concept, design and development of innovative endoscope holder system for endoscopic otolaryngological surgeries. *Indian J Otolaryngol Head Neck Surg* 2015;67(2):113-119.
6. Khan MM, Parab SR. Endoscopic cartilage tympanoplasty: A two-handed technique using an endoscope holder. *Laryngoscope* 2016;126(8):1893-1898.
7. Khan MM, Parab SR. Primary cartilage tympanoplasty: our technique and results. *Am J Otolaryngol* 2011;32(5):381-387.
8. Khan MM, Parab SR. Comparative study of Sliced Tragal Cartilage and Temporalis Fascia in type I Tympanoplasty. *J Laryngol Otol* 2015;129(1):16-22.

# **CURRENT TRENDS OF CHOLESTEATOMA SURGERY IN JAPAN: RESULTS FROM THE JAPAN OTOLOGICAL SOCIETY REGISTRY USING 2015 JOS STAGING AND CLASSIFICATION SYSTEM**

Manabu Komori, Tetsuya Tono, Masafumi Sakagami, Hiromi Kojima, Naohito Hato, Yutaka Yamamoto, Keiji Matsuda, Yuka Morita, Sho Hashimoto

*The Committee on Nomenclature of the Japan Otological Society*

The committee on Nomenclature of the Japan Otological Society (JOS) was appointed in 2004 to create a cholesteatoma staging system widely applicable in Japan and as simple as possible to use in a clinical practice. After the initial proposal of the principal staging system for attic cholesteatoma in 2008, we proposed a 2010-version of the staging system for two main types of acquired cholesteatoma; pars flaccida type and pars tensa type. Since then, this staging system has been widely used in Japan, allowing for more meaningful communication between outcome studies based on surgical methods used for a respective type and stage of cholesteatoma.

A nationwide survey was conducted by the Committee of JOS in order to promote the use of this system among JOS members and to capture the prevalence of cholesteatoma types and stages in Japan in 2015. The operative methods employed in each case were also included to reveal the current trends of cholesteatoma surgery in Japan. Medical information of the patients were anonymized and registered through the JOS website voluntarily between 1 January and 29 February 2016.

As of 31 March 2016, 1791 cases from 74 hospitals have been registered. Pars flaccida cholesteatoma: 1133 cases (65% of the total); pars tensa cholesteatoma: 233 cases; congenital cholesteatoma: 234 cases; cholesteatoma secondary to a chronic tensa perforation: 100 cases; unclassifiable cholesteatoma: 91 cases.

In Japan, canal-wall-down tympanoplasty with canal wall reconstruction is the most-used procedure (657 cases, 36.7%). Four hundred ninety-eight cases (27.8%) were canal-wall-up tympanoplasty, 453 cases (25.3%) were tympanoplasty without mastoidectomy, and 183 cases (10.2%) were canal-wall-down without canal wall reconstruction. Use of endoscope is 25% at this point, but it is expected to increase in the future. From the results of surgical planning, there were 524 cases (29.3%) of planned stage surgery. This is reviewed because early detection cases have increased.

Pars flaccida cholesteatoma: canal-wall-down tympanoplasty with canal wall reconstruction accounted for  $\pm$  40%, canal-wall-up tympanoplasty for 30% of the whole surgery.

Pars tensa cholesteatoma: because of increasing stage I, tympanoplasty without mastoidectomy accounted for  $\pm$  30%, canal-wall-down tympanoplasty with canal wall reconstruction for  $\pm$  35%, canal-wall-up tympanoplasty was  $\pm$  20% of the whole surgery.

Cholesteatoma secondary to a chronic tensa perforation (also the reason why cases of stage 1 often occur): tympanoplasty without mastoidectomy accounted for  $\pm$  70% and the majority.

Congenital cholesteatoma (stage 1 often occurs as well): tympanoplasty without mastoidectomy accounted for  $\pm$  55%; canal-wall-up tympanoplasty for  $\pm$  30%.

Now we better understand current trends of cholesteatoma surgery in Japan. We think it is important to carry out further multi-center studies to clarify the pathogenesis of cholesteatoma. And we are confident this will lead to better treatment and create a guideline for nationwide survey, such as postoperative recurrence rate and postoperative hearing results depending on the JOS Staging and Classification System.

Correspondence: : Manabu Komori, MD , 4-11-1, Izumihoncho, Komae-city, Tokyo, 201-8601, Japan.  
E-mail: m\_komori@jikei.ac.jp

*Cholesteatoma and Ear Surgery – An Update 2017, pp. 157 -158*

*Edited by Matthew Yung*

*2017 © Kugler Publications, Amsterdam, The Netherlands*





# MASTOID OBLITERATION SIX-YEARS FOLLOW-UP RESULTS. EUROPEAN TREND, LOCAL PECULIARITIES

Sergey Kosyakov, Ekaterina Pchelenok

*Russian Medical Academy of Continuous Professional Education, Moscow, Russia*

## Abstract

**Objective:** The canal-wall-down (CWD) mastoidectomy in cholesteatoma can secure a good operation field and easy removal of the lesion. However, there are some problems: the lifelong care of the cavity, dizziness due to the exposed semicircular canal, difficulty with the fitting of a hearing aid, as well as poor cosmetics. The canal-wall-up (CWU) technique has a better hygienic status and better functional outcome. This technique is associated with a higher rate of residual disease and a higher rate of recurrent disease.

**Material and Methods:** One hundred ninety-six patients were observed postoperatively. All patients underwent sanitation surgery with the obliteration of paratympanic spaces followed by the restoration of the posterior wall of the external auditory meatus and simultaneous tympanoplasty (closed-type surgery). The patients were examined one year after the treatment with the use of the MRI technology using the non-EPI DWI regime to monitor the residual and recurrence cholesteatoma.

**Results:** We analyzed the postoperative results from 196 patients. The follow-up observation revealed 14 cases of residual cholesteatoma. Recurrent cholesteatoma was not observed during the follow-up periods.

**Conclusion:** Long-term follow up indicated that the CWD technique with bony obliteration is a safe method with which to treat primary cases and to reconstruct unstable cavities. The MRI technology in the non-EPI DWI regime was successful in differentiating soft tissues and enabled the detection of residual or recurrent cholesteatoma after a CWD bony obliteration technique procedure.

## 1. Introduction

Cholesteatoma is accompanied by progressive growth and bone resorption structures of the middle ear.<sup>1,2</sup> The latest research in molecular biology shows how the cholesteatoma perimatrix influences the bone leading it to resorption. Osteoclasts and deterioration of extracellular matrix affect the bone matrix in this process.<sup>3,4</sup>

Residual cholesteatoma and recurrent cholesteatoma are specific problems, that reduce the surgical treatment efficacy. Today there are two main methods of cholesteatoma surgery: the closed technique (canal-wall-up (CWU)) and the open technique (canal-wall-down (CWD)). It should be noted that one of the stages of surgery intervention is the obliteration of paratympanic spaces, reconstruction of tympanic cavity and ossicular reconstruction.

For a long period of time, CWU operations were used with caution because of the risk of residual cholesteatoma and recurrence of the disease. This method helps to improve the hygienic status and functional result but there are some disadvantages, which includes the necessity of long-term follow-up and a second assessment.

According to different authors, the probability of residual cholesteatoma is about 20%, and recurrent disease is 13% from the total number of operated patients.<sup>5-7</sup> In clinics where the CWU surgical technique is used, the

Correspondence: S. Kosyakov, Russia Medical Academy of Continuous Professional Education, Ivankovskoe street 7, Moscow, Russia 125367.

E-mail: epchelenok@yandex.ru, serkosykov@yandex.ru

*Cholesteatoma and Ear Surgery – An Update 2017, pp. 159 -162*

*Edited by Matthew Yung*

*2017 © Kugler Publications, Amsterdam, The Netherlands*

requirement of a second surgical intervention is 57%. Only in 7.2% residual cholesteatoma was found and in 92.8% surgical intervention was not necessary.<sup>5</sup>

The advantages of the CWD technique are a lower rate of residuals ( $\pm 7\%$ ), a lower rate of recurrence ( $\pm 5\%$ ) and a wide surgical field.<sup>6,9</sup> However, postoperative cavities present a significant problem for the patient and for the doctor. This is why during the last several years a tendency to combine open and closed techniques has become widely spread.<sup>10,11</sup> There are a lot of different techniques for mastoid and epitympanic obliteration: bone pate, bioglass, covering it with chondro-perichondrial flap and temporal fascia.<sup>11</sup>

## 2. Materials and methods

We have been following-up our patients for some years and then analyzed the results of residual and recurrence of cholesteatoma. One hundred ninety-six ears were followed-up (77 females and 119 males). In 141 cases an operation was performed for the first time and in 55 cases re-operation was required.

Generally, this was done with the endaural approach. Mastoidectomy was performed and the epithelium of cholesteatoma was completely removed. The level of external canal posterior wall was determined by extension of cholesteatoma and sclerotic mastoid cells degree. If the process allowed we left high remnants of the external canal posterior wall. The obligatory inspection of the blind zones was accomplished with an endoscope. During the operation, the state of important anatomical structures was evaluated, such as lateral semicircular canal, facial-nerve canal, wall of sigmoid sinus and other structures of the middle ear. Also the state of ear bone was evaluated and in most cases the removal of individual elements was performed. Ossiculoplasty and tympanoplasty were done simultaneously with the chondro-perichondrial flap from tragus or posterior surface of concha of auricle.

Paratympanic spaces discovered during the operation were obliterated with cartilage, cortical bone chips, bone pate and bioglass. Lateral parts of attic, aditus and external canal posterior wall were recovered using the chondro-perichondrial flap.

To control recurrent cholesteatoma and recurrence of the disease in certain conditions standard regimes T1, T2 and non-echo planar diffusion weighted imaging (non-EPI DWI) magnetic resonance imaging (MRI) were used. The high intensive signal in standard regime T2 and non-EPI DWI and the low intensive signal in standard regime T1 show the presence of cholesteatoma. If in all regimes there was an iso-intense appearance, residual cholesteatoma was excluded. Re-examination should be conducted after one year.

## 3. Results

We have been following-up our patients for some years and then analyzed the results about residual and recurrence of cholesteatoma. From 2009 to 2014, we operated 196 ears, of which 141 operations (72%) were primary surgery, and 55 (28%) were revision and re-operations after surgery by other surgeons. The materials used for obliteration were cartilage (23%), bioglass (15%), bone pâté with bioglass (15%) and cartilage with bone pâté (47%).

Postoperative monitoring of patients was carried out intensively during the first two months, we then performed follow-up examinations after six and 12 months. Throughout this year, patients underwent MRI for the diagnosis of residual cholesteatoma and relapse. The results were evaluated according to otomicroscopy, MRI sequences, such as the non-EPI DWI and recorded for survey.

From 2009 to 2011, the residue of cholesteatoma was diagnosed in nine cases (9.6%), from 2009 to 2012 – 11 cases (8.8%), from 2009 to 2013 – 13 cases (7.9%) and from 2009 to 2014 – 14 cases (7.1%). No residual cholesteatoma or cystic lesions were detected in the obliterated mastoid cavity. Most patients had good epithelization on the external auditory canal and could cease water restriction after surgery.

#### 4. Discussion

The ideal goals of cholesteatoma surgery are the elimination of all possible causes of cholesteatoma recurrence and the establishment of a well-aerated middle ear with a proper sound-conducting mechanism as well as a trouble-free external auditory canal with self-cleaning function.

Our findings show that despite the radical intervention with the use of the open technique, in about 30% of patients chronic otitis media had not been eliminated. They were not satisfied with their life quality, due to continuing exacerbation, the need of regular removal from the cavity of the epidermis, difficulties with selection of the right hearing aid and vertigo. When the number of patients increases, the risk of statistical error reduces. It can be determined by a small number of patients. Our research shows that with an increasing number of patients residual cholesteatoma also has a slight increase.

After the primary operation, it usually takes 12-18 months for the residual disease to be revealed. During this period, operated patients must be monitored. The results of surgical treatment were estimated by otomicroscopy and MRI regime non-EPI DWI which allows for specific characterization of small cholesteatoma pearls. On MRI, cholesteatoma can be distinguished unambiguously from other soft tissues such as scar tissue, cholesterol granuloma, granulation tissue and fluid. Today, MRI is the most reliable method to control the residual cholesteatoma and its recurrence. According to different authors, the specificity of diagnosing cholesteatoma is 86%-100%.<sup>12</sup> This means that sanitation surgery with the obliteration of paratympanic spaces, with reconstruction of the external canal posterior wall and simultaneous tympanoplasty is the most preferable method of treatment. The fact is that chronic otitis media leads to a reorganization of bone and to an evident sclerotic process in mastoid cells, whereas the post-aural approach requires opening the large amounts of sclerotic bone. The endaural approach creates an opportunity to follow the process, revealing the formation of the middle ear only within the spread of cholesteatoma with subsequent improvement to these structures. In the case of an endaural approach, if the surgeon is planning to obliterate the paratympanic spaces it is possible to leave more bone intact with, of course, the obligatory inspection of the blind zones with an endoscope.

The operative technique and postoperative control combines the advantages of open and closed technique. The absence of post-operation cavity makes it possible to avoid a second operation, which is usually necessary after the closed technique.

#### References

1. Sudhoff H, Dazert S, Gonzales AM, et al. Angiogenesis and angiogenic growth factors in middle ear cholesteatoma. *Am J Otol* 2000;11:793-798.
2. Sudhoff H, Klenke C, Janowski S, et al. Identification of novel cholesteatoma-related gene expression signatures using full-genome microarrays. *PLoS One* 2012;7(12):52-71.
3. Kanemaru Shin-ichi. Bone destructive mechanisms of cholesteatoma. The 9th International conference on cholesteatoma and ear surgery. Nagasaki Japan June 3-7 2012; 195.
4. Lim DJ, Li JD, Hermansson A, et al. Recent advances in otitis media in molecular biology, biochemistry, genetics and animal models. *Otolaryngol Head Neck Surg* 2013;5:52-63.
5. Offeciers E, Vercruysse JP, De Foer B, Somers T, Casselman J. Mastoid and epitympanic obliteration. The bone obliteration technique. In: *Ars B, Chronic Otitis Media. Pathogenesis-oriented therapeutic management*, pp. 299-327. Amsterdam: Kugler Publications 2008.
6. Sanna M, Sunose H, Mancini F, Russo A. *Middle ear and mastoid microsurgery*. Stuttgart-New York: Georg Thieme Verlag 2003.
7. Sade J. Surgical planning of the treatment of cholesteatoma and postoperative follow-up. *Ann Otol Rhinolaryngol* 2000;4:372-376.
8. Mercke U. The cholesteatoma ear one year after surgery with obliteration technique. *Am J Otol* 1987;6:534-536.

9. Kim M, Choi J. Hearing outcomes according to the types of mastoidectomy: a comparison between CWU and CWD mastoidectomy. *Clin Exper Otorhinolaryngol* 2010;12:203-206.
10. Kim J, Choi J, Chung J. Clinical results of atticoantrotomy with attic reconstruction or attic obliteration for patients with an attic cholesteatoma. *Clin Exper Otorhinolaryngol* 2009;1:39-43.
11. Grantz BJ, Wilkinson EP, Hansen MR. Canal wall reconstruction tympanomastoidectomy with mastoid obliteration. *Laryngoscope* 2005;3:1734-1740.
12. Vercruysse JP, De Foer B, Somers T, Casselman J, Offeciers E. Long-term follow up after bony mastoid and epitympanic obliteration: radiological findings. *J Laryngol Otol* 2010;124(1):37-43.

# MANAGEMENT OF THE FACIAL NERVE IN CHOLESTEATOMA SURGERY: MULTIDISCIPLINARY APPROACH IN A FACIAL PARALYSIS UNIT

Luis Lassaletta<sup>1</sup>, Julio Peñarrocha<sup>1</sup>, Teresa González<sup>2</sup>, Susana Moraleda<sup>3</sup>, Javier Gavilán<sup>1</sup>

<sup>1</sup>Department of Otolaryngology, “La Paz” University Hospital, Madrid, Spain; <sup>2</sup>Department of Maxillofacial Surgery, “La Paz” University Hospital, Madrid, Spain; <sup>3</sup>Department of Physical Medicine & Rehabilitation, “La Paz” University Hospital, Madrid, Spain

## 1. Introduction

The incidence of facial paralysis in patients with middle ear cholesteatoma is generally low, but currently still present. In particular situations such as revision surgery or petrous bone cholesteatoma, facial nerve (FN) involvement may be as high as 45% to 65% of cases. Therefore, the middle ear surgeon must be familiar with nerve decompression and reconstruction techniques. Regarding FN management in cholesteatoma surgery, three main questions are: (1) Should we use intraoperative FN monitoring on a routine basis? (2) How should the damaged nerve be managed intraoperatively and postoperatively? (3) Do we need a Facial Paralysis Unit to achieve the best results?

## 2. Should we use intraoperative facial nerve monitoring on a routine basis?

The facial nerve has a relatively predictable anatomical course within the temporal bone. Difficulties arise in cases of bony malformations or dehiscence, which may be encountered in revision cases, or in complex cholesteatoma cases. Therefore it is becoming the standard of care to monitor the FN during all ear operations. Current evidence suggests that intraoperative facial NIM is of value in identifying the FN that is at surgical risk during middle ear and mastoid surgery, and it is also cost-effective.<sup>1</sup> Nevertheless, even the most up-to-date devices can fail, and a warning from the monitor may be too late. There is, therefore, no substitute for meticulous dissection with excellent visualization.<sup>2</sup> On the other hand, the otologic surgeon rather than a trained neurophysiologist usually performs facial monitoring. Therefore, a learning curve is expected in order to benefit from the FN monitor in striking cases.

## 3. How should the damaged nerve be managed intraoperatively and postoperatively?

The cholesteatoma matrix in direct contact with the nerve leads to the inflammation of the nerve trunk. If this inflammatory process extends beyond the margins of the bony defect and involves part of the nerve still covered by bone, the swelling of the nerve leads to a rise in pressure, compressing the vascular supply of the nerve and causing ischemia. If the ischemia is severe enough, necrosis of the nerve will start to occur with either interruption

Correspondence: Luis Lassaletta, MD, Department of Otolaryngology, “La Paz” University Hospital. Paseo de La Castellana, 261, 28046 Madrid, Spain.  
E-mail: luikilassa@yahoo.com

*Cholesteatoma and Ear Surgery – An Update 2017, pp. 163 -166*  
*Edited by Matthew Yung*  
2017 © Kugler Publications, Amsterdam, The Netherlands



or scarring of the involved segment with fibrous tissue replacement. In both cases the result will be a complete facial paralysis.

Patients presenting with acute facial palsy and an underlying middle ear cholesteatoma should be treated as an emergency. If the facial nerve is compressed by the cholesteatoma, immediate and careful decompression is required to achieve prompt recovery. Cleaning the nerve implies retracting the cholesteatoma matrix away from the nerve to delineate the appropriate dissection plane. Delayed interventions may lead to variable outcomes.<sup>3</sup> If the facial nerve is clearly interrupted, nerve repair with or without a graft is the preferred way of re-establishing its continuity. For an end-to-end coaptation, the two ends are approximated in such a way that the endoneural surfaces lie in contact. If the apposition is maintained with no tension, no graft is needed. Otherwise, an interposition graft must be performed. It must be kept in mind that the most important requirement for a successful anastomosis is lack of tension. If the nerve is fibrosed, the fibrosed segment should be cut and the nerve reconstructed. When an interposition graft is needed, the greater auricular nerve is the preferred donor for repairs that require grafts of less than six cm. The resulting anesthesia to the ipsilateral auricle is well-tolerated and the nerve is accessible and has an adequate diameter to provide a suitable graft.<sup>4</sup> When the required graft is more than 6 cm, a sural graft can be obtained.

If the proximal stump is either unavailable or too distorted for creation of a reliable coaptation, or if facial paralysis has been present for six to 12 months, a hypoglossal-facial anastomosis should be performed. In this case, we prefer the hemi-end-to-end hypoglossal-facial anastomosis technique, which achieves similar results to the classical technique with no tongue morbidity.<sup>5</sup> In most cases, the hemi-hypoglossal-facial technique is associated with a cross-face nerve grafting, which is a reconstructive procedure to obtain emotional controlled smile. The increased tone, improved symmetry, and possibility for purposeful movement of the face are incentives for using this method.

Whatever method is used to restore facial nerve continuity leads to maximum House-Brackmann grade III.<sup>6,7</sup> This affirmation was stated by the Gruppo Otologico, in Piacenza, Italy, who described 39 patients with FN interruption, followed by reconstruction during the original procedure. Among the 11 cases of end-to-end anastomosis, nine had final HB grade III function, and two had grade IV function. Considering the patients who underwent graft interposition, 19 had HB grade III function, four had grade IV, two had grade V, and three had grade VI. In six of the nine patients, a hypoglossal-facial anastomosis was performed. Of these six patients, two recovered to HB grade III function and four to grade IV function.

#### **4. A multidisciplinary approach in a Facial Paralysis Unit is the key to achieve the best results**

Regardless of cause, the management of facial paralysis is complex and often requires multidisciplinary intervention, consisting of a combination of pharmacologic therapy, physical therapy for facial neuromuscular retraining, and surgical intervention for facial reanimation. We believe that complex cases should be treated in a referral hospital by multidisciplinary unit specialists who can offer patients all existing therapeutic options.<sup>8</sup> The fundamental purpose of a Facial Paralysis Unit is to offer patients an integral and multidisciplinary treatment of their pathology, providing the best combination of treatments. The Facial Paralysis Unit at La Paz University Hospital was founded in 2002 by several specialists with an interest in facial nerve disorders from eight departments including Otolaryngology, Maxillofacial Surgery, Physical Medicine & Rehabilitation, Neurosurgery, Ophthalmology, Neurophysiology, Neurology, and Neuro-Radiology.<sup>9</sup> More than 500 patients with facial paralysis are evaluated in the Unit each year. Complex cases are evaluated during monthly sessions, where patients are discussed in order to offer them the best combination of medical, surgical, and rehabilitation techniques. We believe that due to the complexity of the pathology and the quality-of-life implications of these patients, the best way to make an integral management is through multidisciplinary facial paralysis units.

## References

1. Heman-Ackah SE, Gupta S, Lalwani AK. Is facial nerve integrity monitoring of value in chronic ear surgery? *Laryngoscope* 2013;123(1):2-3.
2. Hohman MH, Bhama PK, Hadlock TA. Epidemiology of iatrogenic facial nerve injury: a decade of experience. *Laryngoscope* 2014;124(1):260-265.
3. Linder TE. Facial weakness as a complication of otologic diseases. In: Slaterry WH, Azizzadeh B (eds.), *The facial nerve*, pp. 106-115. New York/Stuttgart: Thieme Medical Publishers 2014.
4. Henstrom DK, Hadlock TA. Facial nerve repair. In: Slaterry WH, Azizzadeh B (eds.), *The facial nerve*, pp. 179-191. New York/Stuttgart: Thieme Medical Publishers 2014.
5. Lassaletta L, González T, Casas P, et al. Hemi-hypoglossal-facial intratemporal side to side anastomosis. *Acta Otorrinolaringol Esp* 2008;59(3):124-126.
6. Falcioni M, Russo A, Taibah A, Sanna M. Facial nerve tumors. *Otol Neurotol* 2003;24(6):942-947.
7. Sanna M, Khrais T, Mancini F, Russo A, Taibah A. *The facial nerve in temporal bone and lateral skull base microsurgery*. 1st ed. New York, NY: Thieme Medical Publishers 2006.
8. Pardo-Maza A, Lassaletta L, González-Otero T, et al. Evolution of Patients With Immediate Complete Facial Paralysis Secondary to Acoustic Neuroma Surgery. *Ann Otol Rhinol Laryngol* 2016;125(6):495-500.
9. Facial Paralysis Unit. La Paz University Hospital. [http://www.madrid.org/cs/Satellite?cid=1354414362776&language=es&pagename=HospitalLaPaz%2FPage%2FHPAZ\\_ServiciosPrincipal](http://www.madrid.org/cs/Satellite?cid=1354414362776&language=es&pagename=HospitalLaPaz%2FPage%2FHPAZ_ServiciosPrincipal)



# THE KERATINOCYTE IN HEALTH AND DISEASE

Irene Leigh

*Ninewells Hospital and Medical School, University of Dundee, Scotland*

## 1. What is a keratinocyte?

There are three main types of epithelia: simple, stratified and mixed glandular. Stratified squamous epithelia (SSE) are resilient multilayered epithelia comprised of a distinct cell type: the keratinocytes, which make up the epidermis (the largest organ in the body), anogenital mucosae and other specialized sites. I will use the epidermis as the best studied squamous epithelium as a paradigm for other squamous epithelia.

The basal layer of the epidermis contains a subpopulation of keratinocyte stem cells, which can give rise to all the cell layers of the epidermis then undergoing terminal differentiation suprabasally to form a final protective outer stratum corneum. The site-specific differentiation of the keratinocyte determines the nature of the resulting epithelium and is dependent on signals from the underlying connective tissue. Keratinocyte stem cells can undergo both symmetric and asymmetric division to maintain homeostatic balance and to repair the epidermis following injury. The balance of growth (proliferation) to differentiation is altered in many disease states including hyper-proliferative inflammatory disease such as psoriasis, genetically determined skin disease (genodermatoses) and malignancy.

Understanding the biology of the keratinocyte was enormously enhanced by the discovery in 1975 that keratinocytes can readily be cultured in the laboratory using 3T3 feeders and growth factors (epidermal growth factor). In these circumstances, the cells are undergoing very rapid turnover (each cell divides once every 22 hours). The keratinocyte retains its hallmark characterization of expression of intermediate filaments type I and II: keratin family. It also forms tight cellular interactions through junctional complexes: including desmosomes whilst stratifying to form a differentiated epidermis, which is firmly attached to a dermal substrate by hemidesmosomes. The huge amplification of this technique was early illustrated by the application of sheets of autologous keratinocytes to treat major burns now commercialized and in clinical practice. Keratinocytes also form skin appendages, such as hair follicles where there are two additional specialized stem cell populations occurring apart from the interfollicular epidermal (IFE) stem cells: namely the Hair stem cells in the hair bulb (directed by the dermal papilla mesenchymal cells) which give rise to the hair fiber and the pluripotential stem cell population in the hair follicle bulge at the site of insertion of the arrector pili muscle. These populations will activate to allow wound healing to occur from the hair follicle if the epidermis is damaged.

## 2. Some critical concepts for skin health

In normal epidermis, there is a balance between keratinocyte proliferation/cell death which is controlled by complex networks of growth factors and their receptors, expressed in both autocrine and paracrine fashion. Even elderly keratinocytes have a high proliferative potential *in vitro* (skin graft evidence) although senescence (replicative) does occur in ageing and skin atrophy. The plasticity of keratinocytes is greater than expected as it receives both

Correspondence: Prof. Irene M Leigh, University of Dundee, Centre Molecular Medicine, Clinical Research Centre, Ninewells Hospital and Medical School, Dundee DD1 9SY, UK.  
E-mail: I.M.Leigh@dundee.ac.uk

*Cholesteatoma and Ear Surgery – An Update 2017, pp. 167 -170*

*Edited by Matthew Yung*

*2017 © Kugler Publications, Amsterdam, The Netherlands*

permissive and directive signals from the underlying dermal niche. Chronically wounded skin may become stem cell depleted, which impairs healing such as in the genodermatosis: epidermolysis bullosa. The epidermis will also be damaged by exogenous factors, particularly ultraviolet radiation.

### 3. Epidermal differentiation: keratins

Keratinocytes express keratins as type I and II intermediate filaments, which are numbered according to their position on a two-dimensional gel and co-express in particular pairs. The heterodimers aggregate in an antiparallel conformation to form the intact keratin fiber. In the normal epidermis, the basal keratinocytes express the keratin pair K1 and K10 and the suprabasal cells, committed to differentiation, express keratins 1 and 10. The suprabasal normal mucosa expresses the keratin pair keratins 6 and 16, as does the epidermis when hyperproliferative in disease or for wound healing. Monoclonal antibodies to individual keratins can thus be used as markers of differentiation. An early study of cholesteatoma<sup>1</sup> showed a keratin expression characteristic of hyperproliferative disease with reduced K10 expression extended basal keratin expression K5 and K14. There was no ectopic expression of simple epithelial keratins 7,18,19 except in mucous glands, whereas this commonly occurs in malignant epidermis.

### 4. Genetically inherited diseases can affect structural proteins

Modern technological advances from next generation sequencing and other -omics technologies have greatly advanced our ability in diagnosing and understanding the genetic mutations underlying inherited diseases. This has illuminated the cause of many genetic skin diseases as being caused by mutations in structural proteins (Table 1).

*Table 1.* Molecular classification of genodermatoses

Cell integrity or adhesion
Keratin disorders
Desmosome diseases
Connexin diseases
Calcium pump deficiencies
Barrier function/ cornification
Enzyme deficiencies giving disorders of keratinization
Disorders of cholesterol metabolism/lipid transport
Others affect epidermal growth and differentiation
Dermo-epidermal junction
Metabolic disorders
Predisposition to cancer
DNA repair
Pigmentation genes (OCA1, 2, etc.)

*Keratins* maintain the structural integrity of a cell by acting as the major stabilizing cytoskeletal protein. Point mutations in critical regions of a keratin polypeptide, particularly the termination initiation and termination peptides lead to keratinocyte fragility and epidermolysis, where mild trauma causes cells to rupture and the skin to form blisters seen clinically. In severe disease keratin aggregates are a diagnostic feature seen ultrastructurally and the distribution of lesions mirrors the site specificity of keratin expression (Table 2). Keratins insert into desmosomal plaques at the cell periphery which help to stabilize the epidermis. As they occur in other tissues, mutations in desmosomal components particularly desmoplakin, cause cardiomyopathies as well as palmoplantar keratodermas. Histologically these are characterized by loss of cellular cohesion and widening of the intercellular space.

Table 2. Keratin mutations

Disease	Mutated keratin
Epidermolysis bullosa simplec	K5/14
Epidermolytic ichthyosis	K1/2/10
Pachyonychia congenita	K6/16/17
Epidermolytic palmoplantar keratoderma	K9
White sponge naevus	K4/13
Meesman's corneal dystrophy	K3/12
Cryptogenic cirrhosis	K8/18

*Connexins* form an important junctional complex, namely gap junctions involved in intercellular communication, aligning as connexons to line channels which allow the passage of small molecules between cells. Mutations in connexins give rise to a number of syndromes, the most important association being hearing loss. Dominant connexin 26 mutations cause palmoplantar keratoderma and hearing loss, but connexin 26 mutations are also the major global cause of non-syndromic recessive hearing loss.

*Filaggrin* is a -filament aggregating protein expressed as profilaggrin in the granules of the stratum granulosum or granular layer. This is involved in forming the cornified envelope, which, with deposition of extracellular lipid, forms the outer impermeable layer of the epidermis: the stratum corneum. In addition to keeping the outside out (infectious agents, antigens, etcetera), this layer retains water in the epidermis so breakdown products of filaggrin are natural moisturising factors and protect against ultraviolet radiation. Mutations in filaggrin were found to cause the common autosomal dominant ichthyosis vulgaris, but also to be strongly associated with atopic eczema. This early loss of skin barrier function probably predisposes to antigen exposure, which drives the immunological responses of atopic eczema.

## 5. Ultraviolet radiation and skin cancer

The keratinocyte is the first line of defence against one of the most damaging environmental factors: ultraviolet radiation (UV). Although UVB (290-320 nm) is less than 1% of the solar terrestrial spectrum, it is the major cause of skin cancer as DNA is the chromophore for UVB. UVA has a role through induction of guanine oxidation products in DNA. Direct DNA damage by UVB induces cyclobutane-pyrimidine dimers and 6-4 photoproducts, which give characteristic CC@TT 'signature' mutations. In addition to the effects on DNA carcinogenesis is enhanced by UV-induced immuno-suppression.

The keratinocytes defend themselves from UV by DNA repair mechanisms including nucleotide excision repair (NER); removal of damaged cells by intrinsic/extrinsic apoptotic pathways; anti-oxidative defences; adaptive responses such as inducible melanogenesis, and epidermal thickening. Critically immune surveillance recognizes and removes mutated cells. Thus, if DNA repair is genetically impaired as in the disease xeroderma pigmentosum or the patient is immunosuppressed as in organ transplant recipients patients will be at greatly increased risk of skin cancer.

In normal epidermal homeostasis: a balance between cellular life and death is maintained, but in skin carcinogenesis: an imbalance between cellular life and death occurs. Normal skin has a high level of UV induced mutation particularly in p53, NOTCH genes and CDKN2a and this is held in check for many years. However, malignancies do occur with increasing age and are a major clinical problem in an ageing population of fair skinned individuals. Up to 230,000 skin cancers were reported in 2015 in the UK alone. Non-melanoma skin cancers deriving from keratinocytes are far commoner than melanomas which arise from the melanocyte subset of cells in the skin and mucous membranes. Basal cell carcinomas are locally invasive, slow growing lesions. Finding mutations



in the *PATCH* and *SMO* genes in hereditary basal cell nevus syndrome (Gorlin's) highlighted that mutations in the Hedgehog (Hh) signaling pathway are sufficient for basal cell carcinogenesis. These dominate in sporadic basal cell carcinoma also and have led to successful trials of inhibitors of Hh signaling. Less is known about the extremely highly mutated cutaneous squamous cell carcinomas (cSCC) What causes progression through premalignant actinic keratosis to cSCC to metastatic disease is not yet clear. As keratinocytes become more dysplastic they lose those differentiation markers characteristic of mature epidermis and express simple epithelial keratins as they go along a pathway of dedifferentiation and invasion.

## 6. Summary

Keratinocytes make up stratified squamous epithelia and can be cultured through many population doublings, which allows us to study keratinocyte biology intensively. Keratinocytes undergo a hyper-proliferative differentiation pathway in wound healing and benign disease but become less differentiated in malignancy. Genetic mutations in keratins and junctional proteins emphasize their role in keratinocyte resilience and mutations in filaggrin play a major role in disturbed barrier function in ichthyosis and atopic eczema.

## Reference

1. Broekaert D, et al. A comparative immunohistochemical study of cytokeratin and vimentin expression in middle ear mucosa and cholesteatoma and in epidermis. *Virhows Archiv A Pathol Anat Histopathol* 1988;413:39-51.

# INTRODUCING THE ‘CHOLE’ CLASSIFICATION

Thomas E Linder<sup>1</sup>, Shankar Shah<sup>1</sup>, Christof Rösli<sup>2</sup>, Alex M Huber<sup>2</sup>, Nue Milici<sup>1</sup>

<sup>1</sup>*Department of Otolaryngology, Head and Neck Surgery, Luzerner Kantonsspital (LUKS), Luzern, Switzerland;*

<sup>2</sup>*Department of Otolaryngology, Head and Neck Surgery, University Hospital Zürich, Zürich, Switzerland*

## 1. Introduction

In otology, chronic otitis media (COM) with or without cholesteatoma formation is a frequent disease entity requiring surgery. The diagnosis of a congenital middle ear or acquired temporal bone cholesteatoma is made clinically by otoscopy and a CT scan is performed to evaluate its extent and for planning of the surgery. Rarely a non-EPI-diffusion MRI is ordered at first diagnosis to support the clinical findings. Before going to the operating theater, a pure-tone audiogram is mandatory often accompanied by a speech audiogram as well.

The goals of surgery have not changed over the last five decades and include total removal of the disease (least risk of residual pathology), prevention of recurrent disease and optimal hearing restoration. The techniques have improved over the last decades and are currently challenged between open- or closed-cavity surgeries, with or without obliteration techniques and these surgical principles are performed using a microscope, endoscope or a combination of both. For hearing reconstruction, newer prosthetic devices were introduced and used in a primary or staged setting. At conferences and during panel discussions, most otologic surgeons report on ‘huge’ cholesteatomas, ‘massive’ extensions, ‘severe’ bony erosions and feel confident with their technique and results. However, it is difficult to compare the outcome if there is no uniform classification system. There have been many attempts already to classify cholesteatoma disease, but none has been widely used or implemented.<sup>1</sup> Some have modified the TNM system used for tumors, others have relied on anatomical barriers.<sup>2,3</sup> After some decades of personal experience with cholesteatoma surgeries, we introduce our Version\_1.0 of a ‘ChOLE’ staging system, and present our first results.

## 2. Methods

We identified four basic scores, which enable the description of a cholesteatoma pre- and intraoperatively.

- Ch = Cholesteatoma extension. All previous classification systems use a staging to identify the location and extension of cholesteatoma matrix within the middle ear and mastoid. Congenital apical cholesteatomas are usually excluded since they present a rare and unique disease entity. We have defined four types of tympanomastoid cholesteatoma extensions (Fig. 1).
- O = Ossicular chain. Whereas preoperative hearing in cholesteatomas appears quite unpredictable to anticipate from analyzing the CT scans and otoscopy, postoperative hearing outcome does depend on the state of the ossicles and the prosthetic reconstruction used. Austin and Kartush<sup>4</sup> and Fisch<sup>5</sup> have introduced a classification system to categorize the most frequently encountered presence or absence as well as fixation of the middle ear ossicles. Few previous classification systems have integrated these findings.<sup>6</sup> Since one of the major goals of surgery is the optimal hearing reconstruction and outcome, it has to be part of a uniform

Correspondence: Prof. Dr. med. Thomas Linder, Department of Otorhinolaryngology, Luzerner Kantonsspital Spitalstrasse, CH-6000 Luzern, Switzerland.  
E-Mail: Thomas.Linder@luks.ch

*Cholesteatoma and Ear Surgery – An Update 2017, pp. 171 -176*

*Edited by Matthew Yung*

*2017 © Kugler Publications, Amsterdam, The Netherlands*

CHOLE - Staging System for Cholesteatoma

Calculate the CHOLE stage with this tool by walking through following steps. Select those items which fit to your patient and get an overall CHOLE stage as result. Use the following shortcuts to quickly switch the single states: C, O, L, E (or A, S, D, F). With every change, the new classification value is copied to the clipboard.

















	Extension	Ossicular chain status (at the end of surgery)	Life threatening complications	Eustachian tube ventilation and mastoid pneumatization
X	Not identifiable (not specified)	Not identifiable (not specified)	Not identifiable (not specified)	Not identifiable (not specified)
0			None	
1	 	 		Moderate to good pneumatization good ventilation
2	 	 	Extracranial complications	Moderate to good pneumatization poor ventilation
3	 	 		Sclerotic mastoid
4	 	 	Intracranial complications	

Fig. 1. Overview.

classification system. We have defined the 'O' status as the final status of the patient's own ossicles at the end of surgery.

- L = Life-threatening complications. The surgical approach may depend on the presence of complications such as brain abscess, labyrinthitis or facial palsy. Severe, or even life-threatening complications are exceedingly rare in the Western World, but are still daily business in underdeveloped and rural countries with limited access to medical care. We defined three levels of complications. Extracranial-extratemporal, such as acute mastoiditis with Bezold's or Luc's abscess, extracranial-intratemporal complications, such as facial palsy, labyrinthitis with sensorineural hearing loss and finally intracranial complications such as meningitis or brain abscess.
- E = Eustachian tube and middle ear ventilation. Since most of the patients do get a CT scan prior to surgery, an evaluation of the degree of pneumatization and ventilation can be performed in these cases. Whereas most patients with acquired COM with cholesteatoma formation suffered from early disease onset and therefore present with a reduced pneumatization and ventilation, there is quite a variety of the extent of aeration. To know the impact of preserving the mastoid using endoscopic inside-out techniques or mastoid obliteration procedures, one must compare groups of patients with similar degree of preoperative ventilation properties.

The acronym 'ChOLE' is therefore used to classify cholesteatoma extension (Ch), ossicular chain status (O), complications (L) and Ventilation (E). We have retrospectively analyzed 100 consecutive primary cholesteatoma cases operated at the Luzerner Kantonsspital to validate the version 1.0 of our classification system. As an additional adjunct the Zürich research group analyzed their quality of life questionnaire ZCMEI-21, developed exclusively for patients with chronic otitis media.

### 3. Results

We were able to categorize all patients into our classification system. The distribution between the individual subgroups is shown in Table 1. The rating otologists with different surgical and non-surgical experience relied on the preoperative CT scans, surgical notes and the surgeon's drawing. Since fellows from non-German speaking countries were also rating a number of 20 patients randomly, we identified that the quality of the surgeon's drawing was quite dependent on the skills of that surgeon, whereas analyzing the operating note was easier to understand for the German speaking residents. During the study we therefore standardized the surgeon's drawings by using prefabricate schematics of the temporal bone (database by [www.innoforce.ch](http://www.innoforce.ch)), which markedly improved the validity of the extent (Ch) and ossicular chain (O) staging. Large extensions (Ch4) were rarely encountered, whereas there was a similar distribution between Ch1-3 subgroups (Fig. 2). The majority of cases presented with an erosion of the incus (03) with an intact stapes and malleus handle (Fig. 3). Severe complications (L) were not depicted in this study group and the pneumatization was rather reduced in the majority of cases. There was a significant relationship between the preoperative PTA and the ossicular score ( $p < 0.001$ ). Overall, there were eight residual and eight recurrent cholesteatomas within the follow-up time of one to ten years, however, there was no significant difference in their occurrence between different score groups. Open cavity surgeries were more frequently performed in the subgroup of higher Ch scores or poorer pneumatization subgroups. Our attempt to summarize the individual classes into a limited number of stages (e.g. Ch1, O2, L1, E2 into Stage 2) was rather empiric and did not allow statistical comparison.

Table 1. Distribution of 100 patients into the ChOLE classification system.

Extension		Ch 1	Ch 2	Ch 3	Ch 4
n		31	21	46	2
Ossicular chain	<b>O 0</b>	<b>O 1</b>	<b>O 2</b>	<b>O 3</b>	<b>O 4</b>
n	25	51	12	11	1
Complications (L)	<b>L 0</b>	<b>L 1</b>	<b>L 2</b>	<b>L 3</b>	
n	100	0	0	0	
Pneumatization (E)	<b>E 0</b>	<b>E 1</b>	<b>E 2</b>	<b>E 3</b>	
	2	14	33	51	



Fig. 2. Distribution of Ch-Extension subgroups.




Fig. 3. Distribution of Ossicular chain subgroups (O).

#### 4. Discussion

Whereas many attempts have already been made to classify cholesteatomas, most of them were too complicated or not pertinent to the clinician's experience and expectation. Our approach was to identify the parameters relevant for the clinical judgment. One of them is certainly the extent of the disease (Ch). We identified four stages for tympanomastoid cholesteatomas and excluded the apical or supralabyrinthine extensions. During the validation process it became clear that a standardized schematic representation of the anatomical borders improved the interobserver agreements in a retrospective analysis of 100 cases. Surgical drawings of the most important aspects of disease extension and also of the reconstructive methods are used in our clinics for many years and we strongly encourage to standardize these schematic OR notes using a template and a color coding. Meanwhile, we have implemented an improved version of cholesteatoma extension and are in the process of its validation. The state the ossicular chain is usually not considered in other suggested classification systems.<sup>2,3,7</sup> As the patient's and

surgeon's expectation is optimal hearing reconstruction in a primary or staged setting, the identification of the integrity and functionality of the ossicles is vital for quality control and for comparison of different prosthesis and techniques. Our ossicular chain staging (O) is based on the well-established Austin-Kartush and Fisch grading and represents the most frequent situations encountered at surgery. Although our 100 patients did not present with a complication (L) caused by the cholesteatoma, we feel that it is important to integrate the presence of labyrinthitis, facial palsy or abscess formation in a classification system. Finally, the pneumatization and ventilation of the mastoid cells was included in the staging system to evaluate its impact on current or future techniques. Whereas acquired cholesteatomas may develop due to poor Eustachian tube and middle ear ventilation function, the impact of the degree of pneumatization was never systematically analyzed nor tested prospectively also in respect to recidivism of the disease.

## 5. Conclusions

We propose a classification system 'ChOLE' for the easy and straight forward pro- and retrospective staging of tympanomastoid cholesteatomas and rely on the disease extent, condition of the patient's own ossicular chain at the end of surgery, complications and the degree of pneumatization and ventilation. It can be supplemented with a specific quality of life questionnaire, such as the ZCMEI-21. We are currently working on an improved version of the ChOLE staging system and validate it on a larger cohort with a comparison of other classification systems, such as the EAONO/JOS classification system.<sup>6</sup>

## References

1. Black B, Gutteridge I. Acquired cholesteatoma: classification and outcomes. *Otol Neurotol* 2011;32(6):992-995.
2. Belal A, Reda M, Mehanna A, Belal Y. TMC: a new staging system for tympanomastoid cholesteatoma. *Egyptian J Otolaryngol* 2012;28:12-16.
3. Kitahara T, Mishiroy Y, Sakagami M, et al. Staging-based surgical results in chronic otitis media with cholesteatoma. *Nihon Jibiinkoka Gakkai Kaiho* 2012;115(2):91-100.
4. Kartush JM. Ossicular chain reconstruction. *Otolaryngol Clin N Am* 1994;27(4):689-717.
5. Fisch U, May J, Linder T (eds). *Tympanoplasty, Mastoidectomy and Stapes Surgery*. 2nd edition. Stuttgart: Thieme 2008.
6. Dornhoffer JL. Prognostic factors in ossiculoplasty: a statistical staging system. *Otol Neurotol* 2001;22(3):299-304.
7. Yung M, Incesulu A, Sudhoff H, et al. EAOMO/JOS joint consensus statements of the Definition, Classification and Staging of Cholesteatoma. *Chole* 2016, Edinburgh. 2016.





# DWI IMAGING IN EXTENSIVE PETROUS BONE CHOLESTEATOMA

Simon K.W. Lloyd<sup>1,2,3</sup>, Hannah North<sup>2</sup>, Andrew T. King<sup>4</sup>, Scott Rutherford<sup>4</sup>, Charlotte Hammerbeck-Ward<sup>4</sup>, Simon Freeman<sup>2,3</sup>

<sup>1</sup>University of Manchester, Manchester, UK; <sup>2</sup>Department of Otolaryngology, Salford Royal Hospital, Manchester, UK; <sup>3</sup>Department of Otolaryngology, Manchester Royal Infirmary, Manchester, UK; <sup>4</sup>Department of Neurosurgery, Salford Royal Hospital, Manchester, UK

## 1. Introduction

Over the past few years, magnetic resonance imaging (MRI) using diffusion-weighted imaging (DWI) techniques have been used to aid the identification of recurrent/residual middle ear cholesteatoma following surgery. There is a considerable body of literature on the sensitivity and specificity of DWI in post-operative monitoring of middle ear cholesteatoma. There is a fairly high recurrence rate ranging from 10-35%. There is, however, no literature looking at recurrence rates on DWI imaging in petrous bone cholesteatoma. Clinical petrous bone cholesteatoma (PBC) recurrence rates are up to 6%. This relatively low recurrence rate is counter-intuitive given the extent of petrous disease and the structures that are often involved. This study investigates the recurrence rates in PBC as determined by non-EPI DWI imaging.

## 2. Patients and Methods

A retrospective analysis of a prospectively updated skull base disease database was undertaken and sixty four patients with PBC were identified and included in the study. The mean age at surgery was 44.4 years. There were 35 right ears and 29 left ears. Thirty-seven patients had acquired cholesteatomas and 27 had congenital cholesteatomas. The mean follow up was 3.4 years. All patients underwent postoperative serial non-EPI DWI imaging using multi shot fast spin echo propeller sequences using a 1.5 Tesla General Electric MRI scanner. Cholesteatomas were classified according to the Moffat classification. 46% were supra labyrinthine; 33% had massive labyrinthine cholesteatomas; 18% were infralabyrinthine; 3% were purely apical. All structures within or adjacent to the temporal bone were involved in the study cohort with otic capsule, facial nerve and dura being the most frequently involved structures. A wide range of surgical approaches were used with the translabyrinthine approach and subtotal petrosectomy being the most commonly used.

## 3. Results

The recurrence rate on DWI imaging was 38%. Fifty percent of these recurrences were stable or very small at the time of writing and were being managed conservatively. DWI imaging allows monitoring of these recurrences and intervention can be timed to allow removal when the recurrence is large enough to find easily, but small enough to remove with minimal risk of further recurrence. The other 50% underwent re-exploration of the temporal bone.

Correspondence: Professor Simon Lloyd, University Department of Otolaryngology, Head and Neck Surgery, Peter Mount House, Manchester Royal Infirmary, Oxford Road, Manchester M13 9WL, UK.  
E-mail: sklloyd@me.com

*Cholesteatoma and Ear Surgery – An Update 2017, pp. 177 -178*  
*Edited by Matthew Yung*  
2017 © Kugler Publications, Amsterdam, The Netherlands

The sensitivity and specificity of DWI imaging in these cases was 100%. DWI imaging allowed clear identification of the anatomical location of the recurrence.

#### **4. Conclusion**

Non-EPI DWI MRI is a useful technique for identification of residual/recurrent petrous bone cholesteatoma. Recurrence rates are higher than the existing literature suggests and this reflects the fact that clinical follow up in patients with this disease, many of whom have had blind sac closure, is not reliable. DWI MRI also provides useful surgical planning information when considering removal of recurrences.

# ENCEPHALOCELE AND BRAIN HERNIATION FROM PREVIOUS MASTOID SURGERY

Simon K.W. Lloyd<sup>1,2,3</sup>, Hannah North<sup>2</sup>, Andrew T. King<sup>4</sup>, Scott Rutherford<sup>4</sup>, Charlotte Hammerbeck-Ward<sup>4</sup>, Simon Freeman<sup>2,3</sup>

<sup>1</sup>University of Manchester, Manchester, UK; <sup>2</sup>Department of Otolaryngology, Salford Royal Hospital, Manchester, UK; <sup>3</sup>Department of Otolaryngology, Manchester Royal Infirmary, Manchester, UK; <sup>4</sup>Department of Neurosurgery, Salford Royal Hospital, Manchester, UK

## 1. Introduction

Meningoencephaloceles (MEC) are herniations of the brain and meninges through the skull base. They may be congenital or acquired. Those that are acquired and occur in the middle temporal fossa are often follow mastoid surgery. They are associated with CSF leak, meningitis and intracranial sepsis as well as hearing loss, most commonly conductive in nature. This paper presents the outcomes of repair of lateral skull base defects in the presence of residual cholesteatoma.

## 2. Patients and Methods

A prospectively updated database was retrospectively searched to identify patients MEC. Of 37 patients identified with MEC, ten were associated with residual cholesteatoma. They were either congenital defects associated with incidental cholesteatoma or residual cholesteatoma with iatrogenic MEC following significant dural injury. The mean age at surgery was 47.1 years. The male female ration was one to four. Mean follow-up was 31 months. All patients had preoperative CT and MR imaging and postoperative MR imaging. They presented with CSF otorrhoea (50%) or meningitis or other forms of intracranial sepsis (30%). Ten percent were incidental findings.

## 3. Results

The mean skull base defect size was 11.5 mm (range 2-20 mm). Sixty percent were confined to the tegmen mastoideum. Ten percent were confined to the tegmen tympani. Twenty percent involved both. Ten percent involved the external auditory canal. The repair was transmastoid in 50%, combined transmastoid and middle fossa in 40% and middle fossa only in 10%. Those that were smaller than two cm and confined to the tegmen mastoideum were candidates for a transmastoid approach. Larger defects, multiple defects or defects over the ossicular heads were generally managed by a combined transmastoid and middle fossa approach. Transmastoid repairs were undertaken using conchal cartilage/perichondrium composite grafts inserted through the defect. A second layer of bone dust and fibrin glue was then used to reinforce the bony defect. Blind sac closure was not necessary in most cases. Middle fossa repairs were undertaken using patties consisting of bone dust and fibrin glue or calvarial bone placed along the middle fossa floor. A second layer of artificial dura was used to cover the dural

Correspondence: Professor Simon Lloyd, University Department of Otolaryngology, Head and Neck Surgery, Peter Mount House, Manchester Royal Infirmary, Oxford Road, Manchester M13 9WL, UK.  
E-mail: sklloyd@me.com

*Cholesteatoma and Ear Surgery – An Update 2017, pp. 179 -180*

*Edited by Matthew Yung*

*2017 © Kugler Publications, Amsterdam, The Netherlands*

defect. Cholesteatoma was removed and involved dura was diathermied to denature the protein matrix. There were no recurrent CSF leaks. One patient had a postoperative temporal lobe abscess and one patient had postoperative meningitis. There were no cases of postoperative sensorineural hearing loss. Recurrence of cholesteatoma occurred in 20%, one of which was an implantation cholesteatoma following blind sac closure. There were no recurrences of the MEC on postoperative imaging.

#### **4. Conclusion**

Transmastoid and middle fossa approaches are a safe means of repairing middle fossa MEC. The risk of cholesteatoma recurrence is no higher than in routine middle ear cholesteatoma.

# PRACTICALITY ANALYSIS OF JOS STAGING SYSTEM FOR CONGENITAL CHOLESTEATOMA: JAPAN MULTICENTER STUDY (2009-2010)

Yuka Morita<sup>1</sup>, Tetsuya Tono<sup>2</sup>, Yutaka Yamamoto<sup>3</sup>, Hiromi Kojima<sup>3</sup>, Masafumi Sakagami<sup>4</sup>, Yasuo Mishiro<sup>4</sup>, Taeko Okuno<sup>5</sup>, Yasuyuki Hinohira<sup>6</sup>, Keiji Matsuda<sup>2</sup>, Sho Hashimoto<sup>7</sup>

<sup>1</sup>Niigata University, Niigata, Japan; <sup>2</sup>Miyazaki University, Miyazaki, Japan; <sup>3</sup>Jikei University School of Medicine, Minato, Tokyo, Japan; <sup>4</sup>Hyogo College of Medicine, Nishinomya, Hyogo, Japan; <sup>5</sup>Mitsui Memorial Hospital, Tokyo, Japan; <sup>6</sup>Kamio Memorial Hospital / Syowa University, Tokyo, Japan; <sup>7</sup>National Sendai Medical Center, Sendai, Japan

## 1. Introduction

Potsic classification has been widely used as the classification of congenital cholesteatoma. According to this classification, destruction of ossicles is one of the important points. And the stage will be progressed if the ossicular chain is destructed even in the case of small cholesteatoma which is limited to the tympanic cavity. The committee on Nomenclature of the Japan Otological Society (JOS) was appointed in 2004 to create a cholesteatoma staging system widely applicable in Japan and as simple as possible to use in a clinical practice. We introduce our staging system about congenital cholesteatoma.

## 2. Methods

A total of 599 ears that underwent surgery for fresh cholesteatoma between 2009 and 2010 at six institutions in Japan were recruited and cases with congenital cholesteatoma were selected. In order to determine the progress site reliably, we strictly selected the cases in which surgical records could be obtained in detail. We evaluated the progression of cholesteatoma according to the 2015 JOS cholesteatoma staging and classification system as followed.

Stage I: Limited to tympanic cavity ( Ia: anterior part, Ib: posterior part, Ic: both);

Stage II: Beyond tympanic cavity;

Stage III: Associated with intra-temporal complications;

Stage IV: Associated with intracranial complications.

## 3. Results

Seventy-one out of 599 ears were diagnosed for congenital cholesteatoma and 37 ears of 71 have been studied. Six ears were classified for Stage Ia, 11 ears for Ib, one ear for Ic, 17 ears for II and two ears for III. Concerning the pathology of stapes in Stage I, the missing rate of stapes superstructure was 0%, 54.5% and 100% in Stage Ia, Ib and Ic, respectively.

Correspondence: Yuka Morita M.D.,Ph.D., Department of Otolaryngology Head and Neck Surgery, Niigata University Faculty of Medicine, Asahimachi-dori 1, Chuo-ku, Niigata 951-8510, Japan.

E-mail: yukam@med.niigata-u.ac.jp

*Cholesteatoma and Ear Surgery – An Update 2017, pp. 181 -182*

*Edited by Matthew Yung*

*2017 © Kugler Publications, Amsterdam, The Netherlands*



#### **4. Conclusions**

Congenital cholesteatoma which was limited to the tympanic cavity was different in stapes status by the part of existence of cholesteatoma. Especially in this study, Stage Ib was most common in Stage I. Our staging system which is classified on the basis of cholesteatoma extent is simple and useful.

# **SURGERY OF CHOLESTEATOMA IN PEDIATRIC AGE: ASSESSMENT OF COMBINED MICRO-ENDOSCOPE APPROACH**

N. Nassif, \*T. Sorrentino, \*S. Zorzi, L.O. Redaelli De Zinis

*Department of Pediatric Otorhinolaryngology, Children's Hospital of Brescia,*

*\*Department of Otorhinolaryngology, Spedali Civili of Brescia, Italy*

## **1. Introduction**

Cholesteatoma in pediatric age is an aggressive disease and often necessitates an extensive surgical approach to eradicate the pathology and a long-time follow-up. The introduction of otoendoscopy not only as a diagnostic tool but also as an operative one gives a cue to reconsider certain standardized microscope operative techniques.<sup>1,2</sup> The aim of this study is to survey how otoendoscopy is evolving in our daily practice in approaching middle ear cholesteatoma and the preliminary results obtained.

## **2. Methods**

The medical charts of patients who underwent tympanoplasty for chronic otitis media with cholesteatoma between January 1995 and December 2014 were reviewed. Patients with incomplete data were not included in the study. The data collected included age, sex, features of cholesteatoma and types of tympanoplasty (TPL) were divided as follows: transcanal (TC), canal-wall-up (CWU) or canal-wall-down (CWD). The surgical techniques applied were divided according to the instrumentation used such as microscope and or endoscope and revision surgery for recidivism. Furthermore, Comparison of data was done before and after 2010, the year of introduction of otoendoscopy in our department.

## **3. Results**

Ninety-three children, 57 M and 36 F, average age ten (range three to 16) were identified for the study. Seven patients had bilateral cholesteatoma. There were 186 tympanoplasties performed, divided as follows: 63% (63/100) CWU, 15 of which underwent a second look CWU and 25 underwent a second look CWD; 20% (20/100) CWD of which ten, two and one cases underwent a second, third and fourth look, respectively; 17% (17/100) underwent TC, seven of which underwent a second look TC. Three out of these seven underwent a third look and were converted to CWD (two cases) and to CWU (one case). Before and after the introduction of endoscopy the corresponding 56 and 44 first-look procedures were performed as follows: CWU 57% vs 45%, CWD 27% vs 16% and TC 16% vs 39%, respectively.

Correspondence: Nader Nassif, Department of Pediatric Otorhinolaryngology, Spedali Civili, Piazza Spedali Civili 1, 25100 Brescia, Italy.

E-mail: nadernassif@alice.it

*Cholesteatoma and Ear Surgery – An Update 2017, pp. 183 -186*

*Edited by Matthew Yung*

*2017 © Kugler Publications, Amsterdam, The Netherlands*

#### 4. Discussion

The incidence of cholesteatoma in pediatric age varies between three to six per 100 000.<sup>3,4</sup> Moreover, recidivism is high and an extensive surgical approach as an attempt to eradicate the pathology is often necessary without undermining the preservation of hearing. In primis, the surgical approach is tailored according to the nature of cholesteatoma in being acquired or congenital, cystic or invasive. Furthermore, the strategy to manage recidivism of cholesteatoma depends on if it is residual, recurrent or iatrogenic in nature.

Standardized surgical approaches of TC, CWU, CWD or subtotal petrosectomy are at our disposition. In pediatric age, the surgeon opts to be less invasive since children have a life span to meet. Therefore, not only eradication of the disease is considered, but also functional outcomes such as hearing, balance and stability of the cavity.

Follow-up is another issue to be considered. Children have an extremely active metabolism and the possibility of recidivism is higher than in adults, thus they need to be followed-up for a longer period, almost their lifespan. Imaging, MRI, non-EPI-DWI, is a very helpful tool in monitoring the disease and trying to avoiding unnecessary surgical revisions. Most authors would consider MRI at one year postoperatively, otherwise explorative tympanoplasty is recommended.<sup>5</sup> In case of recurrence of the disease, especially if invasive, the indication of revision surgery would shift towards more invasive options such as converting a CWU into CWD procedure.

Introduction of otoendoscopy lately gives a cue to reconsider certain standardized techniques. Use of endoscopy in ear surgery is an interesting technique by offering the possibility to be less invasive.<sup>6</sup> It helps dominate blind angles favoring better cholesteatoma removal and hence, at least indirectly, decrease the rate of recidivism. Applying solely otoendoscopy for cholesteatoma removal should be limited when the disease is involving only the tympanic cavity.<sup>7</sup>

In our series, between 1995 and 2014, primary surgeries were mainly CWU (63%), followed by CWD (20%) and TC (17%). Dividing the data since the introduction of otoendoscopy in 2010, we noticed that the CWU underwent a little decrease in percentage (57% to 45%) but CWD dropped to almost one half (27% to 16%). On the other hand, the TC approach increased more than double (16% to 39%), as shown in Table 1.

*Table 1.* Distribution of percentage of first look procedures before and after introduction of endoscopy.

	1995-2010	2010-2014
CWU	57%	45%
CWD	27%	16%
TC	16%	39%.

CWU: canal wall up, CWD: canal wall down, TC: transcanal.

This decrease in the CWU and CWD surgeries and the tangible increase of TC, 250%, are the result of otoendoscopy. The otosurgeon is more confident to take a choice in avoiding mastoidectomy in certain cases such as cholesteatoma extending to the attic. In our daily practice, when cholesteatoma is not well dominated in the middle ear in the TC approach, we would extend surgery to CWU or CWD in order to make sure the pathology is removed. Since angled endoscopes offer a valid view of epitympanum and therefore the aditus ad antrum, we are more at ease to decide not to extend our surgery to a mastoidectomy.

The decrease of almost 40% of CWD after the introduction of otoendoscopy was due to the fact that the sinus tympani and facial recess were well-dominated during surgery. Both with the microscope and endoscope, the pathology was removed and checked for not leaving any macroscopic residuals.

The important considerations concerning the rational of applying endoscopy in ear surgery are to eradicate surgery and decrease morbidity, especially in children. In case of intact and healthy ossicles, where cholesteatoma is occupying the lateral part of the head of the malleus and the body of the incus or extending to the antrum, a CWU mastoidectomy including antrostomy would be a plausible choice to take away the pathology leaving intact

the ossicles. On the other hand, in trying to approach such a pathology by an exclusive TC endoscopy, an extended atticotomy (reaching the antrum of the mastoid) and removal of the head of the malleus and the incus are required. That would determine the need to reconstruct both the ossicles and the defect of the EAC with a piece of cartilage. In case of a small defect of the EAC, a small piece of cartilage may do the job with good results in the future. If the defect is wide, a wedge of cartilage is needed to reconstruct the postero-superior part of the EAC. This closure would not be guaranteed in the coming years since the child is in the phase of growing up and therefore an increase in the dimensions of the area of the EAC is inevitable with a consequence of a high probability of cholesteatoma recidivism and CWD revision surgery would be necessary. As a consequence, the advantages of otoendoscopy as being less invasive and reduce morbidity have been vanished.

Finally, otoendoscopy is a developing technique and it seems to be a promising one but, in the meanwhile, awareness is needed to avoid abusing it. A long-time follow-up is necessary in order to compare the real benefit between the endoscope and the microscope techniques. A good compromise seems to be the use of combined techniques, endoscope and microscope.

## 5. Conclusions

The application of otoendoscopy as an adjunctive tool to operative microscope is a rational strategy in removing the disease. Surgery tends to be less invasive by avoiding mastoidectomy in selected cases and therefore reducing surgical morbidity. Exclusive endoscopic transcanal cholesteatoma removal should be limited to disease interesting only the tympanic cavity. A long-time follow-up is necessary in order to compare the real benefit of endoscopy.

## References

1. Badr-el-Dine M. Value of ear endoscopy in cholesteatoma surgery. *Otol Neurotol* 2002;23(5):631-635.
2. Ayache S, Tramier B, Strunski V. Otoendoscopy in cholesteatoma surgery of the middle ear: what benefits can be expected? *Otol Neurotol* 2008;29(8):1085-1090.
3. Shohet JA, de Jong AL. The management of pediatric cholesteatoma. *Otolaryngol Clin North Am* 2002;35(4):841-851.
4. Marchioni D, Soloperto D, Rubini A, et al. Endoscopic exclusive transcanal approach to the tympanic cavity cholesteatoma in pediatric patients: our experience. *Int J Pediatr Otorhinolaryngol* 2015;79(3):316-322.
5. Lecler A, Lenoir M, Peron J, et al. Magnetic resonance imaging at one year for detection of postoperative residual cholesteatoma in children: Is it too early? *Int J Pediatr Otorhinolaryngol* 2015;79(8):1268-1274.
6. Barakate M, Bottrill I. Combined approach tympanoplasty for cholesteatoma: impact of middle-ear endoscopy. *J Laryngol Otol* 2008;122(2):120-124.
7. Tarabichi M, Nogueira JF, Marchioni D, et al. Transcanal endoscopic management of cholesteatoma. *Otolaryngol Clin North Am* 2013;46(2):107-130. Review.



# COCHLEAR IMPLANTATION IN CHRONIC OTITIS MEDIA

Abdullah Dalgic, Tolgahan Catli, Deniz T. Edizer, Gorkem Atsal, Levent Olgun

*Izmir Bozyaka Training and research Hospital, Otolaryngology Head and Neck Surgery, İzmir, Turkey*

## 1. Introduction

Chronic otitis media (COM) is a chronic inflammation of the middle ear and mastoid cavity.<sup>1</sup> Clinical features are recurrent otorrhoea through a tympanic perforation, with conductive or sensorineural hearing loss of varying severity. COM can cause progressive sensorineural hearing loss. Conventional hearing aids, bone conduction hearing aids, bone-anchored hearing aids, middle ear implantable hearing aids, cochlear implant and brain stem implants are used for hearing rehabilitation after COM surgery. If there is profound sensorineural hearing loss in patients with COM, cochlear implantation may be a good option for hearing rehabilitation.<sup>2</sup> However, there are some difficulties with the cochlear implantation, such as problems with cavity, infection, tympanic membrane perforation in patients with COM.

In this study we present experiences with cochlear implantation in patients with COM.

## 2. Material and Methods

In this retrospective study, 2185 patients implanted at Izmir Bozyaka Teaching and Research Hospital between 1998 and 2016 were evaluated. Fifty-one patients had profound hearing loss due to COM. In six patients, the etiology was not related to COM. Demographic information, side of the ear with COM, radiological findings, pre-operative and postoperative audiological results, operation techniques and stage of the surgery and complications, were recorded.

## 3. Results

Among 2185 CI patients who were operated at our institution, there were 57 (2.6%) COM patients. Patients' age was between 14 and 67 years old (mean age 35). Three of the patients were under 18 years old, one of those had a radical cavity in both ears, the other two had simple perforation in both ears. Eight of the 57 patients were female and 49 were male. Computed tomography and magnetic resonance imaging were performed preoperatively in all patients. Fifty-one of 57 patients had radical cavities in both ears and six of 57 patients COM sequel in both ears. Subfacial insertion was applied 17 patients with radical cavity. Subfacial insertion was done in 12 patients during primary surgery and in five patients during re-implantation. Open mastoidectomy and same-stage cul-de-sac procedure with implantation was performed in six patients. Radical mastoidectomy and same-stage cul-de-sac procedure was the procedure of choice in ten patients and cochlear implantation was achieved in the second

Correspondence: Abdullah Dalgic, MD, Izmir Bozyaka Training and Research Hospital, Otolaryngology Head and Neck Surgery, İzmir, Turkey.

E-mail: dalgicabdullah@gmail.com

*Cholesteatoma and Ear Surgery – An Update 2017, pp. 187-190*

*Edited by Matthew Yung*

*2017 © Kugler Publications, Amsterdam, The Netherlands*



**Table 1.** Hearing results of the patients.

SDS scores	
0-30	3
30-50	9
50-60	28
60-70	14
70-80	3

stage. There were no electrode problems in the six patients with COM sequel. Electrode problems occurred in seven patients with open radical cavities (12.2%). Five of them required re-implantation and two patients are followed-up without any intervention. The hearing results of the patients are shown in Table 1.

#### 4. Discussion

COM can cause mixed conductive and sensorineural hearing loss. Especially in patients with radical cavities, conventional hearing aids can lead to serious problems.<sup>3</sup> Transcutaneous or percutaneous bone-anchored devices and middle ear implants may be a solution for conductive hearing loss.<sup>4</sup> The additional sensorineural component makes hearing rehabilitation more difficult. In case of profound sensorineural hearing loss in patients with COM, cochlear implants can be successful for hearing rehabilitation. The CI technique in COM necessitates some technical modifications.

COM itself and/or the surgical interventions may result in alteration of the normal anatomy of the middle ear. Canal-wall-down cavities can be more challenging to manage. As a general rule, the operative field must be free of infection, otherwise serious intracranial complications may arise. Another important point that is to protect the electrode array adequately. Despite many modifications, the complication rate is still relatively high for cochlear implantation in COM. The standard surgical technique of cochlear implantation should be modified individually.

If a tympanoplasty procedure controls an infection, cochlear implantation at a second stage is preferable. If the patient has a draining ear, the infection should be eradicated and the external ear should be closed at first stage. If the patient already has a draining canal-wall-down cavity, the cochlear implantation should also be staged. However, if the patient has a dry canal-wall-down cavity, either blind sac closure may be chosen or the cavity may be left open. Second-stage procedure also has the advantage of investigating the tympanomastoid cavity for residual and/or recurrent disease.<sup>6</sup> If the surgeon prefers to leave the cavity open, subfacial insertion of an electrode array may be a good option.<sup>6,7</sup>

More posterior placement of the internal receiver transmitter/implant body than usual may be a preventive measure. Similarly, excessive bulking of the electrode array within the mastoid cavity should be prevented.

Fifty-seven patients were implanted after a succesful tympanoplasty. In the ten patients implanted at second stage, cul-de-sac procedure six patients implanted at the same stage with cul-de-sac procedure. The mastoidectomy cavity was left open in 41 patients. In 17 of these patients, subfacial insertion was achieved.

In seven of the patients in which the cavity was left open, the electrode array disrupted the epithelial lining of the cavity. Re-implantation with subfacial insertion of an electrode was neccessary in these patients. Two patients were under follow-up. However, better protection of the electrode array and additional measures which prevent curling of the electrode within the cavity would make subfacial insertion unnecessary. Currently, since our approach to patients with a radical cavity is quite flexible, function results of CI in COM are mostly excellent. It is advised in all cases with profound hearing loss. Combination of COM surgery techniques with CI can give excellent results.

If the cavity is infected because of a subtotal petrosectomy, cul-de-sac closure in second-stage implantation is a rule. If a patient has a dry cavity, the first choice is to leave the cavity open with adequate protection of the electrode array.

## References

1. Acuin J. Chronic suppurative otitis media: burden of illness and management options. Geneva: World Health Organization, 2004. [http://www.who.int/pbd/deafness/activities/hearing\\_care/otitis\\_media.pdf](http://www.who.int/pbd/deafness/activities/hearing_care/otitis_media.pdf) (accessed Jan 28, 2010)
2. Incesulu A, Kocaturk S, Vural M. Cochlear implantation in chronic otitis media. *J Laryngol Otol* 2004;118(1):3-7.
3. Yoo MH, Park HJ, Yoon TH. Management options for cochlear implantation in patients with chronic otitis media. *Am J Otolaryngol* 2014;35(6):703-707.
4. Piché M, Côté M, Philippon D, Laflamme N, Bussi  res R. Cochlear implantation in patients with chronic otitis media and radical mastoidectomy: A single-stage procedure. *Rev Laryngol Otol Rhinol (Bord)* 2014;135(4-5):115-180.
5. Watson GJ, Silva S, Lawless T, Harling JL, Sheehan PZ. Bone anchored hearing aids: a preliminary assessment of the impact on outpatients and cost when rehabilitating hearing in chronic suppurative otitis media. *Clin Otolaryngol* 2008;33(4):338-342.
6. Pan T, Ma FR, Duan JM. Cochlear implant in patient with chronic otitis media after subtotal petrosectomy. *Zhonghua Er Bi Yan Hou Tou Jing Wai Ke Za Zhi* 2010;45(12):1043-1044.
7. Vincenti V, Pasanisi E, Bacciu A, Bacciu S, Zini C. Cochlear implantation in chronic otitis media and previous middle ear surgery: 20 years of experience. *Acta Otorhinolaryngol Ital* 2014;34(4):272-277.



# APPROACH TO PETROUS BONE CHOLESTEATOMA

Tolgahan Catli, Deniz Tuna Edizer, Abdullah Dalgic, Cagri Celik, Levent Olgun

*Bozyaka Teaching and Research Hospital, Izmir, Turkey*

## 1. Introduction

Petrous bone cholesteatoma (PBC), congenital or acquired, is a not uncommon and highly destructive lesion of the temporal bone and various classifications about this pathology have been proposed during the last decades.<sup>1</sup> From the anatomical standpoint, either the lesion arises from the different parts of the temporal bone or different anatomical sites of the temporal bone might be involved during the disease. As a very deep structure of the skull, the petrous bone has very important neighboring bones and tissues and a cholesteatoma mass sited in this area might have challenging consequences. Computed tomography (CT) and magnetic resonance imaging (MRI) have effectively influenced the diagnostic procedures and currently make it possible to treat lesions in a relatively early stage.<sup>2</sup>

## 2. Materials and methods

A retrospective analysis was conducted of the clinical charts of all patients with PBC (n = 89) at Bozyaka Teaching and Research Hospital from 1990 to 2016. During the same period, 2900 cases of cholesteatoma were surgically treated at the same institution. The mean age was 46 years and the age ranged from nine to 83 years old. Basically, the etiology was classified as congenital, acquired and unidentified.

## 3. Results

The preoperative common symptoms were hearing loss (HL) followed by facial nerve weakness (palsy or paralysis). Hearing status of the patients was as follows: pure conductive hearing loss in 14 patients; mixed hearing loss in 43 patients; severe sensorineural hearing loss (SNHL) in 11 patients and profound SNHL in 21 patients. Among 89 patients, seven had preoperative House-Brackmann (HB) grade-III, three had HB-grade IV, four had HB-grade V facial palsy. Ten (n = 10) of these patients with facial palsy got a Bell's palsy treatment elsewhere before the exact diagnosis of PBC. Others had normal facial nerve function pre- and postoperatively. According to Sanna's classification, lesions were classified into massive labyrinthine (n = 41), supra-labyrinthine (n = 37), supra-labyrinthine apical (n = 6), infralabyrinthine (n = 4) and infralabyrinthine apical (n = 1). Chosen procedure was canal-wall-down tympanoplasty in 27 cases and in four of these patients the canal wall was reconstructed with cartilage and in the rest the cavity was left open. A transotic procedure was required in five patients and the transcochlear approach was used to eradicate the cholesteatoma in one. In 38 patients, a subtotal petrosectomy with blind-sac closure (SPBSC) was the preferred technique. In the rest, a radical mastoidectomy was performed. All patients with cul-de-sac closure were followed-up by yearly diffusion MRI. A residual cholesteatoma was detected in two patients and successfully extirpated. All patients with residual disease either with open or closed cavity turned

Correspondence: T. Catli, Saim Cikrikci Street, Karabaglar, Izmir, Turkey.  
E-mail: tcatli80@hotmail.com

*Cholesteatoma and Ear Surgery – An Update 2017, pp. 191 -192*  
*Edited by Matthew Yung*  
*2017 © Kugler Publications, Amsterdam, The Netherlands*

to a cul-de-sac procedure. Apart from these 89 cases, a recurrent or residual cholesteatoma was detected in nine referred cases. Seven of them required a radical mastoidectomy and in two cases a cul-de-sac procedure was performed. Facial nerve functions recovered in nine of the patients who had a facial paralysis before intervention: grade 1-2 in seven and grade 3 in two patients.

#### 4. Discussion

Our experience pointed out once again that CT and MRI have utmost importance in the detection of PBC. Recurrent or progressive facial palsy, deep headache, unilateral recurrent middle ear effusion or acute otitis media may be first signs of a PBC.<sup>3</sup> In these cases, radiological evaluation may allow early diagnosis of lesion. However, clinical practice proves that in our country the majority of PBC cases seek medical treatment in a relatively advanced stage. Eleven of our cases with facial palsy had treatment elsewhere before the diagnosis. To increase the awareness about PBC among general practitioners, pediatricians, neurologists and even otolaryngologists seems to be appropriate.

#### References

1. Yung MW. The use of middle ear endoscopy: has residual cholesteatoma been eliminated? *J Laryngol Otol* 2001;115(12):958-961.
2. Magliulo G. Petrous bone cholesteatoma: clinical longitudinal study. *Eur Arch Otorhinolaryngol* 2007;264(2):115-120.
3. Atlas MD, Moffat DA, Hardy DG. Petrous apex cholesteatoma: diagnostic and treatment dilemmas. *Laryngoscope* 1992;102(12 Pt 1):1363-1368.

# ACTIVE MIDDLE EAR IMPLANTS IN CHRONIC OTITIS MEDIA

Levent Olgun, Deniz T. Edizer, Abdullah Dalgic, Tolgahan Catli, Cagri Celik

*Izmir Bozyaka Training and Research Hospital, Otorhinolaryngology Department, Izmir, Turkey*

## 1. Introduction

Middle ear implantable hearing devices or active middle ear implants (AMIs) amplify sound energy with a complex system. A microphone collects the sound energy and amplifies it. The signal processor converts the mechanical energy to electrical signals and the transducer reconverts the electrical signals to enhanced mechanical signals. The transducer is attached either to ossicular chain or the round window.

Moderate to severe sensorineural hearing loss (SNHL) with a speech discrimination score of more than 50% is the traditional indication of AMI. Since 2005, conductive and mixed types of hearing loss, with a bone conduction not worse than 60 dB HL and a speech discrimination score of more than 50%, have also been considered as indications of AMI. Patients with bilateral mastoidectomy cavities who cannot use conventional hearing aids constitute an important subset of candidates for AMI. Congenital external and middle ear anomalies and recalcitrant chronic external otitis are other less common indications.<sup>1</sup> In case of conductive or mixed types of hearing loss, the middle ear anatomy is generally abnormal either as a result of the disease itself or previous surgery or congenital abnormality. This abnormal middle ear anatomy is associated with an increased risk of complications. In cases with SNHL, where the middle ear anatomy is almost normal, coupling of the middle ear implant to the incus or stapes is preferred.

In standard cases, the body of the implant is fixed over the parietal bone and the transducer is positioned to the incus and/or stapes. Since the middle ear anatomy is generally normal, the complication rate is relatively low. However, in cases where the external and middle ear anatomy have been disturbed by the disease itself or the surgery performed for the disease, as seen in chronic otitis media or otosclerosis, the complication rate is higher.

Proper contact of the transducer with the ossicular chain or round window is mandatory in every active middle ear implantation.

Middle ear implants use a variety of ways to direct vibrations to the inner ear. In some cases, couplers may be used to completely attach the transducer to the short or long process of the incus, stapes or round window. If the middle ear implant is coupled to the round window, the transducer should be perpendicular to the round window membrane and be fixed in proper position with cartilage chips. A coupler aids in proper functioning in case of round window coupling.

## 2. Methods

We retrospectively evaluated the middle ear implantation cases in Izmir Bozyaka Training and Research Hospital between 2008 and 2015. The type and manufacturer of the AMI were noted. The indications of AMI and minor and major complications were recorded.

**Surgical technique:** Previously created canal wall down cavity was exposed with the retroauricular incision. The cavity was reshaped and the epithelial lining was elevated carefully. Round window application of the transducer

Correspondence: Levent Olgun, MD, Izmir Bozyaka Egitim ve Arastirma Hastanesi, KBB Servisi, 35170, Karabaglar – Izmir - Turkey.  
E-mail: leventolgun52@yahoo.com.tr

*Cholesteatoma and Ear Surgery – An Update 2017, pp. 193 -196*

*Edited by Matthew Yung*

*2017 © Kugler Publications, Amsterdam, The Netherlands*



was performed, if the cavity was free of any residual/recurrent disease and/or cholesteatoma. If the cavity had cholesteatoma, subtotal petrosectomy with or without cul-de-sac closure of the external ear was performed. Round window application of the transducer was supported by cartilage strips harvested from the conchal bowl or tragus of the auricle.

Preoperative air and bone conduction hearing thresholds for 500 Hz, 1000 Hz, 2000 Hz, 3000 Hz, 4000 Hz and 8000 Hz were recorded. Mean threshold was calculated by taking the arithmetic mean of the 500 Hz, 1000 Hz, 2000 Hz and 3000 Hz frequencies. Postoperative aided thresholds were also taken for each frequency and gain with AMI was calculated. Postoperative bone conduction thresholds were evaluated in terms of inner ear damage.

### 3. Results

Thirty-one patients (16 female, 15 male) had undergone active middle ear implantation. The mean age was  $45.04 \pm 12.06$ . Vibrant Soundbridge was used in 29 patients; Carina was used in two patients. AMI was performed for bilateral conductive or mixed hearing loss due to bilateral canal-wall-down cavity in 29 patients and sensorineural loss in two patients.

Preoperative and postoperative audiometric (pure tone and speech) evaluations were performed. Preoperative mean air conduction threshold was  $76.23 \pm 16.95$  dB HL. Postoperative mean threshold with active AMI was  $42.93 \pm 14.28$  dB HL. The mean gain was  $33.3 \pm 14.4$  dB HL.

Complications of AMI were electrode exposure (two patients), breakdown of external acoustic canal closure (four patients), gradual sensorineural hearing loss (one patient), recurrence of conductive hearing loss (two patients). Two patients had both external acoustic canal breakdown and electrode exposure. Revision surgery was performed in seven patients: cochlear implantation was performed in patient with gradual SNHL after AMI; reimplantation with AMI in six patients.

### 4. Discussion

Complications of AMIs may be categorized as minor and major. Minor complications are wound problems, exposure of the transducer and/or electrode carrier, recurrent infection in mastoid cavity, conductive hearing loss, necrosis of the incus, changes in the position of the device and difficulty in charging. On the other hand, major complications include exposure of the implant body, extrusion of the implant, sensorineural hearing loss, facial paralysis and transducer disconnection.

Prevention of complications is more important and necessary than management of complications. To eliminate burr contact to the ossicles is very important to prevent SNHL. Likewise, facial nerve monitoring may be effective in preventing facial nerve damage. Chronic otitis media increases the risk of complications.

If there is active inflammation, a canal-wall-down procedure including cartilage tympanoplasty and cul-de-sac closure as well as facial nerve monitoring should be considered concomitant with middle ear implantation. In the presence of active inflammation, subtotal petrosectomy along with cul de sac closure of the ear should be preferred. Obliteration of the canal-wall-down cavity with adipose tissue may provide additional benefits. On the other hand, if the ear is free of any active inflammation, as in the case of tympanosclerosis, cartilage tympanoplasty should be performed to separate the tympanomastoid cavity from the external environment. In both cases, it is better to perform middle ear implantation in a second stage. Mucosa of the posterior part of the cavity should be elevated with caution and AMI may be positioned under the mucosa. Curling of the electrode array may lead to disruption of the mucosa in time which may result in exposition of the AMI.

If the position of the inner part (body of the implant) and the electrode array are not correctly positioned, epithelial lining of the mastoidectomy cavity can be disrupted. Blind sac closure of the cavity should be considered

in these cases.<sup>2</sup>

If the posterior canal wall is intact, the risk of wire link exposure is low, whereas if a canal-wall-down procedure is performed, wire link should be placed in a channel created in the bone and covered with soft tissues.

Many animal and temporal bone studies support the fact that delivery of amplified energy to the cochlea via a transducer located over the RW can have good effects on hearing.<sup>3</sup>

Both stapes and round window applications of AMI were reported to give good hearing results.<sup>4</sup> Although cochlear stimulation from the RW is not a normal sound transmission pathway, the drive produced by the RW membrane is capable to stimulate the auditory pathway.<sup>3,4</sup> Burr contact with the round window, which may lead to SNHL, must be prevented.

Placing the FMT on the stapes was reported to increase the stiffness of the ossicular chain.

The patients with AMI are free from the common side effects of conventional hearing aids including feedback or occlusion effects and have better cosmetic outcomes.<sup>4</sup> The efficacy of the round window implant can be expressed in terms of improved audibility, as determined from comparisons of post-operative unaided and aided AC thresholds, and from pre- and postoperative measures of speech intelligibility.<sup>3</sup>

Ossiculoplasty cannot properly fix the hearing problem in chronic otitis media, which is most apparent in canal-wall-down cavities. Multiple surgeries may sometimes be necessary to eradicate the disease and improve hearing results.<sup>2</sup> Additionally, a cochlear component of hearing loss may coexist which is not generally responsive to middle ear surgery.<sup>2</sup>

Placing the FMT on the RW makes it a sensible alternative for hearing amplification in chronic otitis media. Important points in utilizing AMI in canal-wall-down cavities include the necessity of drilling a channel for electrode array, covering the array with bone pate and/or cartilage and to provide an adequate distance between the implant body and the posterior wall of the canal-wall-down cavity.<sup>5</sup>

## References

1. Vyskocil E, Riss D, Honeder C, et al. Vibroplasty in mixed and conductive hearing loss: comparison of different coupling methods. *Laryngoscope* 2014;124(6):1436-1443.
2. Olgun L, Balaban M, Ozuer MZ, Gultekin G, Uckan B. Round Window Application of Implantable Hearing Aids in Radical Cavities. *J Int Adv Otol* 2008;4(3):191-196.
3. Colletti V, Soli SD, Carner M, Colletti L. Treatment of mixed hearing losses via implantation of a vibratory transducer on the round window. *Int J Audiol* 2006;45(10):600-608.
4. Lee JM, Jung J, Moon IS, Kim SH, Choi JY. Benefits of active middle ear implants in mixed hearing loss: Stapes versus round window. *Laryngoscope* 2016 Aug 25.
5. de Abajo J, Sanhueza I, Giron L, Manrique M. Experience with the active middle ear implant in patients with moderate-to-severe mixed hearing loss: indications and results. *Otol Neurotol* 2013;34:1373-1379.



# ADHESIVE OTITIS MEDIA AND OSSICULOPLASTY

Kadir Serkan Orhan, Beldan Polat, Mehmet Çelik, Hakan Avcı, İbrahim Yağcı, Yahya Güldiken

*Department of ORL, Istanbul Medical Faculty, University of Istanbul, Istanbul, Turkey*

## Abstract

**Objective:** Eustachian tube dysfunction may deteriorate physiology of middle ear pressure and ventilation that result in ear drum retraction. Cholesteatoma can develop from retraction pocket that may result in ossicular erosion. On the other hand, Ossicular erosion may result from prolonged contact between tympanic membrane and ossicular chain without active infection and cholesteatoma.

**Materials and Methods:** Thirty-two patients whose underwent ossicular chain reconstruction with bone cement included in the study. Of these patients 16 had adhesive otitis media. Glass ionomer cement was used for reconstruction by otomicroscope or endoscope. We compared preoperative and postoperative audiogram findings.

**Results:** We found better results of postoperative air conduction thresholds compared to preoperative value ( $p=0.001$ ). In addition, postoperative air bone gap was found to be decreased compare to preoperative level ( $p=0.001$ ).

**Conclusion:** Glass ionomer cement can be safely used for reconstruction of lenticular process erosion in patient with adhesive otitis media.

## 1. Introduction

Eustachian tube dysfunction may deteriorate physiology of middle ear pressure and ventilation that result in ear drum retraction. Cholesteatoma can develop from retraction pocket that may result in ossicular erosion. On the other hand, ossicular erosion may result from prolonged contact between tympanic membrane and ossicular chain without active infection and cholesteatoma.

Long process of the incus, lenticular process and/or stapes superstructure can be effected and result in complete or partial ossicular discontinuity. In lenticular process erosion, bone cement can be used for reconstruction. Incus interposition, malleus-stapes bone cement or ossicular prosthesis are the reconstruction options in case of incus long process erosion.

The aim of the study is to assessed efficacy and safety of bone cement ossicular reconstruction for ossicular discontinuity in patients with adhesive otitis media.

## 2. Material and methods

Between January 2010 and January 2016, the patients with adhesive otitis media underwent bone cement ossicular reconstruction in tertiary university clinic were included the study. Inclusion criteria of the study; preoperative air-bone gap greater than 20 dB, adhesive otitis media, bone cement reconstruction and preserved the external ear canal. Exclusion criteria of the study; chronic otitis media with cholesteatoma, canal wall down tympanoplasty

Correspondence: Kadir Serkan Orhan, MD, Assoc. Prof of ORL, University of Istanbul, Istanbul Medical Faculty, Department of ORL, Istanbul, Turkey.

E-mail: ksorhan@istanbul.edu.tr

*Cholesteatoma and Ear Surgery – An Update 2017, pp. 197 -200*

*Edited by Matthew Yung*

*2017 © Kugler Publications, Amsterdam, The Netherlands*

technique, using the ossicular prosthesis. All the surgeries were performed with endaural approach and tragal cartilage graft was used for tympanoplasty. Informed consent was received from the patients and local institutional board was approved the study (ref no: 2015/826).

Glass Ionomer Cement (GIS) (Espe Dental AG, Seefeld, Germany) was used in all patients. Before the application, remnant squamous epithelium was removed from the ossicles surface. GIS is mixed with its special solution on the slide. When it came to sufficient consistency, it was applied with a fine peak by endoscope or oto-microscope. Aluminum sheet or sponge were used to protect facial nerve and oval window (Figure 1)

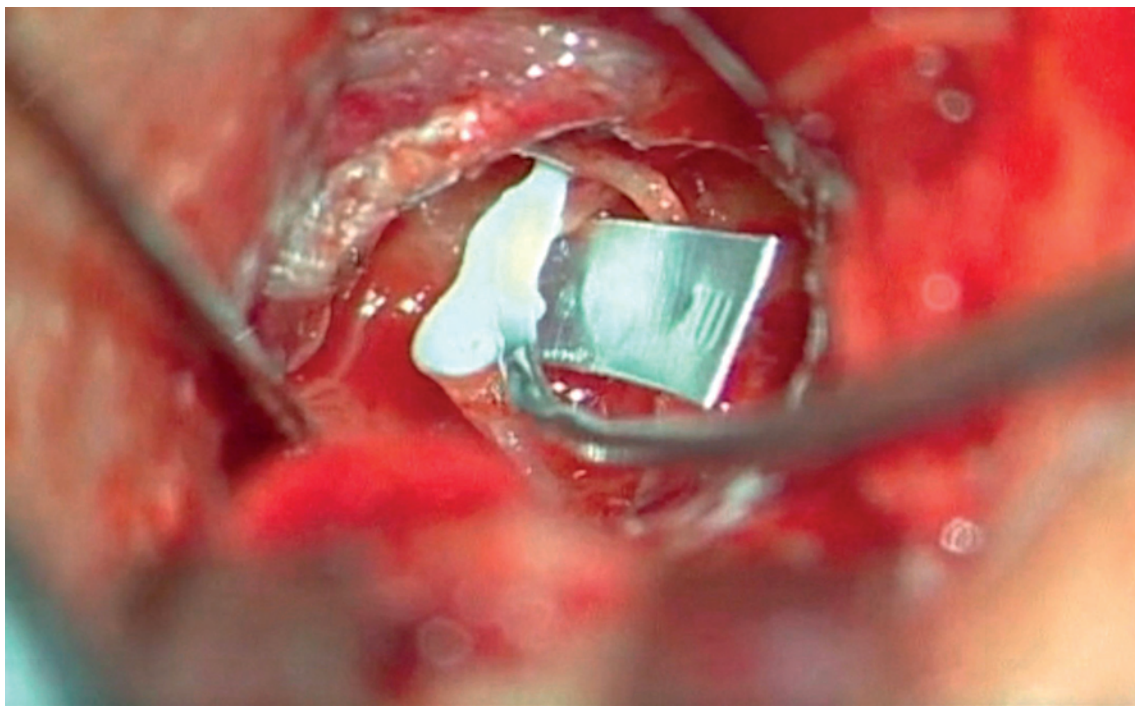
All data was uploaded to SPSS version 17 (SPSS Inc, Chicago, Illinois, USA) Results were expressed as mean  $\pm$  standard deviation (SD). The value of  $P < 0.05$  was accepted as statistically significant in all tests. Wilcoxon test were used to compare between preoperative and postoperative audiological outcomes.

### 3. Results

Fifty-two patients underwent bone cement reconstruction were included the study. Of these patients, 16 had adhesive otitis media. Nine patients were male and another 7 were female. Ages between 16 and 54 years, mean  $\pm$  standard deviation (SD) was  $32.5 \pm 10.2$ .

All applications were applied to stapes-incus reconstruction for erosion of lenticular and or long process of incus. Six patients had malleus long process medialization. No complication was observed intraoperative and postoperative period. Follow up time ranged 6 months and 5 years (mean; 34 months)

Preoperative air conduction threshold was  $41.5 \pm 9.8$  dBHL, postoperative value was  $22.7 \pm 7.1$  dBHL. This difference was statistically significant ( $p = 0.001$ ). Preoperative and postoperative bone conduction thresholds were  $8.1 \pm 6.2$  dBHL and  $5.3 \pm 4.1$  dBHL respectively. This difference was not statistically significant ( $p = 0.12$ ). Preoperative and postoperative air-bone gap were found to be  $33.5 \pm 6.1$  dBHL and  $17.3 \pm 5.7$  dBHL respectively. This difference was statistically significant ( $p = 0.001$ )



*Fig. 1.* Intraoperative view showing the use of an aluminum sheet to protect the facial nerve and oval window during bone cement application.

#### 4. Discussion

Middle ear pressure is regulated by some mechanisms including gas diffusion through the middle ear mucosa, pressure buffer of the mastoid cells and gas exchange through the Eustachian tube.<sup>1</sup> Boyle's law presents that pressure multiplied by volume equals a constant ( $P \times V = C$ ) at a constant temperature. Thus, pressure and volume are inversely proportional.<sup>2</sup> The pressure in a small mastoid volume such as sclerotic mastoid may change more compared to aerated mastoid air cell systems. So, tympanic membrane may remain under force.<sup>3,4</sup>

Eustachian tube, which is a dynamic organ, plays a role of protection, pressure control and clearance of the middle ear. Eustachian tube dysfunction may cause to abnormal middle ear pressure and tympanic membrane retraction, however, it is not only cause of adhesive otitis media. Tympanic membrane structure differs in the anterior and posterior portion of pars tensa. Posterior part has thinner lamina propria and increased vascular supply compared to anterior portion, so posterior part tends to retraction and adhesion.<sup>2,5</sup>

Long process of incus has a single nutrient vessel, which is incudal artery that branch of anterior tympanic artery and has also no collateral circulation. Therefore, Lenticular process and long process are susceptible for aseptic necrosis. Retracted tympanic membrane that attached the incus, inflammation and cholesteatoma may give rise to ossicular erosion and discontinuity.

Glass ionomer cement (GIS) (Ketac-Cem, Espe Dental AG, Seefeld, Germany) has been use for middle ear surgery including ossicular reconstruction, prosthesis fixation in stapes surgery, electrode fixation in cochlear implant surgery and closure of semisircular canal fistula.<sup>6</sup>

GIS has been used for reconstruction of incus long process destruction for many time. Watson GJ and Narayan S. reported in their meta-analysis that the success rate for closure to less than 20 dB varies between 74 and 94.<sup>4</sup> per cent, with success rates appearing to be higher for gaps equal to or less than 2 mm (81.3–94 per cent).<sup>7</sup> In their meta-analysis, GIS was used to perform rebridg- ing ossiculoplasty in 318 patients in 3 comparative studies and 5 case series.<sup>8-15</sup> Closure of air- bone gaps less than 20 dB and less than 10 dB were achieved in 74–94 per cent and 40–76 per cent of cases, respectively. However, closure to less than 10dB was only achieved in 121 patients.<sup>7</sup>

Facial nerve and inner ear should be protected from GIS. Because of chemical reaction and thermal effect may damage to adjunct structures. Transient facial paralysis has been reported in GIS application.<sup>13</sup> In addition, GIS may fracture in long term period.<sup>11,14</sup> Righini-Grunder, Hausler *et al.* reported that inflammatory foreing body reaction were observed in 4.3% of their case series.<sup>6</sup>

GIS can be safely used for ossicular reconstruction for incus long process and lenticular process erosion in patient with adhesive otitis media

#### References

1. Ars, B. (1995). Tympanic membrane. Retraction pocket. *Acta Otorhinolaryngol Belg* 49, 163-171.
2. Danner, C.J. (2006). Middle ear atelectasis: what causes it and how is it corrected? *Otolaryngol Clin North Am* 39, 1211-1219.
3. Buckingham, R.A., and Ferrer, J.L. (1973). Middle ear pressures in eustachian tube malfunction: manometric studies. *Laryngoscope* 83, 1585-1593.
4. Sade, J., Halevy, A., and Hadas, E. (1976). Clearance of middle ear effusions and middle ear pressures. *Ann Otol Rhinol Laryngol* 85, 58-62.
5. Ruah, C.B., Schachern, P.A., Paparella, M.M., and Zelterman, D. (1992). Mechanisms of retraction pocket formation in the pediatric tympanic membrane. *Arch Otolaryngol Head Neck Surg* 118, 1298-1305.
6. Righini-Grunder, F., Hausler, R., Chongvisal, S., and Caversaccio, M. (2015). Glass ionomer cement in otological microsurgery: experience over 16 years. *Eur Arch Otorhinolaryngol* 272, 2749-2754.
7. Watson, G.J., and Narayan, S. (2014). Bone cement: how effective is it at restoring hearing in isolated incudostapedial erosion? *The Journal of laryngology and otology* 128, 690-693.



8. Maassen, M.M., and Zenner, H.P. (1998). Tympanoplasty type II with ionomeric cement and titanium-gold-angle prostheses. *Am J Otol* 19, 693-699.
9. Yazici, H., Uzunkulaoglu, H., Emir, H.K., Kizilkaya, Z., Dogan, S., and Samim, E. (2013). Comparison of incus interpositioning technique versus glass ionomer cement application in type 2 tympanoplasty. *Eur Arch Otorhinolaryngol* 270, 1593-1596.
10. Celik, H., Aslan Felek, S., Islam, A., Demirci, M., Samim, E., and Oztuna, D. (2009). The impact of fixated glass ionomer cement and springy cortical bone incudostapedial joint reconstruction on hearing results. *Acta Otolaryngol* 129, 1368-1373.
11. Rath, G., Bauer, M., Pytel, J., Vona, I., Szanyi, I., Lujber, L., and Gerlinger, I. (2008). Ionomer cement for reconstruction of the long process of the incus: the Pecs experience. *Clin Otolaryngol* 33, 116-120.
12. Baglam, T., Karatas, E., Durucu, C., Kilic, A., Ozer, E., Mumbuc, S., and Kanlikama, M. (2009). Incudostapedial rebridging ossiculoplasty with bone cement. *Otolaryngol Head Neck Surg* 141, 243-246.
13. Bayazit, Y.A., Ozer, E., Kanlikama, M., Durmaz, T., and Yilmaz, M. (2005). Bone cement ossiculoplasty: incus to stapes versus malleus to stapes cement bridge. *Otol Neurotol* 26, 364-367.
14. Hafiz, G. (2005). A more reliable method for incudostapedial rebridging ossiculoplasty: bone cement and wire. *Adv Ther* 22, 56-62.
15. Brask, T. (1999). Reconstruction of the ossicular chain in the middle ear with glass ionomer cement. *Laryngoscope* 109, 573-576.

# THE COMQ-12 AND COMBI QUESTIONNAIRES FOR THE ASSESSMENT OF CHOLESTEATOMA SURGERY OUTCOME

John S. Phillips

*Norfolk and Norwich University Hospitals NHS Foundation Trust, Norwich, UK*

## 1. Introduction

Chronic ear disease is associated with material morbidity and affects approximately 2% of the population.<sup>1</sup> From a clinical perspective, a considered appraisal of patient symptoms is required to assess disease severity, and to appreciate the results of both surgical and non-surgical interventions.<sup>2</sup> The same applies from a research perspective,<sup>3</sup> only more formally. In this context, measures of health-related quality of life (HRQoL) allow a systematic replicable appraisal of need for and benefit from treatment. In current health care policy, emphasis has been on remedying the past lack of outcome information as a tool of quality assurance<sup>4</sup> giving rise to the concept of patient-reported outcome measures (PROMs) mostly intended for routine administration. Two disease specific HRQoL questionnaires have been recently developed for chronic otitis media: the Chronic Otitis Media Questionnaire – 12 (COMQ-12), and the Chronic Otitis Media Benefit Inventory (COMBI).<sup>5,6</sup> The process of questionnaire development for these two important outcome instruments are detailed below.

## 2. The Chronic Otitis Media Questionnaire – 12 (COMQ-12)

The Chronic Otitis Media Questionnaire 12 (COMQ-12) is a 12-item multiple-choice disease specific HRQoL questionnaire.<sup>5</sup> It is a 'static' HRQoL questionnaire as it provides a snapshot of HRQoL specifically at the point of completion. It was developed by a formal process of item reduction from a long list of symptoms. This long list was derived from a literature search and review of questionnaires on symptoms associated with chronic otitis media. Over a period of 12 months this long list was revised progressively using patients' commentaries on two aspects of the item content: (a) topic relevance to patient's symptoms; and (b) comprehensibility of question wordings. The resulting predecessor to the COMQ-12, the COMQ-14 was a provisional list of 14 items. This was reviewed by members of the Clinical Audit and Practice Advisory Group (CAPAG) of ENT-UK (British Association of Otorhinolaryngology – Head and Neck Surgery). The COMQ-12 was then subjected to a rigorous process of psychometric appraisal. Consistency criteria (Cronbach's alpha) and first principle component loadings demonstrated satisfactory scoring with 11 of the original 12 items. The Cronbach's alpha was 0.889 for the COMQ-12, indicating high consistency of items as markers of a common underlying severity of chronic otitis media. The mean of the 12 split-half reliability correlations was 0.817, demonstrating satisfactorily high reliability. A single factor was obtained correlating highly with simple unweighted scoring. Although the COMQ-12 is derived from similar origins to other chronic otitis media questionnaires, it has many advantages over them with respect to the diversity of quality of life domain representation.<sup>5,7</sup>

In another study, the COMQ-12 was given to healthy volunteers, comprising of hospital staff (doctors, nurses, administrative staff), for completion.<sup>8</sup> COMQ-12 scores overall ranged from 0 to 41 with a mean score of 3.4

Correspondence: Mr John S Phillips, Consultant ENT Surgeon, Norfolk & Norwich University Hospitals NHS Foundation Trust, Colney Lane, Norwich, Norfolk NR4 7UY, UK.  
E-mail: john.phillips@mac.com

*Cholesteatoma and Ear Surgery – An Update 2017, pp. 201 -204*

*Edited by Matthew Yung*

*2017 © Kugler Publications, Amsterdam, The Netherlands*

(SD 6.1); for the participants that did not report a history of ear disease, scores ranged from 0 to 15 with a mean score of 1.85(SD 2.94). The median COMQ-12 score overall was 2, and the modal score was 0 with 27(39%) participants achieving this score. Of significance, overall, 83% of respondents achieved a score of 5 or less, 93% of respondents achieved a score of 10 or less out of a possible maximum of 60. As a consequence of this study, we proposed that the 'normal' values defined in this study are seriously considered before contemplating intervention, especially when patients with COMQ-12 scores of 5 or under are considered for surgery.

As a consequence of the ease of application, opportunity for benefit, and favourable psychometric appraisal to date, interest has been demonstrated by a number of otological centres outside the UK. Since the initial publication of the COMQ-12, a Dutch version of the COMQ-12 has been developed.<sup>9</sup> The Dutch version of the COMQ-12 was obtained via an established process of translation and back-translation. The internal consistency of the Dutch version of the COMQ-12 was high, with a Cronbach's alpha value of 0.833.

### 3. The Chronic Otitis Media Benefit Inventory (COMBI)

After the publication of national myringoplasty outcome from the United Kingdom, it became apparent that current HRQoL questionnaires in this field lack documented ability to assess 'responsiveness'.<sup>10</sup> Dynamic assessment tools, such as the somewhat generic Glasgow Benefit Inventory,<sup>11</sup> already exist as popular 'one-shot' instruments. However, until now, a tool that is both dynamic and semi-specific, focusing on the chief domains affected in chronic middle ear disease, has not existed. This was the inspiration behind the development of a 'dynamic' patient-reported outcome measure, which was named the Chronic Otitis Media Benefit Inventory (COMBI).<sup>6</sup>

At the level of item content, the preliminary version of the COMBI was constructed from the same 12 items that form the static instrument, the COMQ-12. Several pieces of work have supported this content for the purposes of developing a chronic otitis media quality of life instrument.<sup>5,7-9</sup> At the level of item format, when 'before' and 'after' data are not collected on separate occasions, items have to elicit a retrospective reflection comparing status between two defined occasions or periods. The item wording was therefore adapted to allow the respondent to report any perceived change in symptoms. Other intervening events are conceivable, but here the prime application envisaged was the consequences of a surgical intervention. The common 5-point numerical response format was used, with two anchoring responses of opposite polarities offered, and one response being neutral, viz: 'much better', 'a little or somewhat better', 'no change', 'a little or somewhat worse', and 'much worse'. To generate preliminary totals in the first round of processing, this scoring was adopted at arithmetic face-value (values 1-5), with a lower score indicating a deterioration in symptoms and a higher score indicating an improvement.

We tested this questionnaire on a clinical population of patients who had undergone surgery for chronic otitis media at two otology secondary care centres in England. The internal consistency of the COMBI was high within our cohort of patients, with a Cronbach's alpha value of 0.907. The factor analysis yielded a readily interpretable three-factor solution explaining 73.6% of the variance.

The COMBI's one-shot format offers convenience over available single-occasion status instruments for chronic middle ear disease that require completion both pre-intervention and post-intervention. Differences obtained by subtraction or baseline adjustment may be more bias-free for research but there are situations where simpler and more accessible methods of questionnaire completion are desired and acceptable.<sup>7,10</sup> The COMBI should not be considered a replacement for the COMQ-12, but as a complementary tool for use in specific situations. The COMBI's brevity and consistent psychometric properties are considered to be particularly useful in applications such as clinical audit.

#### 4. Moving forward to the future

HRQoL measurements reflect the overall burden of disease from the perspective of the patient rather than the clinician. This makes their acquisition particularly pertinent in otology, where single clinical, radiological, and audiological findings may inter-relate poorly, and also poorly predict HRQoL. Furthermore the use of HRQoL measures has been shown to aid both the patient's prioritisation of their symptoms<sup>12</sup> and the management of their individual expectations.<sup>13</sup> In a wider context, ambitions to publish both patient-reported outcomes and objective health markers for the purposes of benchmarking, improving standards, and determining payment to health-care providers have been set out by some European governments.<sup>14</sup> Patient reported outcome measures are also likely to represent an important part of the revalidation process of doctors in the UK.<sup>15</sup> The COMQ-12 and COMBI are positioned to contribute to this development.

For clinical audit purposes, clinical findings, operative details and audiological assessment have been considered essential.<sup>16</sup> However, the three-way dissociation between recurrence rates, auditory measurements, and patient reported symptoms cannot be emphasized strongly enough.<sup>17</sup> Thus, with HRQoL measures gaining acceptance among clinicians, the COMQ-12 and COMBI should complement the data acquired by contemporary clinical audit tools.<sup>16</sup>

Questionnaire development should not be considered as a single process in a single population at a single point in time. High quality questionnaire development evolves over an extended period time, in different populations experiencing the disease being studied. Since the translation and psychometric appraisal of the Dutch version of the COMQ-12, there has been interest expressed from a number of other countries; including Russia, Serbia, Portugal and China. Going forward, we are working with our international colleagues to translate and psychometrically appraise both the COMQ-12 and COMBI with the ultimate aim of acquiring outcome data as an international collaborative exercise.

#### Acknowledgements

We thank Matthew Yung, Mark Haggard, Helen Spencer, Paul Van de Heyning, Vincent Van Rompaey and Eline Oorts.

#### References

1. Nadol JB Jr, Staecker H, Gliklich RE. Outcomes assessment for chronic otitis media: the Chronic Ear Survey. *Laryngoscope* 2000;110(3 Pt 3):32-35.
2. Koller M, Lorenz W. Survival of the quality of life concept. *Br J Surg* 2003;90(10):1175-1177.
3. Koller M, Klinkhammer-Schalke M, Lorenz W. Outcome and quality of life in medicine: a conceptual framework to put quality of life research into practice. *Urol Oncol* 2005;23(3):186-192.
4. Black N. Patient reported outcome measures could help transform healthcare. *BMJ* 2013;346:f167.
5. Phillips JS, Haggard M, Yung M. A new health-related quality of life measure for active chronic otitis media (COMQ-12): development and initial validation. *Otol Neurotol* 2014;35(3):454-458.
6. Phillips JS, Haggard M, Spencer H, Yung M. The Chronic Otitis Media Benefit Inventory (COMBI): development and validation of a dynamic quality of life questionnaire for chronic ear disease. Under peer-review.
7. Phillips JS, Yung MW. A systematic review of patient reported outcome measures for chronic suppurative otitis media. *Laryngoscope* 2016;126(6):1458-1463.
8. Phillips JS, Yung MW. COMQ-12 scores in adult patients without chronic middle ear disease. *Clin Otolaryngol* 2014;39(6):362-367.

9. Oorts E, Phillips J, Van de Heyning P, Yung M, Van Rompaey V. Development of the Dutch version of the health-related quality of life measure for chronic otitis media (COMQ-12). *B-ENT* 2015;11(4):291-295.
10. Phillips JS, Nunney I, Yung MW. Myringoplasty Outcomes in the United Kingdom. *J Otol Laryngol* 2015;129(9):860-864.
11. Robinson K, Gatehouse S, Browning GG. Measuring patient benefit from otorhinolaryngological surgery and therapy. *Ann Otol Rhinol Laryngol* 1996;105:415-422.
12. Nies C, Celik I, Lorenz W, et al. Outcome nach minimal-invasiver Chirurgie. Qualitative Analyse und Bewertung der klinischen Relevanz von Studienendpunkten durch Patient und Arzt. *Chirurg* 2001;72:19-29.
13. Koller M, Lorenz W, Wagner K, et al. Expectations and quality of life of cancer patients undergoing radiotherapy. *J R Soc Med* 2000;93:621-628.
14. Liberating the NHS: Transparency in Outcomes – A Framework for the NHS. Department of Health 2010.
15. Medical Revalidation – Principles and Next Steps. The report of the Chief Medical Officer for England's working group. Department of Health July 2008.
16. Yung M, Gjuric M, Haeusler R, et al.; European Otology Database Project Group. An international otology database. *Otol Neurotol* 2005;26(5):1087-1092.
17. Smyth GD, Patterson CC. Results of middle ear surgery: do patients and surgeon agree? *Am J Otol* 1985;6:276-279.

# DIAGNOSIS, CLASSIFICATION AND SURGICAL MANAGEMENT OF PETROUS BONE CHOLESTEATOMAS: REVIEW OF 200 CONSECUTIVE PATIENTS

Sampath Chandra Prasad, Gianluca Piras, Enrico Piccirillo, Mario Sanna

*Department of Otolaryngology & Skull Base Surgery, Gruppo Otologico, Piacenza – Rome, Italy*

## 1. Introduction

Petrous bone cholesteatomas (PBCs) are slow growing expansile epidermoid lesions arising in the petrous portion of the temporal bone with an incidence of 4-9% of all petrous pyramid lesions. The rarity of these lesions, the slow and silent growth pattern, their complex location in the skull base, the proximity to vital neurovascular structures and the tendency to recur make PBCs very challenging to diagnose and treat. PBCs have shown to be locally aggressive by involving the petrous bone and the areas surrounding it like the clivus, nasopharynx, sphenoid sinus, the infratemporal fossa and even extending intradurally. Also, the close proximity of the disease to the labyrinth and the facial nerve (FN) puts to risk both hearing and FN function which is reflected in the high incidence of FN palsy (34.6%-100%) seen in the important series reported in literature. The classification proposed by Sanna *et al.*,<sup>1,2</sup> which is now widely accepted, divides PBCs into five groups based on the relationship of the disease to the labyrinthine block. Surgery remains the mainstay of treatment of PBCs. The primary objectives in surgical approaches for PBCs, today, is to ensure total disease eradication along with complete control and safety of the surrounding important neurovascular structures. The development of the transotic (TO) and transcochlear (TC) approaches, combined with various other skull base approaches, have helped achieve both these objectives and are considered the mainstay of surgery for PBCs.

## 2. Materials and Methods

Two hundred one cases of PBCs from 200 patients were included in the study, including one patient with bilateral cholesteatoma. The history of presenting illness, clinical examination findings, audiological and radiological examinations, and classification were documented. The type of approach, intraoperative findings and postoperative complications were recorded. The preoperative and postoperative FN function was graded according to the House-Brackmann (HB) grading system.<sup>3</sup> The follow-up period was analyzed for recurrences and late postoperative sequelae. Follow-up was defined as that period of time from surgery to the most recent office visit or patient contact.

## 3. Results and observations

Two hundred forty-six cases of PBCs treated at the Gruppo Otologico were retrospectively analyzed. The incidence of PBCs among all cholesteatomas (7340 cases) in our series was 3.3%. The age of the patients ranged from nine to

Correspondence: Sampath Chandra Prasad, M.S., DNB, FEB-ORLHNS Department of Otolaryngology & Skull Base Surgery, Gruppo Otologico, C/o Casa Di Cura 'Privata' Piacenza spa, Via Emmanueli 42, Piacenza 29121, Italy.  
E-mail: sampathcp@yahoo.co.in

*Cholesteatoma and Ear Surgery – An Update 2017, pp. 205 -208*

*Edited by Matthew Yung*

*2017 © Kugler Publications, Amsterdam, The Netherlands*



83 years with a mean age of 45 years. One hundred forty-one patients were males and 59 were females resulting in a male:female ratio of 2.4:1. The mean duration of follow-up was 6.3 years. Twenty-eight (14%) of the cases were purely congenital, 114 (57%) were acquired and 59 (29%) were iatrogenic PBCs.

**Classification:** Supralabyrinthine PBCs were the most common type with 92 (45.8%) cases followed by the massive PBCs with 72 (35.8%) cases (Table 1). Apical PBCs were rare with just four (2%) of cases in the series. Seven cases (7.6%) of supralabyrinthine PBCs had a limited apical extension. Eight cases had extensions to the clivus, three cases into intradural areas, two cases into the sphenoid sinus and one into the nasopharynx.

Table 1. Sanna classification of PBCs versus the approach used in this series.

SL IL			Sanna classification of PBCs				
			IL-A	M	A	Total	
Surgical Approach	TO		34	6	9	16	1
	MTC	Type A	17	2	2	32	2
		Type B	0	0	1	3	0
	TL		18	1	2	14	0
	STP		17	6	0	3	0
	TM		3	1	0	2	0
	TM+MCF		2	0	0	2	0
	RL+TM		1	2	0	0	0
	IFTA-B		0	0	1	0	1
Total			92 (45.8%)	18 (8.9%)	15 (7.5%)	72 (35.8%)	4 (2%)

Table 2. Preoperative and postoperative FN function versus class of PBCs.

		Sanna classification of PBCs											
	SL		IL		IL-A		M		A		Total		
	Pre	Post	Pre	Post	Pre	Post	Pre	Post	Pre	Post	Pre	Post	
House Brackmann grades	Grade I	45	40	13	12	11	10	25	25	1	0	95 (47.2%)	87 (43.2%)
	Grade II	8	11	1	1	2	2	9	5	1	1	21 (10.4%)	20 (10%)
	Grade III	15	24	3	3	0	1	10	12	0	0	28 (14%)	40 (20%)
	Grade IV	7	3	1	0	0	0	3	7	1	1	12 (6%)	12 (6%)
	Grade V	3	4	0	0	0	0	1	2	0	0	4 (2%)	5 (2.4%)
	Grade VI	14	10	0	2	2	2	24	21	1	2	41 (20.4%)	37 (18.4%)
	Total	92		18		15		72		4		201 (100%)	
SL: Supralabyrinthine; M: Massive; IL: Infralabyrinthine; IL-A: Infralabyrinthine-apical; A: Apical; Pre: Preoperative; Post: Post-operative.													

**Complications:** Postoperatively, 164 (82.8%) of the 198 ears that had various degrees of hearing loss ended up as dead ears. This was an obvious sequela of the surgical approaches chosen for the radical removal of the disease. One patient in this series developed a cerebrospinal fluid (CSF) leak leading on to a brain abscess which was subsequently drained and the patient recovered completely. Recurrence of PBC occurred in seven (3.5%) cases of which three were in previous radical cavities.

#### 4. Discussion

Surgery with radical removal is the mainstay of treatment for PBCs and there is no role for any form of expectant management. An early intervention could possibly result in better FN results and even hearing preservation. Hearing preservation surgeries can be used in limited PBCs of the supralabyrinthine (combined middle cranial fossa-transmastoid approach) and infralabyrinthine (transmastoid-retrofacial approach) varieties. However, it must be noted that in most cases, preservation of the otic capsule is impossible, as experienced by most authors, and this must be taken as the price to pay for achieving total disease clearance and in many cases also for preservation of the FN.

**Management of the FN:** The FN may be skeletonized, re-routed, cut with an end to end anastomosis or grafted with a cable motor nerve.<sup>4</sup> The best possible functional outcome after FN grafting in our series has been a HB grade III. Also, in FN re-routing, the results have been HB grade III or worse in most cases, except in two cases where it was grade II. The depreciation in FN function is because surgical procedure usually involve disruption of the blood supply from the deep petrosal artery near the geniculate ganglion. In another study, we analysed the results of 213 cases where the FN was grafted for all pathologies of the skull base (follow-up greater than one year). The study revealed that petrous bone cholesteatomas had one of the worst outcomes, in which more data will be published later. The reason for this could be the fact that preoperatively, most of the cases presented with varying grades (> HB III) of longstanding FN palsy. In patients with long duration of facial palsy (> 12 months) facial-masseteric nerve grafting or facial-hypoglossal anastomosis is indicated.<sup>5</sup>

**Management of the dura:** The dura is frequently involved in PBCs. The matrix may be adherent to the dura and such cases require special techniques. The first step is to expose the area of the dura involved. Subsequently, the

matrix can be peeled off the dura using a flag or circular knife. In case of adherence, the matrix can be neutralized by gently coagulating over it and the surrounding dura. There is a risk of opening the dura while removing the adherent matrix causing an intraoperative CSF leak. CSF leaks resulting from dural tears do not need special repair but can be swiftly managed by inserting free muscle plugs into the subarachnoid space through the defect and cavity obliteration with fat.<sup>6</sup>

*Management of the jugular bulb:* Dealing with the jugular bulb in cases where it is involved is a well thought out strategy. Preoperative imaging must be carefully analysed for two aspects: the relationship of the lesion with the jugular bulb and the patency of the contralateral venous drainage system by MR venography. In the presence of a hypoplasia of the contralateral venous system, sacrifice of the bulb means occlusion of the main venous drainage of the brain, with the consequent risk of benign intracranial hypertension or venous infarction of the temporal lobe. In such cases damage to the jugular bulb or the sigmoid sinus must be avoided at all cost. However, in cases where the opposite venous drainage is patent, it is safe to occlude the jugular bulb or sigmoid sinus by intra- or extraluminal packing with surgicel if it is damaged during dissection.

*Management of complex cases:* Achieving radical clearance can be difficult in complex cases of PBCs which present with very challenging extensions due to its proximity to vital neurovascular structures. To identify this, we have included a subclassification for extensions into the clivus (C), sphenoid sinus (S), nasopharynx (N) and intradural areas (I). Radical clearance can be achieved even in such complex cases by the addition of an ITFA-type B to a TO approach or one of the modified TC approaches. In case of midline extensions, anterior endoscopic approaches can be used to good effect by combining them with the lateral approaches, either in a single or two staged procedure. In our series, only one complex case had a recurrence near the paraclival internal carotid artery (ICA) which was removed using an anterior endoscopic approach. The details of management are described elsewhere and are beyond the scope of discussion in this article.<sup>5</sup>

## 5. Conclusions

PBCs are a rare and challenging lesions to treat and they require thorough preoperative evaluation and surgical planning and training in lateral skull base approaches. Following a widely accepted classification allows standardization of reporting and in turn formulation of treatment policy. Radical surgery is the treatment of choice and hearing preservation must be a factor secondary to total disease clearance. Active FN management, including re-routing, end-to-end anastomosis and cable nerve grafting consistently come to play in the surgical management of PBCs and postoperative FN results can be satisfactory in most cases. Follow-up has been rendered safe and easy with the development of DWI and other improvements in imaging.

## Reference

1. Abes GT, Abes FLLB and Jamir JC. The Variable Clinical Presentation of Tuberculosis Otitis Media and the Importance of Early Detection. *Otology & Neurotology*. 2011;32:539-543.

# **SUBTOTAL PETROSECTOMY – SURGICAL TECHNIQUE, INDICATIONS, OUTCOMES AND COMPREHENSIVE REVIEW OF LITERATURE**

Sampath Chandra Prasad, Valeria Roustan, Enrico Piccirillo, Mario Sanna

*Department of Otology & Skull Base Surgery, Gruppo Otologico, Piacenza – Rome, Italy*

## **1. Introduction**

Subtotal petrosectomy (STP), with obliteration of the middle ear and mastoid and closure of the external auditory canal (EAC), is an effective solution in mastoid and middle ear diseases that are chronic and recurrent, leave behind a large surgical cavity, exposed vital structures like the dura, carotid, expose inner ear fluids or CSF, with no realistic chance of reconstruction of the conductive apparatus. Although this technique was introduced in the late 1950s and 1960s, Ugo Fisch introduced the term ‘Subtotal Petrosectomy’ in 1965.<sup>1,2</sup> He described STP as the complete exenteration of all pneumatic tracts in the temporal bone including retrofacial, retrosigmoid, antral, retrolabyrinthine, supralabyrinthine, infralabyrinthine, peritubal and pericarotid cell tracts. Although the initial description involved preservation of the otic capsule, it allowed expanding the procedure, when necessary, to exenterate the cochlea, the labyrinth or the internal auditory canal. Blind sac closure of the EAC was recommended but was not mandatory. Over the last couple of decades, there has been a growing interest in STP and the indications for the same has also increased.

## **2. Materials and Methods**

The charts of all patients treated with STP from 1983 to December 2015 were analyzed. At our center, STP is a procedure that is defined by following four important steps: (1) Blind sac closure of the EAC; (2) Canal-wall-down mastoidectomy with complete removal of middle ear disease and removal of all epithelium; (3) Exenteration of the mastoid cells, peri-sigmoid cells, perilabyrinthine cells, perifacial cells and the hypotympanic bone; (4) Retention of the otic capsule, fallopian canal, middle fossa and posterior fossa plates; (5) Obliteration of the surgical cavity with abdominal fat.

*Surgical procedure:* A wide retro-auricular skin incision is used. The muscoloperiosteal flap is shaped and elevated in a T-fashion. The skin of the EAC is exposed and separated from the bone in the superior, posterior and inferior quadrants. The skin is then transected completely in all quadrants at the level of the junction between the bony and cartilaginous portions of the EAC. The skin is then carefully separated from the cartilage all around and is everted outwards. The everted skin is then sutured tightly using 3-0 resorbable sutures. The anterior and posterior edges of the underlying cartilage are also sutured to form a second layer of closure. The medial part of the skin is elevated completely up to the level of the annulus and the tympanomeatal flap is covered by an aluminium foil. A canal-wall-down mastoidectomy is then performed and varying amounts of bone is removed as indicated by the technique. The elevated tympanomeatal flap is then excised completely, making sure that there is non-squamous epithelium left behind. The disease is excised completely. The ossicular chain, except for the stapes (or the infrastructure) is removed. The extent of exenteration of the temporal cell tracts is determined by the extent

Correspondence: Sampath Chandra Prasad  
E-mail: sampathcp@yahoo.co.in

*Cholesteatoma and Ear Surgery – An Update 2017, pp. 209 -214*  
*Edited by Matthew Yung*  
*2017 © Kugler Publications, Amsterdam, The Netherlands*

of disease and the indication of STP. In case of STP for an extensive cholesteatoma, the drilling of cells has to be extensive whereas in case of a STP for a cochlear implant after a radical cavity, the extent of cellular exenteration may be limited. The Eustachian tube (ET) is completely obliterated using periosteum, reinforced with muscle or small pieces of cartilage. This may be cemented in place with bone wax or fibrin glue. The resulting cavity is filled with fat harvested from the abdomen and treated with antibiotic. The 'T' shaped musculo-periosteal flap is then closed with 2-0 Vicryl. The skin is closed in layers. A compressive dressing is applied over the wound.

### 3. Results and Observations

Of the 529 cases that were analyzed, 411 patients were included in the study based on the inclusion and exclusion criteria.

*Pathology (Table 1):* 265 (64.5%) patients had been subjected to multiple surgeries before a STP was performed. In one particular case, the patient had elsewhere undergone two previous myringoplasties, two transtympanic drainage procedures, two canal-wall-up and one canal-wall-down mastoidectomies. The most common indication for STP was recurrent chronic otitis with or without cholesteatoma with 165 (35.9%) patients. Eighty-seven (18.9%) of the 165 cases had erosion of the middle fossa plates and dural exposure. Difficult cases of CI, temporal bone fractures, and Class B3 tympanomastoid paragangliomas were the next most common indications with 91 (19.8%), 43 (9.4%) and 38 (8.3%) cases respectively.

*CI with STP:* The most common indications for CI with STP were previous surgeries and otosclerosis (48.3% and 17.5% respectively). Seventy-six (83.5%) cases underwent a round window insertion, 14 (15.4%) underwent a cochlear turn drill out procedure. Full electrode insertion was possible in all but one (98.9%) case. The most common complication was a CSF gusher seen in two (2.2%) patients.

Table 1. Pathologies for which STP was performed in our series.

Pathology		No. of patients (%)	
Chronic otitis	Without cholesteatoma	21 (4.6)	165 (35.9)
	With cholesteatoma	57 (12.4)	
	Cholesteatoma with dural exposure	87 (18.9)	
Difficult cochlear implantation		91 (19.8)	
Meningoencephalic herniation		64 (13.9)	
Temporal bone fractures		43 (9.4)	
Class B3 tympanomastoid paraganglioma		38 (8.3)	
Petrous Bone Cholesteatoma		22 (4.8)	
Facial nerve tumors		18 (3.9)	
Iatrogenic CSF leak		4 (0.9)	
Meningioma		4 (0.9)	
Carcinoid		2 (0.4)	
External auditory canal malignancies		2 (0.4)	
Petrous apex cholesterol granuloma		1 (0.2)	
Mastoid granuloma		1 (0.2)	
Pleomorphic adenoma		1 (0.2)	
Ewing sarcoma		1 (0.2)	
Langerhans cell histiocytosis		1 (0.2)	
Melanocytoma		1 (0.2)	
Osteoradionecrosis		1 (0.2)	
TOTAL		460 (100)	

Table 2. Details of complications in STP.

Complication	No. of patients (%)	Management	Final outcome at final follow-up
Postaural wound fistula	5 (25)	Repair of fistula	Completely healed in all cases
Insufficient ET closure	4 (20)	Observation	Small pocket of air around the ET orifice seen in radiology. NED in all cases
Residual cholesteatoma	3 (15)	Revision surgery	NED in both cases
Deterioration in FN function	2 (10)	No active intervention	1 recovered to HB grade I
Fistula of blind sac closure	2 (10)	Repair of fistula	Permanent closure in both cases
Retroauricular haematoma	2 (10)	Drainage	Completely healed in both cases
Mastoid abscess secondary to infected fat	1 (5)	Drainage + antibiotics	Completely healed
Electrode extrusion	1 (5)	Reimplantation	CI working successfully
<b>Total</b>	<b>12 (100)</b>		

FN: Facial nerve; NED: No evidence of disease; CI: Cochlear implantation.

*Follow-up and complications (Table 2):* The mean follow-up of the patient pool was 36 months  $\pm$  19 months. Twenty (4.3%) patients had complications. Five (25%) patients had a postauricular wound fistula all of whom were re-operated. The wound was closed with a local musculoperiosteal flap. Three (15%) patients had a recidivism including one case where a STP was done for a FN tumor. All the patients were re-operated and have since remained disease free. There was one case each (5%) of mastoid fat infection and electrode extrusion.

#### 4. Discussion

Today, STP can be deemed as an interface between middle ear and lateral skull base surgery as it allows drilling out the temporal bone more extensively than in routine middle ear surgery. It has also proven to be of benefit in making hearing CI and active middle ear implantation possible in cases that were previously considered contra-indicated.

STP is indicated in any disease primarily in the middle ear and mastoid with limited extensions into deeper parts of the temporal bone that leaves behind a large cavity. Its indications can be described as in Table 3. STP offers an excellent solution in complicated and recurrent cases. There have been reports where unfortunate patients have undergone surgery up to 26 times before a STP offered a permanent solution.<sup>3</sup> In our own series, we have encountered cases with up to eight previous surgeries and it is in such patients that STP offers the maximum benefit. This benefit is more pronounced in patients with good contralateral ear and it also allows underwater activity.

**STP with Implants:** The first series of STP for CI were reported in the mid-1990s when the surgery was staged as a means to look for residuals and also to eliminate chances of infection during CI. However, we believe that a well performed STP enables a simultaneous CI and the surgery must be staged only in case of doubt regarding disease clearance. This philosophy is finding acceptance with more authors.<sup>4-6</sup> The objectives of STP are: (1) To solve chronic infections of middle ear or cavity; (2) To solve CSF leakage and/or the risk of meningitis; (3) To have less risk of extrusion of the array; (4) To have better access and visibility in difficult CI or unfavorable anatomy. Our low complication rates have demonstrated that performing simultaneous STP with CI is a feasible option and should be among the surgical options in CI surgery.<sup>7</sup>



Table 3. Indications for STP.

Indications	Pathology
To eliminate recurrent infection by drilling out multiple air cell tracts and to remove large cholesteatomas but which do not extend deeply into the petrous apex or the internal auditory canal	Chronic otitis media Middle ear cholesteatoma Limited petrous bone cholesteatoma (involving the labyrinth or perilyabyrinthine cells tracts only) Osteoradionecrosis
To remove large tumors without intradural extensions	Tympanomastoid paragangliomas (B2/3) Facial nerve tumors of the tympanic and mastoid portions limited to the mastoid/middle ear cleft Other tumors
To obliterate the middle ear and mastoid cleft from the external environment to eliminate chances of intracranial spread of infection due to exposure of dura, inner ear fluids.	Temporal bone fractures involving the otic capsule Meningoencephalic herniation Iatrogenic CSF leak
To allow CI and AMEI in difficult cases	In chronic otitis (in radical cavity) In Cochlear obliteration and ossifications that require a partial drill out Inner ear malformations Temporal bone fractures involving the otic capsule Revision cases
CI: Cochlear implantation; AMEI: Active middle ear implantation.	

**Complications:** In the early years before the advent of MRI, STP was considered hazardous due to increase incidences of recurrent disease and there was a general hesitancy among surgeons in adopting this procedure. A closed cavity meant that recurrences could not be detected and patients often presented with a facial nerve palsy due to recurrences. However, with the development of MRI and Diffusion Weighted Imaging (DWI) MRI in particular, recurrences as small as two millimeters can now be detected.<sup>8</sup> Refinements in the surgical techniques and better microscopes have also ensured reduction of residuals and recurrences. Our recidivism rates of 15% is less than the reported rates of recidivism in canal-wall-down procedures (with long-term follow-ups) which range from 1.5% to 17%.<sup>9-11</sup> In our series, we had a higher incidence of postaural wound fistula (0.72% in our series) in the initial years. This was because we received a lot of pleuri-operated cases with multiple postauricular incisions and often extensive scarring. The placement of a wide postaural incision and an anteriorly pedicled flap has helped overcome this difficulty. Similarly fistula of the blind sac (10% in our series) has decreased in the last few years in our series owing to a two layered closure of the EAC as described before. The incidence of recidivism is low because STP permits wide bone removal and hence total disease clearance. Further, care taken to ensure that there is no skin of the EAC left behind reduces the incidence of iatrogenic recurrences separate from the original disease.

## References

1. Coker NJ, Jenkins HA, Fisch U. Obliteration of the middle ear and mastoid cleft in subtotal petrosectomy: indications, technique, and results. *Ann Otol Rhinol Laryngol* 1986;95:5-11.
2. Fisch U. *Microsurgery of the Skull Base*. Stuttgart: Georg Thieme Verlag, 1988.
3. Issing PR, Schonemark MP, Winkelmann S, Kempf HG, Ernst A. Cochlear implantation in patients with chronic otitis: indications for subtotal petrosectomy and obliteration of the middle ear. *Skull Base Surg* 1998;8:127-131.
4. Vincenti V, Pasanisi E, Guida M, Di Trapani G, Sanna M. Hearing rehabilitation in neurofibromatosis type 2 patients: cochlear versus auditory brainstem implantation. *Audiol Neurotol* 2008;13:273-280.
5. Henseler MA, Polanski JF, Schlegel C, Linder T. Active middle ear implants in patients undergoing subtotal petrosectomy: long-term follow-up. *Otol Neurotol* 2014;35:437-441.

6. Szymanski M, Ataide A, Linder T. The use of subtotal petrosectomy in cochlear implant candidates with chronic otitis media. *Eur Arch Otorhinolaryngol* 2016;273:363-370.
7. Sanna MF, R, Merkus P, Falcioni M. Subtotal Petrosectomy in Cochlear Implantation. In: *Surgery for Cochlear and other Auditory Implants*, pp. 158-162. Stuttgart: George Thieme Verlag 2016.
8. De Foer B, Vercruysse JP, Bernaerts A et al. Detection of postoperative residual cholesteatoma with non-echo-planar diffusion-weighted magnetic resonance imaging. *Otol Neurotol* 2008;29:513-517.
9. Gantz BJ, Wilkinson EP, Hansen MR. Canal wall reconstruction tympanomastoidectomy with mastoid obliteration. *Laryngoscope* 2005;115:1734-1740.
10. Vartiainen E. Ten-year results of canal wall down mastoidectomy for acquired cholesteatoma. *Auris Nasus Larynx* 2000;27:227-229.
11. Alves RD, Cabral Junior F, Fonseca AC, Bento RF. Mastoid Obliteration with Autologous Bone in Mastoidectomy Canal Wall Down Surgery: a Literature Overview. *Int Arch Otorhinolaryngol* 2016;20:76-83.



# BEYOND MIDDLE EAR

Livio Presutti, Marco Bonali

Otolaryngology-Head and Neck Surgery Department, University Hospital of Modena, Italy

## 1. Introduction

The lateral skull base is a borderline region between the fields of otolaryngology and neurosurgery. Surgical approaches to this area are very challenging, due to many noble structures to preserve, such as the internal carotid artery, otic capsule and facial nerve. Also the complications for pathologies of the internal auditory canal and petrous apex are frequent, because of the need of extensive surgical routes. Moving from the classical approaches that have been created to treat this kind of diseases (*i.e.*, translabyrinthine, retrosigmoid, middle cranial fossa),<sup>1-7</sup>

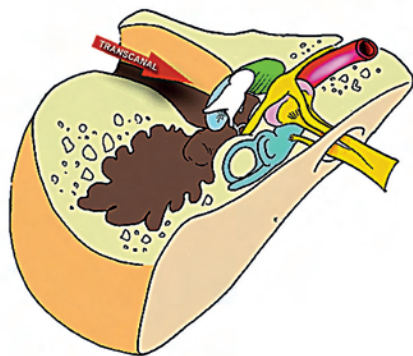


Fig. 1. Drawing showing the transcanal route to the inner ear (red arrow).

we developed combined surgical approaches with the introduction of the endoscope, to reach the inner ear without the brain retraction and the extensive bone removal of the exclusive microscopic classical approaches. In particular, the endoscopic/microscopic association for the retrosigmoid approach reached very useful results to avoid drilling of the posterior aspect of the petrous bone, through the endoscopic control (with angled optics) of the intracanal extension of the pathology.<sup>8-9</sup> Due to the increasingly important role of the endoscopic transcanal surgical approach for pathologies of the middle ear, the next step was the progressive study and validation of exclusive transcanal surgical corridors to inner ear and petrous apex (Fig. 1).<sup>10-12</sup>

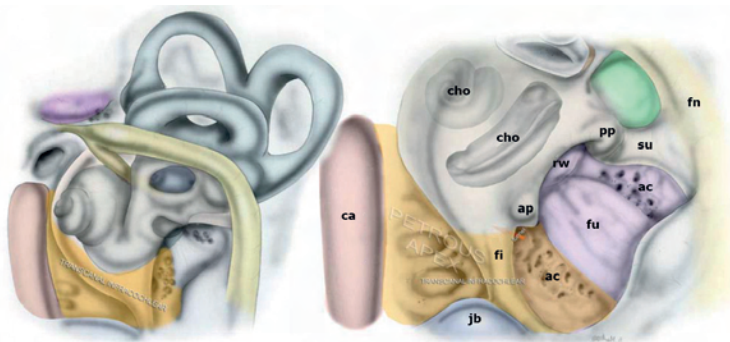


Fig. 2. Left ear. *Left*: Schematic drawing showing the transcanal endoscopic anatomy of the medial wall of the tympanic cavity in relationship to the infracochlear approach (orange area). *Right*: Anatomical details of the infracochlear approach. cho = coclea; ap = anterior pillar; pp = posterior pillar; ca = carotid artery; fi = finiculus; su = subiculum; jb = jugular bulb; rw = round window; fu = fustis; ac = area concamerata; fn = facial nerve.f

## 2. The transcanal infra-cochlear approach<sup>11</sup>

This surgical corridor is employed for pathologies that are located at the level of the petrous apex, inferiorly to the internal auditory canal. Dissection limits for the removal of the disease are: cochlea superiorly, internal carotid artery anteriorly and jugular bulb inferiorly (Fig. 2). Indications to this surgical approach are: cholesterol granuloma of the temporal bone lying inferiorly to the cochlea, with normal preoperative hearing function; cholesteatoma with spread into the subcochlear canaliculus,

Correspondence: Dr. Marco Bonali, Otolaryngology-Head and Neck Surgery Department, University Hospital of Modena, Via del Pozzo 71, 41100, Modena, Italy.  
E-mail: bonamed1984@hotmail.it

*Cholesteatoma and Ear Surgery – An Update 2017, pp. 215 -218*

*Edited by Matthew Yung*

2017 © Kugler Publications, Amsterdam, The Netherlands

under the finculus bone, with extension to petrous apex; cholesteatoma with infiltration of the subtympanic sinus and inferior extension to cochlea. The main steps of this approach, after the tympanomeatal flap creation and the circumferential drilling of the bony portion of external auditory canal, are: identification of the jugular bulb and vertical tract of the carotid artery, drilling of the medial wall of the tympanic cavity between basal turn of the cochlea and jugular bulb in order to reach the pathology, through the subcochlear canaliculus, towards the petrous apex. This kind of surgical corridor allows ossicular chain and postoperative hearing preservation.

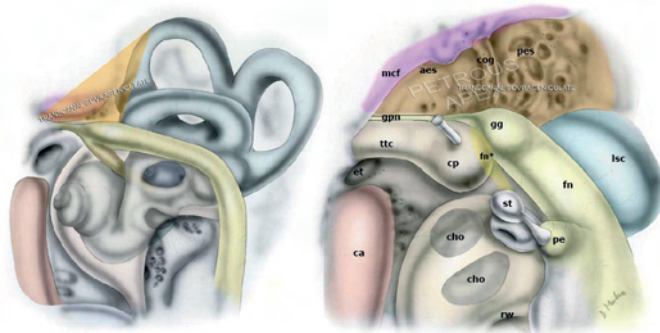


Fig. 3. Left ear. *Left*: Schematic drawing showing the transcanal endoscopic anatomy of the medial wall of the tympanic cavity in relationship to the suprageniculate approach (orange area). *Right*: Anatomical details of the suprageniculate approach. mcf = middle cranial fossa; aes = anterior epitympanum; pes = posterior epitympanum; gpn = great petrous nerve; ttc = semicanal of the tympanic tensor tendon; cp = cochleariform process; gg = geniculate ganglion; fn = facial nerve; fn\* = facial nerve (labyrinthine tract); et = Eustachian tube; lsc = lateral semicircular canal; cho = cochlea; st = stapes; pe = pyramidal eminence; ca = carotid artery; rw = round window.

dura and lateral semicircular canal, is important to better expose the geniculate ganglion area. The amount of drilling between the middle cranial fossa, labyrinthine block and facial nerve, is according to the extension of the pathology. Muscle fragment can be positioned at the end of the disease removal, in order to obliterate the cavity created, and then the ossiculoplasty is performed.

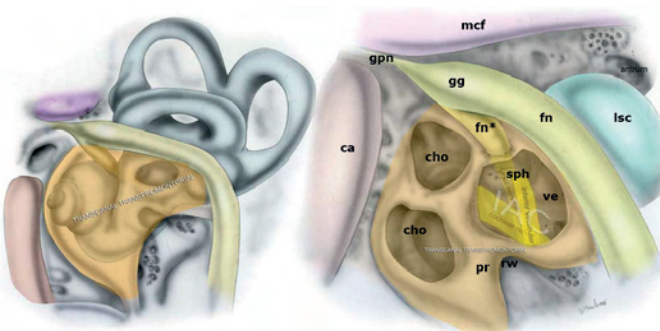


Fig. 4. Left ear. *Left*: Schematic drawing showing the transcanal endoscopic anatomy of the medial wall of the tympanic cavity in relationship to the transpromontorial approach (orange area). *Right*: Anatomical details of the transpromontorial approach. ca = carotid artery; gpn = great petrous nerve; gg = geniculate ganglion; cho = cochlea; mcf = middle cranial fossa; ve = vestibule; sph = spherical recess; rw = round window; pr = promontory; lsc = lateral semicircular canal; fn = facial nerve; fn\* facial nerve (first tract).

### 3. The transcanal suprageniculate approach<sup>11</sup>

The surgical limits of this exclusive endoscopic approach through the external ear canal are: geniculate ganglion and second tract of the facial nerve inferiorly, middle cranial fossa superiorly, labyrinthine block posteriorly (Fig. 3). This surgical corridor allows to avoid classical extensive microscopic approaches, like middle cranial fossa. Because of the pathology to treat (*i.e.*, cholesteatoma) is located above the cochlea and the labyrinth, in this case is possible to preserve the sensorineural hearing, but ossicular chain removal is needed to reach this area. So, ossiculoplasty is mandatory. The main surgical steps are: ossicular chain removal (incus and malleus), in order to expose the second tract of VII cranial nerve and the great petrous nerve. Careful dissection of some structures, like COG (transverse crest), cochleariform process, middle cranial fossa

### 3. The transcanal transpromontorial approach<sup>11</sup>

The introduction and validation of an exclusive transcanal transpromontorial approach to remove pathologies like vestibular schwannomas from the fundus of the internal auditory canal, has changed radically the point of view about this kind of surgery.<sup>10-11,13-14</sup> Indeed, management of vestibular schwannomas is traditionally represented by surgery in case of big masses, small masses with hydrocephalous, or tumors with disabling symptoms. This minimally invasive access through the natural opening of the external auditory canal reduces significantly the amount of bone drilling and neurovas-



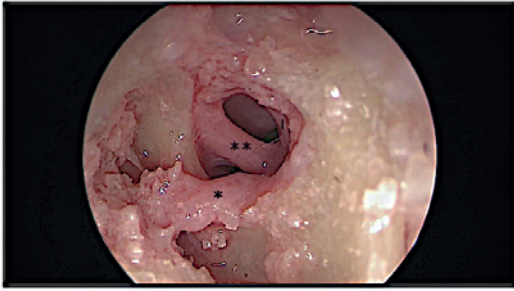


Fig. 5. Cadaveric specimen. Access to the internal auditory canal with exposure of the cochlear (\*), facial (\*\*) and inferior vestibular nerve (l)

cular structures manipulation (Fig. 4), and allows to perform a safe surgical procedure also for small tumors in selected cases, instead of wait and scan policy or gamma knife therapy. The indications to this kind of approach must be chosen very accurately:<sup>15-16</sup> tympanic cavity cholesteatoma with medial extension toward inner ear structures (cochlea, vestibule, IAC); small symptomatic (hearing loss or disabling vertigo) or growing acoustic neuroma with exclusive extension to IAC fundus; cochlear schwannoma with or without IAC involvement; residual acoustic neuroma into the IAC after previous surgery.

The promontory region has to be drilled to reach the fundus of internal auditory canal, cochlea and vestibule, so the hearing loss of the side operated is implicit. Of course, a surgeon who wants to perform this kind of surgery for lateral skull base diseases must own some fundamental prerequisites: experience and knowledge about classical microscopic procedures for inner ear surgery and endoscopic middle ear surgery; confidence with endoscopic dissections and detailed mastery of the anatomical structures from the external to the internal auditory canal. The main surgical steps of this approach are: removal of the ossicular chain, promontory drilling with exposure of cochlear turns and vestibule, access to the internal auditory canal with visualization of facial and cochlear nerve (Fig. 5), dissection of the pathology from the facial nerve into the internal auditory canal. There are some differences between microscopical approaches and transcanal endoscopic transpromontorial approach as regards the postoperative care. In fact, this surgical procedure usually does not require intensive care unit observation and the patient can be extubated immediately after surgery.<sup>15-16</sup>

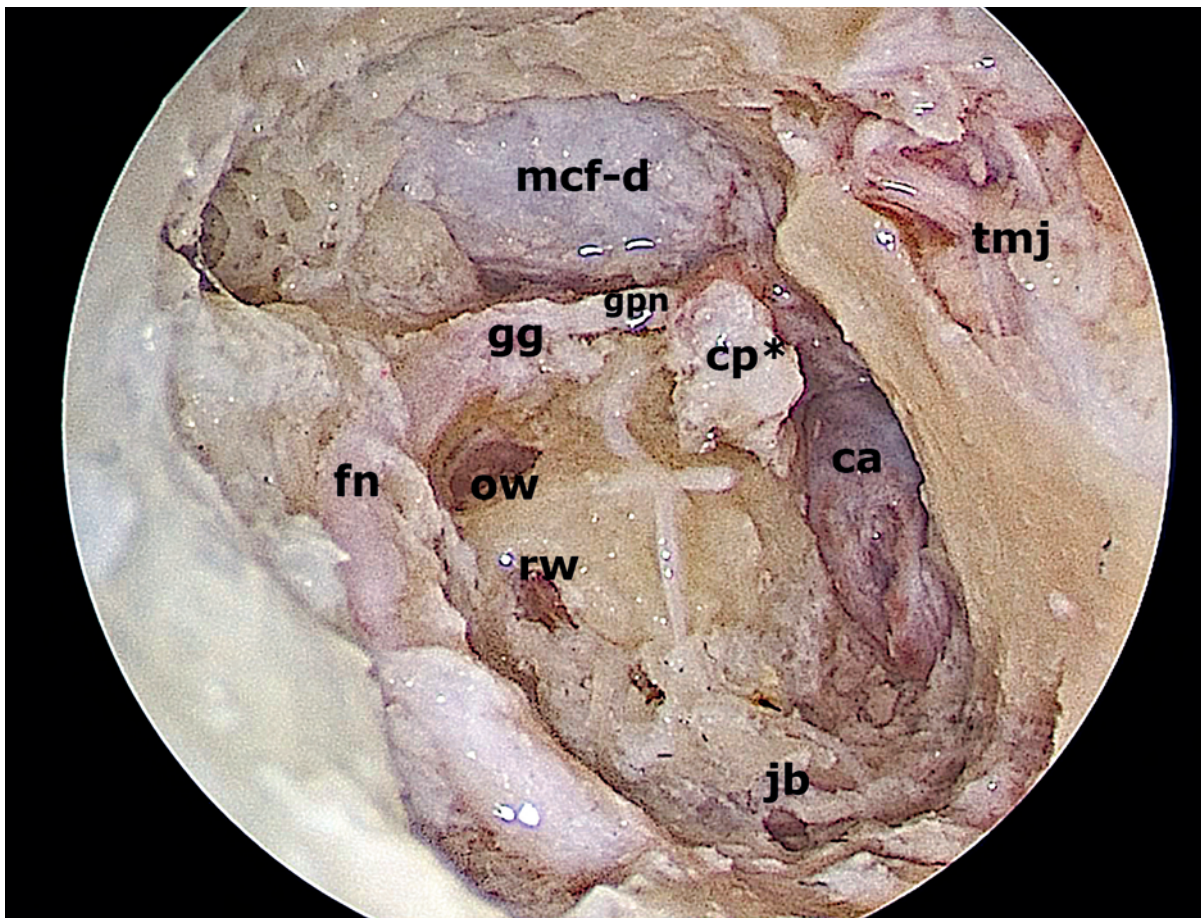


Fig. 6. Right ear. Dissection specimen with the main landmarks of the extended transpromontorial micro/endoscopic approach. fn, facial nerve; rw, round window niche; mcf-d, middle cranial fossa dura; tmj, temporo-mandibular joint; gpn, great petrous nerve; cp, cochleariform process; ow, oval window; gg, geniculate ganglion; ca, carotid artery; jb, jugular bulb.



In case of larger masses with limited extension to the cerebello-pontine angle, we also developed a combined transcanal transpromontorial endoscopic/microscopic approach with an enlarged access route and the careful identification of the main border structures, in order to enhance visibility and improve surgical maneuvers. This expanded surgical approach is based on the skeletonization of some structures around the promontory region: the second tract of the facial nerve superiorly, the vertical tract of the internal carotid artery and the temporo-mandibular joint anteriorly, the jugular bulb inferiorly, the third portion of the facial nerve posteriorly, and the middle cranial fossa dura superiorly (Fig. 6). Moreover, the extended approach also allows to use a microscopic technique and therefore bimanual dissection of the pathology.

## References

1. Bennett M, Haynes DS. Surgical approaches and complications in the removal of vestibular schwannomas. *Otolaryngol Clin North Am* 2007;40(3):589-609.
2. Staecker H, Nadol JB Jr, Ojeman R, Ronner S, McKenna MJ. Hearing preservation in acoustic neuroma surgery: middle fossa versus retrosigmoid approach. *Am J Otol* 2000;21(3):399-404.
3. Day JD, Chen DA, Arriaga M. Translabyrinthine approach for acoustic neuroma. *Neurosurgery* 2004;54(2):391-395.
4. Browne JD, Fisch U. Transotic approach to the cerebellopontine angle. 1992. *Neurosurg Clin N Am* 2008;19:265-278, vi.
5. Chen JM, Fisch U. The transotic approach in acoustic neuroma surgery. *J Otolaryngol* 1993;22:331-336.
6. Rowed DW, Nedzelski JM. Hearing preservation in the removal of intracanalicular acoustic neuromas via the retrosigmoid approach. *J Neurosurg* 1997;86:456-461.
7. Magnan J, Barbieri M, Mora R, et al. Retrosigmoid approach for small and medium-sized acoustic neuromas. *Otol Neurotol* 2002;23:141-145.
8. Presutti L, Alicandri-Ciufelli M, Rubini A, Gioacchini FM, Marchioni D. Combined lateral microscopic/endoscopic approaches to petrous apex lesions: pilot clinical experiences. *Ann Otol Rhinol Laryngol* 2014;123(8):550-559.
9. Magnan J, Chays A, Lepetre C, Pencroffi E, Locatelli P. Surgical perspectives of endoscopy of the cerebellopontine angle. *Am J Otol* 1994;15(3):366-370.
10. Marchioni D, Alicandri-Ciufelli M, Mattioli F, et al. From external to internal auditory canal: surgical anatomy by an exclusive endoscopic approach. *Eur Arch Otorhinolaryngol* 2013;270(4):1267-1275.
11. Marchioni D, Alicandri-Ciufelli M, Rubini A, Presutti L. Endoscopic Transcanal Corridors to the Lateral Skull Base: Initial Experiences. *Laryngoscope* 2015;125:S1-S13.
12. Presutti L, Nogueira JF, Alicandri-Ciufelli M, Marchioni D. Beyond the Middle Ear. Endoscopic Surgical Anatomy and Approaches to Inner Ear and Lateral Skull Base. *Otolaryngol Clin North Am* 2013;46(2):189-200.
13. Presutti L, Alicandri-Ciufelli M, Cigarini E, Marchioni D. Cochlear Schwannoma Removed Through the External Auditory Canal by a Transcanal Exclusive Endoscopic Technique. *Laryngoscope* 2013;123(11):2862-2867.
14. Komune N, Matsuo S, Miki K, Rhoton Jr. AL. The endoscopic anatomy of the middle ear approach to the fundus of the internal acoustic canal. *J Neurosurg* 2016;2:1-10.
15. Marchioni D, Carner M, Rubini A et al.. The Fully Endoscopic Acoustic Neuroma Surgery. *Otolaryngol Clin North Am* 2016;49:1227-1236.
16. Marchioni D, Alicandri-Ciufelli M, Rubini A, et al. Exclusive endoscopic transcanal transpromontorial approach: a new perspective for internal auditory canal vestibular schwannoma treatment. *J Neurosurg* 2016;11:1-8.

# RETRACTION POCKETS – ENDOSCOPIC APPROACH

Livio Presutti, Marco Bonali

*Otolaryngology-Head and Neck Surgery Department, University Hospital of Modena, Modena, Italy*

The great advantage of the endoscope in exploring the middle ear is that it allows to explore a wider part of the tympanic cavity, especially with the angled lenses, and the magnification of the image provides more anatomical details. This has led to a better understanding of the middle ear ventilation routes. Moreover, the possibility to look behind the corner is very helpful to control spreading routes of pathologies like cholesteatoma, in relationship to anatomical variations as well.

First of all, it has to be underlined that the middle ear mucosa plays an important role in gas homeostasis, and preservation of mastoid mucosa is important for maintaining the gas exchange function. But there is also the Buffer effect. In fact, based on Boyle's law, small mastoid volumes tend to cause greater changes in pressure and may develop compensatory mechanisms like atelectasis of the TM.<sup>1</sup>

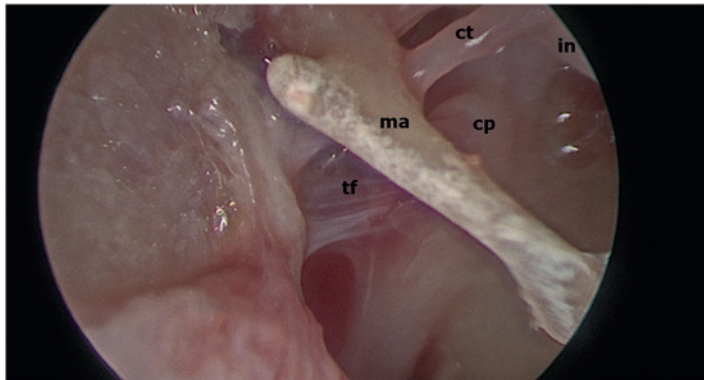


Fig. 1. Left ear. Endoscopic evaluation of the tensor fold area. tf = tensor fold; ma = malleus; ct = chorda tympani; cp = cochleariform process; in = incus.

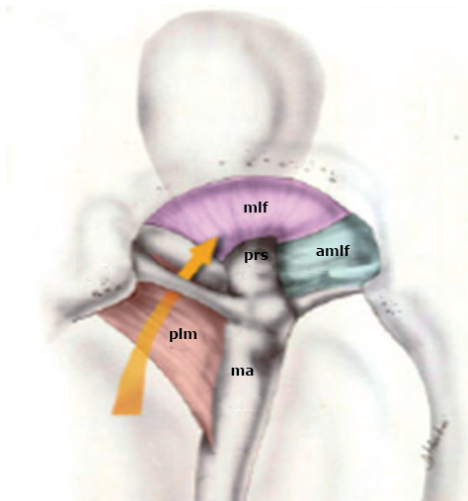


Fig. 2. Schematic drawing representing the limits of Prussak's space. mlf = lateral malleolar fold; plm = posterior malleolar ligament; amlf = anterior malleolar ligament fold; ma = malleus; prs = Prussak's space.

In literature, Palva and colleagues<sup>2-6</sup> studied the anatomy of the epitympanum in relationship to some mucosal folds. In particular, they underlined the role of tensor fold, that extends from the semicanal of the tensor tympani muscle to the lateral aspect of epitympanum, and delimited anteriorly by the root of zygomatic bone and posteriorly by the cochleariform process and by the tensor tympani tendon (Fig. 1). It lies between sovratubular recess and anterior epitympanum

and in some cases can be incomplete, (creating an alternative ventilation pathway to the attic).

Palva also described the Prussak space as a separate area that can play a role in creating retraction pockets. This space, is delimited laterally by Sharpnell's membrane, medially and inferiorly by neck and short process of the malleus, superiorly by lateral malleolar fold and posteriorly by posterior pocket of Von Tröltsch (Fig. 2).

Another author, Chatellier,<sup>7</sup> was the first to analyze the concept of 'epitympanic diaphragm', that is made up of three malleolar ligaments (anterior, lateral and posterior), by the posterior incus fold and by two duplicated membranous fold (tensor fold and lateral incudomalleal fold) associated with the incus and the malleus) (Fig. 3).

Correspondence: Dr. Marco Bonali, Otolaryngology-Head and Neck Surgery Department, University Hospital of Modena, Via del Pozzo 71, 41100, Modena, Italy.  
E-mail: bonamed1984@hotmail.it

*Cholesteatoma and Ear Surgery – An Update 2017, pp. 219 -222*

*Edited by Matthew Yung*

*2017 © Kugler Publications, Amsterdam, The Netherlands*

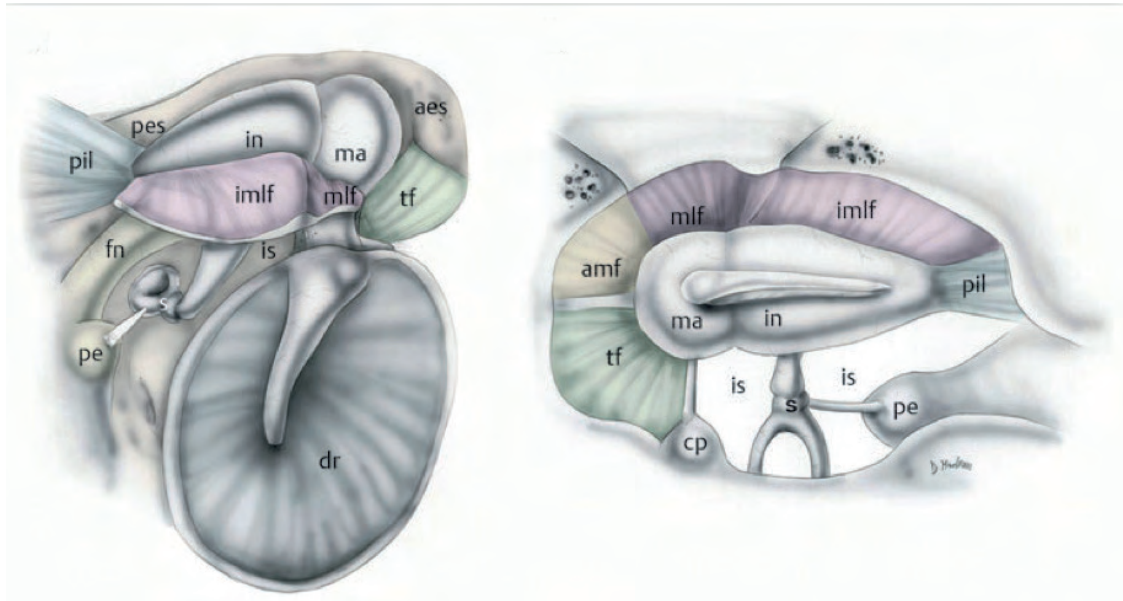


Fig. 3. Schematic drawing showing the epitympanic diaphragm and the isthmus region. Pil = posterior incudal ligament; pes = posterior epitympanum; in = incus; ma = malleus; aes = anterior epitympanum; imlf = incudo-malleolar lateral fold; mlf = malleolar lateral fold; tf = tensor fold; fn = facial nerve; is = isthmus; pe = pyramidal eminence; dr = eardrum; amf = anterior malleolar fold; s = stapes; cp = cochleariform process.

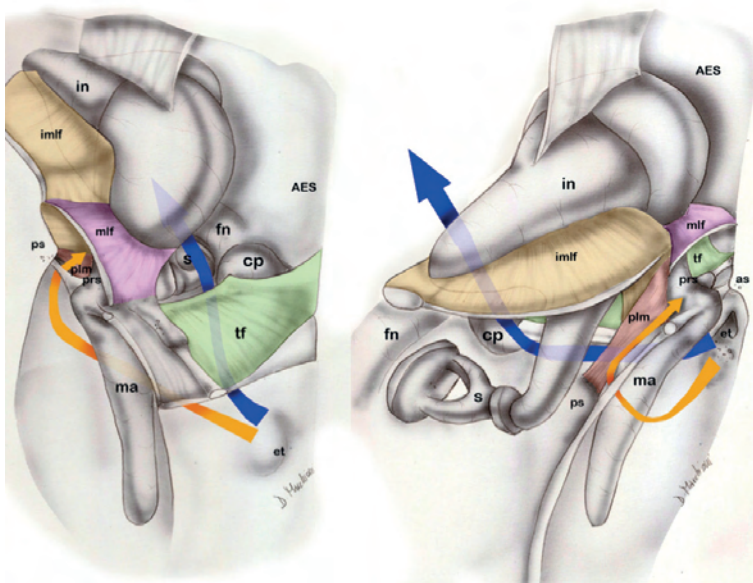


Fig. 4. Schematic drawing showing the ventilation routes to epitympanic compartments (orange arrow) and Prussak's space (blue arrow). tf = tensor fold; fn = facial nerve; s = stapes; in = incus; ma = malleus; prs = Prussak's space; et = Eustachian tube; AES = anterior epitympanic space; imlf = lateral incudomalleal fold; mlf = lateral malleal ligamental fold; cp = cochleariform process; plm = posterior malleal ligamental fold; amlf = anterior malleal ligamental fold; pil = lateral and medial posterior incudal ligament.

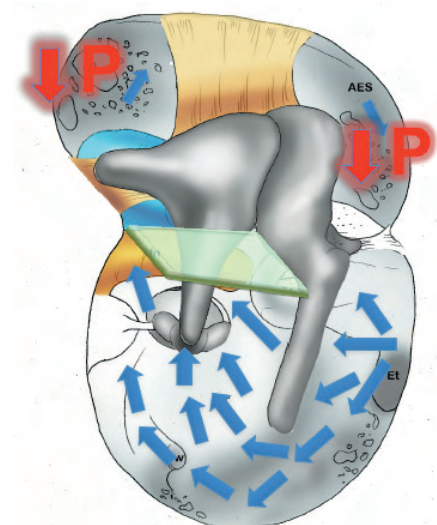
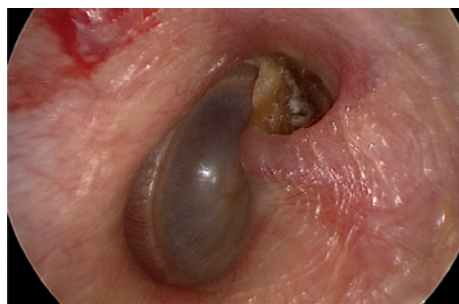

Fig. 5. Schematic drawing showing the concept of pressure decreasing in selective epitympanic dysventilation syndrome.

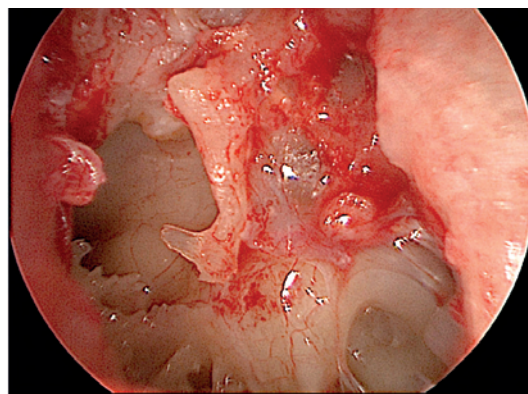
Another important region to analyze is the isthmus; this region provides the main ventilation to the epitympanic compartments, and is located between the medial part of the posterior incudal ligament and the tensor tympani tendon. However, the isthmus area which provides the better aeration for the attic ends posteriorly at the level of the incudo-stapedial joint.

So, we can consider two independent ventilation routes.<sup>8-10</sup> The first is through the tympanic isthmus and is for the superior attic. The second is for the Prussak space and passes through the posterior pocket of Von Trötsch (Fig. 4). This concept is very important for the transcanal endoscopic middle-ear surgery, because the restoration





*Fig. 6.* Left ear. Endoscopic evaluation of the tympanic membrane. Epitympanic retraction pocket with epidermization is clearly seen.



*Fig. 7.* Left ear. Endoscopic reconnaissance of the tympanic cavity. A complete isthmus blockage is present and the ventilation flow is completely excluded from epitympanic compartments.

of ventilation pathways through the creation of a large tympanic isthmus and an accessory route through the tensor fold is the basis of this surgery.

Tympanic isthmus can be blocked by congenital folds, inflammatory webs or granulation tissue and in these cases the main ventilation route to the epitympanic compartments is altered. This event can lead to a progressive pressure reduction in the epitympanum with a consequent selective dysventilation of the epitympanum, despite a regular airflow from the Eustachian tube (Fig. 5). This is the reason why some endoscopic evaluations show a normal mesotympanic ventilation with an isolated epitympanic retraction pocket.<sup>11-13</sup>

In case of an attic cholesteatoma with blockage of the isthmus (Fig. 6), exploration of the tympanic cavity with endoscopic optics allows to better assess the regular airflow from the tubaric region, and to remove the mucosal fold in the isthmus region (Fig. 7). Another region to explore and to eventually open is the tensor fold area, in order to restore the entire ventilation to the epitympanic compartments. So, the endoscopic approach for retraction pockets provides a more detailed visualization of the anatomical structures, with the possibility not only to remove the pathology, but also to treat the cause which led to the ventilation disorder.

## References

1. Presutti L, Marchioni D. Endoscopic Ear Surgery. Principles, indications and techniques. 1st ed. Georg Thieme Verlag KG; 2005.
2. Palva T, Johnsson L. Epitympanic compartment surgical considerations: reevaluation. *Am J Otol* 1995;16:505–513.
3. Palva T, Ramsay H. Incudal folds and epitympanic aeration. *Am J Otol* 1996;17:700–708.
4. Palva T, Ramsay H, Bo'hling T. Tensor fold and anterior epitympanum. *Am J Otol* 1997;18:307–316.
5. Palva T, Bo'hling T, Ramsay H. Attic aeration in temporal bones from children with recurring otitis media: tympanostomy tubes did not cure disease in Prussak's space. *Am J Otol* 2000;21:485–493.
6. Palva T, Ramsey H. Aeration of Prussak's space is independent of the supradiaphragmatic epitympanic compartment. *Otol Neurotol* 2007;28:264–268.
7. Chatellier HP, Lemoine J (1946) Le diaphragme interatticotympanique du nouveau-ne. *Ann Otolaryngol Chir Cervicofac* 1946;13:534–566.
8. Marchioni D, Alicandri-Ciufelli M, Grammatica A, Mattioli F, Genovese E, Presutti L. Lateral endoscopic approach to epitympanic diaphragm and Prussak's space: a dissection study. *Surg Radiol Anat.* 2010;32:843-852.
9. Marchioni D, Molteni G, Presutti L. Endoscopic Anatomy of the Middle Ear. *Indian J Otolaryngol Head Neck Surg* 2011;63(2):101–11.
10. Marchioni D, Bonali M, Presutti L. Endoscopic Middle Ear Anatomy. *Curr Otorhinolaryngol Rep* (2015) 3:200–208.
11. Marchioni D, Alicandri-Ciufelli M, Molteni G, Artioli FL, Genovese E, Presutti L. Selective epitympanic dysventilation syndrome. *Laryngoscope.* 2010;120(5):1028-1033.

12. Marchioni D, Grammatica A, Alicandri-Ciufelli M, Aggazzotti-Cavazza E, Genovese E, Presutti L. The contribution of selective dysventilation to attical middle ear pathology. *Med Hypotheses*. 2011;77(1):116-120.
13. Marchioni D, Mattioli F, Alicandri-Ciufelli M, Presutti L. Endoscopic approach to tensor fold in patients with attic cholesteatoma. *Acta Otolaryngol*. 2008;25:1-9.

# THE GENETICS OF CHOLESTEATOMA PROJECT

Peter Prinsley<sup>1</sup>, Carl Philpott<sup>1</sup>, Barbara Jennings<sup>1</sup>, Mahmood Bhutta<sup>2</sup>

<sup>1</sup>University of East Anglia Norfolk UK; <sup>2</sup>Royal Perth Hospital W Australia

## 1. Background

Cholesteatoma is a lesion of the ear, formed of a mass of stratified keratinizing squamous epithelium.<sup>1</sup> It arises from the lateral epithelium of the tympanic membrane, and then grows as a self-perpetuating mass into the middle ear, causing local tissue destruction. This often includes destruction of the ossicles (bones of hearing), which can lead to a hearing loss of up to 60 decibels. The only available treatment for cholesteatoma is surgery, comprising tympanomastoidectomy to remove or exteriorize disease. Around 7,000 such procedures are performed in the UK each year,<sup>2</sup> both in children and adults, with each procedure typically requiring two to three hours under general anaesthesia<sup>3</sup> at an estimated cost to the NHS of over £14 million. Tympanomastoidectomy is often successful in removing cholesteatoma but the restoration of hearing, even with the use of ossicular prostheses, is less assured. Only 60-70% of patients with cholesteatoma will recover functional hearing after tympano-mastoidectomy,<sup>4</sup> and hearing is a major determinant of quality of life after such surgery.<sup>5-7</sup>

The aetiology of cholesteatoma remains elusive. Chronic otitis media in childhood predisposes to development of cholesteatoma,<sup>8,9</sup> but only a small proportion of those with chronic otitis media will develop cholesteatoma. Animal models confirm the role of chronic mucosal inflammation in inducing cholesteatoma,<sup>10-12</sup> but have also failed to illuminate how or why this occurs. There is mounting evidence that predisposition to cholesteatoma has a genetic basis. Despite this being a rare disorder (1:10,000 per year), those who develop cholesteatoma have a 7% chance of developing disease in the contralateral ear.<sup>13</sup> In addition several authors, including a member of our team, have described familial clustering of cholesteatoma.<sup>14-16</sup>

We completed a systematic review to collate the evidence that the condition may be inherited as a genetic trait in some families. The protocol used was registered with the PROSPERO International prospective register of systematic reviews database in June 2015.<sup>17</sup> We concluded that we should accommodate the hypothesis that a range of aetiological pathways exist for cholesteatoma and that these may result in disease sub-types that differ in both severity and tractability.<sup>18</sup>

## 2. Aims and objectives

To identify genetic pathways predisposing to cholesteatoma.

## 3. Proposed methods

We have already identified a number of families with multiple individuals affected by cholesteatoma. This includes three sets of identical twins. Whereas this already represents what is likely to be a very informative group for genetic analysis, we will seek to refine the cohort to use in this study. Hence our first step will be to contact

Correspondence: Peter Prinsley, Consultant ENT Surgeon, 26 Eaton Rd, Norwich, Norfolk NR4 6PZ, UK.  
E-mail: Peter.prinsley@jpaget.nhs.uk

*Cholesteatoma and Ear Surgery – An Update 2017, pp. 223 -226*  
*Edited by Matthew Yung*  
2017 © Kugler Publications, Amsterdam, The Netherlands



otologists across the UK to identify other families, so that we can use those that we deem most informative. We aim to recruit between 20 and 40 families across the UK with an estimated five to ten family members available to participate; including affected and non-affected individuals. Once these families are identified we will write to them to invite their participation in this study. Those who are willing to participate will be invited either to attend their local hospital, or to have a research nurse visit them. For each family we will complete pedigree analysis, and then collect bloods for DNA or saliva (Oragene kits) from affected and non-affected individuals. For families that are some distance from the hospital we will instead conduct an interview by phone and collect DNA by posting the Oragene kits.

The next stage of the study will deploy whole exome sequencing coupled to a linkage analysis strategy to leverage the participation of families in which cholesteatoma is segregating. In conjunction with the pedigree mapping, we will have an unprecedented opportunity to identify genetic polymorphisms predisposing to formation of cholesteatoma, and by using multiple affected families, to identify recurrent pathways or genes identified through this methodology.

Our working protocol accommodates a spectrum of etiologies of cholesteatoma; from multifactorial (with a small genetic contribution) to oligogenic; and with a few outlier families demonstrating cholesteatoma as a Mendelian trait with incomplete penetrance. There is great potential for us to make rapid progress in our aims, by enriching for individuals who may fall into this latter group; by recruiting families with several affected individuals and those with bilateral disease.

The power of genome sequencing studies is correlated with the number of exome sequencing reactions undertaken and strategies can be followed to efficiently prioritize which individual genomes within an affected kindred should be sequenced. A large-scale sequencing experiment will allow us to capture data from all available participants who are affected with cholesteatoma, and several unaffected controls within each kindred.

Inclusion of data collected from unaffected controls reduces the risk of technical (sequence calling) errors leading to false positive results. And exploiting the co-segregation of variants with the disease phenotype, in comparison with data from unaffected participants, helps to distinguish causal and non-causal genetic variation.

#### 4. Timescale and progress so far

- A research team has been assembled that includes ENT surgeons with disease-specific expertise and academic delivery, geneticists and research nurses.
- A systematic literature review has been completed and submitted for publication.
- The Cambridge Research Ethics Committee has approved the entire project including sequencing and Health Research Authority (HRA) approval has been given with adoption of the study on to the NIHR portfolio.
- The British Society of Otolaryngology support the project and have identified a number of further collaborative centers that wish to recruit participants to the study.
- Peter Prinsley has been accepted as an MD student at the University of East Anglia (UEA)
- The team meets regularly and will issue interim reports of activity to the funding charities
- It is anticipated that preliminary results will be available within the two-year timescale of the MD.

#### References

1. Bhutta MF, Williamson IG, Sudhoff HH. Cholesteatoma. *BMJ* 2011;342:d1088.
2. Health and Social Care Information Centre. Hospital Episode Statistics, Admitted Patient Care, England - 2012-13. Leeds 2013.
3. Rowlands RG, Harris R, Hern JD, Knight JR. Day-case paediatric mastoid surgery. *Int J Pediatr Otorhinolaryngol* 2003;67(7):771-775.

4. Stankovic MD. Audiologic results of surgery for cholesteatoma: short- and long-term follow-up of influential factors. *Otol Neurotol* 2008;29(7):933-940.
5. Choi SY, Cho YS, Lee NJ, et al. Factors associated with quality of life after ear surgery in patients with chronic otitis media. *Arch Otolaryngol Head Neck Surg* 2012;138(9):840-845.
6. Nadol JB, Jr, Staecker H, Gliklich RE. Outcomes assessment for chronic otitis media: the Chronic Ear Survey. *Laryngoscope* 2000;110(3 Pt 3):32-35.
7. Jung KH, Cho YS, Hong SH, et al. Quality-of-life assessment after primary and revision ear surgery using the chronic ear survey. *Arch Otolaryngol Head Neck Surg* 2010;136(4):358-365.
8. Spilsbury K, Miller I, Semmens JB, Lannigan FJ. Factors associated with developing cholesteatoma: a study of 45,980 children with middle ear disease. *Laryngoscope* 2010;120(3):625-630.
9. Djurhuus BD, Christensen K, Skytthe A, Faber CE. The impact of ventilation tubes in otitis media on the risk of cholesteatoma on a national level. *Int J Ped ORL* 2015;79(4):605-609.
10. Huang CC, Shi GS, Yi ZX. Experimental induction of middle ear cholesteatoma in rats. *Am J Otolaryngol* 1988;9(4):165-172.
11. Vassalli L, Harris DM, Gradini R, Applebaum EL. Propylene glycol-induced cholesteatoma in chinchilla middle ears. *Am J Otolaryngol* 1988;9(4):180-188.
12. Masaki M, Wright CG, Lee DH, Meyerhoff WL. Experimental cholesteatoma. Epidermal ingrowth through tympanic membrane following middle ear application of propylene glycol. *Acta Oto-laryngol* 1989;108(1-2):113-121.
13. Rosenfeld RM, Moura RL, Bluestone CD. Predictors of residual-recurrent cholesteatoma in children. *Arch Otolaryngol Head Neck Surg* 1992;118(4):384-391.
14. Prinsley P. Familial cholesteatoma in East Anglia, UK. *J Laryngol Otol* 2008:1-4.
15. Homoe P, Rosborg J. Family cluster of cholesteatoma. *J Laryngol Otol* 2007;121(1):65-67.
16. Podoshin L, Fradis M, Ben-David Y, et al. Cholesteatoma: an epidemiologic study among members of kibbutzim in northern Israel. *Ann ORL* 1986;95(4 Pt 1):365-368.
17. Jennings B, Bhutta M, Philpott C, Willis G, Prinsley P. Genetics and cholesteatoma 2015. [http://www.crd.york.ac.uk/PROSPERO/display\\_record.asp?ID=CRD42015023579](http://www.crd.york.ac.uk/PROSPERO/display_record.asp?ID=CRD42015023579)
18. Jennings BA, Prinsley P, Philpott C, Willis G, Bhutta MF. The genetics of cholesteatoma. A systematic review using narrative synthesis. *Clin Otolaryngol*. 2017;00:1–13.



# SURGICAL TECHNIQUE FOR BONEBRIDGE IMPLANTATION IN YOUNG CHILDREN WITH PREVIOUS MASTOIDECTOMY DUE TO CHRONIC SUPPURATIVE OTITIS MEDIA

Ángel Ramos-Macias<sup>1</sup>, Daniel Perez-Plasencia<sup>1</sup>, Elena Muñoz Pascual<sup>2</sup>, Marta Bastarrica Martí<sup>2</sup>, Angel Osorio Acosta<sup>1</sup>

<sup>1</sup>Department of ENT, Hospital Universitario de Gran Canaria, Insular y Materno Infantil, Universidad de Las Palmas de Gran Canaria, Spain; <sup>2</sup>MED-EL Spain

## Abstract

The percutaneous bone-anchored hearing aids have been implanted in adults and children to treat conductive and mixed hearing losses. The main disadvantages of these implants are related to the percutaneous abutment and subsequent skin problems. An alternative to this kind of devices is the active transcutaneous bone conduction implant, BONEBRIDGE (BB), whose results are comparable to the percutaneous system, due to the same direct drive stimulation, but there is no risk for the skin. In order to stimulate the bone directly, the stimulator is placed under the skin and into a bone bed in the mastoid area. A minimum bone thickness is required to fit the implant into the bone and it is more difficult depending on the size of the mastoid or the previous surgeries. This is of particular importance in children who have undergone a radical mastoidectomy. This paper describes the surgical technique used in a case of a child with a previous radical mastoidectomy. The position of the implant into the bone was located behind the sigmoid sinus and three main points were considered: the incision, the bone thickness, and the dura mater and sigmoid sinus.

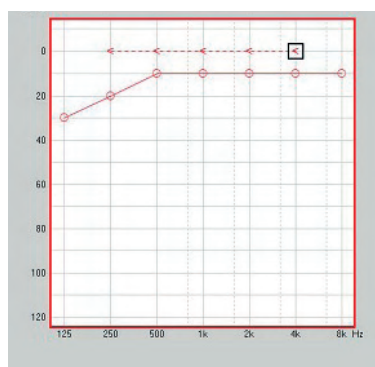


Fig. 1. Pure-tone audiogram pre-implantation. Red curves: bone and air conduction of right ear. Blue curves: bone and air conduction of left ear.

## 1. Introduction

Patients with conductive or mixed hearing loss who are unable to wear conventional hearing aids due to external and/or medium ear malformation, chronic otitis media for example, are usually treated with percutaneous bone anchored devices. The main disadvantages of these devices are related to percutaneous abutment, including skin reactions, wound infection, growth of skin over the abutment, and implant extrusion, with major complications in up to 37% of the children, requiring revision surgery or removal of the implant.<sup>1</sup>

The Bone Conduction implant (BCI) BONEBRIDGE (MED-EL, Innsbruck, Austria) system is the first active transcutaneous bone conduction hearing aid. In addition, it allows the skin to remain intact, without abutment, avoiding wound infection or implant extrusion, maintaining an outcome similar to percutaneous bone anchored hearing systems.<sup>2</sup>

The BONEBRIDGE (BB) is composed of an external audio processor with directional microphone and battery, and an internal part, the BCI, which contains the BC-FMT (Bone Conduction – Floating Mass Transducer). It has a cylindrical shape with a diameter of 15.8 mm and a depth of 8.7 mm; this part has to be embedded into the

Correspondence: Prof. Angel Ramos, ENT Dept. University Hospital Gran Canaria, Av Dr Pasteur s.n., Las Palmas - Spain.  
E-mail: ramosorl@idecnet.com

*Cholesteatoma and Ear Surgery – An Update 2017, pp. 227 -232*

*Edited by Matthew Yung*

*2017 © Kugler Publications, Amsterdam, The Netherlands*

temporal bone. The BCI generates a vibration that is transmitted directly into the bone and subsequently into the internal ear, via the two screws that maintain fixed the BCI to the skull. The screws do not need osseointegration before the implant activation. Consequently this allows an earlier activation than in percutaneous bone anchored implants.

The BC-FMT of the BONEBRIDGE is connected by a flexible transition to the electronic housing, the coil and the magnet, integrated in a silicone covering. The flexible transition can be bent up to 90° horizontally and 30° vertically to fit properly to the skull anatomy during the implantation.

To get a better placement into the mastoid and to reduce drilling depth, the manufacturer can provide additional spacers, called lifts, which elevate the BC-FMT from the temporal bone plane. There are four lift sizes, ranging from one mm to four mm. They can be inserted under the wings of the BC-FMT. If lifts are used, longer screws are also used to ensure adequate skull fixation.

The BB was approved with the CE mark for implantation in children at age of five years and above having demonstrated significant improvements in the pure tone and speech recognition in silence and noise.

The characteristics of BONEBRIDGE make the system a good option for children suffering conductive hearing loss due to malformation or chronic otitis media.

The BC-FMT fits in most adult patients,<sup>3</sup> but it depends on the size of the mastoid, the pathology and previous surgeries. For the placement of the BB system, a bone thickness of at least four mm is required to prevent damage of the meninges, firstly because of the deep bed for the BC-FMT and secondly because of the screws insertion requirement. It is intended since children with thin skin may be susceptible to pressure damage over time.

## 2. Case description

A six-year-old male child with conductive hearing loss (Fig. 1) in the left ear secondary to a radical mastoidectomy due to an extensive middle ear cholesteatoma. The canal-wall-down technique was used maintaining the air bone gap. A conventional hearing aid was tried with an unsatisfactory adaptation, inconsistent use and no optimal results. A BB implantation was then performed in 2015 at the Otolaryngology Department in the Canary Islands Insular – Maternity and Children University Hospital Complex (Las Palmas de Gran Canaria).

The bone conduction threshold fits with the audiological criteria for BB, better than 45 dB in 500, 1000, 2000 and 4000 Hz.

The CT scan of the temporal bone shows a complete absence of the middle ear structures with a complete mastoidectomy. The sigmoid sinus was just 1.7 mm behind the edge of the cortical area of the mastoidectomy. Nothing further was found.

As there was a mastoid radical cavity, there was not enough bone for placing the implant into the mastoid. The alternative location was the retrosigmoid area. A radiological planning was done before the implantation in order to find the best location for the BC-FMT and screws.

Due to the mastoid cavity, the theoretical location recommended for the implantation in this case was posterior to the sigmoid sinus area, about five mm from the temporal line and skin suture, using the mastoidectomy edge as a reference for the implantation. Minimum thickness of skull at the optimal place for the FMT was 4.3 mm.

A small incision of an *inverted italic* S-shape was made one cm above from the upper theoretical projection of the external auditory canal (EAC), parallel to the temporalis muscle over the previous tympanoplasty incision. During the surgery, a pocket was created for the placement of the system as well as a small muscle-periosteal flap to cover the region of the lower screw, facing the mastoid tip.

The bone bed was drilled using a cylindrical burr (0.5 cm) and diamond burr for drilling close to the meninges and sinus, creating a bone island in the middle of the bed, with an exposition of the dura of one mm along the edge of the cortical drilled, in order to protect the structures and give more flexibility to the implant adjustment. The bed depth was checked with the T-sizer template. Four-mm lifts were used to accommodate the implant into the

bone enabling the BCI wings to be positioned over the bone. As an additional protection, small pieces of 'spongostan' were placed along the dura edges.

After the implant fixation, the flap closure was performed with cutaneous and subcutaneous absorbable sutures.

At three months after the implantation the free-field threshold (PTA4) in aided condition was 3.7 dB HL (Fig. 2). The speech discrimination was 90% at 65 dB, masking contralateral ear.

### 3. Discussion

Depending on the anatomical characteristics, three main approaches for the BCI placement have been described; these are via the mastoid, retrosigmoid approach and middle fossa.<sup>4</sup> Choosing one of the three approaches depends on the mastoid anatomy, the sinus position, previous surgeries and pathology.

When the BB is considered for children who present a complete mastoid, the BC-FMT and the screws can be placed in the mastoid region itself, in order to avoid both the dura and the sigmoid sinus. Even when the size of the mastoid is not large enough, exposing these structures does not mean a larger problem.

This possibility disappears when the volume of available bone in the sinodural angle for the implant is reduced. An alternative could be a placement lower than the mastoid tip. However in young patients it is more complex due to the curvature, size of the mastoid tip and the fact that pneumatization is not completely developed at young ages.<sup>5</sup> It is a spongy, weak and bleeding bone, preventing the correct cylinder drilling required for placing the BC-FMT.

In this case, when there is not enough space in the pre-sigmoidal mastoid region, the retrosigmoid approach is an option. Mainly it could be indicated for patients who have undergone previous mastoidectomy for chronic otitis media or cholesteatoma, with radical mastoidectomy.<sup>4</sup>

In the case of previous mastoidectomy in children, the mastoid may present itself as modified when it is compared to that of healthy mastoid reference, Habesglu *et al.*<sup>6</sup> reported that the mastoid volume values in the chronic otitis media group were significantly smaller when compared with those of a healthy group, while there were no significant differences between groups when they assessed Henle spine-sigmoid sinus (HS-SS) distances.

In planning the BB surgery, it is necessary to check the bone size and references for the BCI implantation to avoid damaging the sinus and dura mater. Also necessary is a TAC analysis, using 2D and 3D reconstruction, measuring the mastoid volume, the sigmoid sinus and dura mater disposition in the temporal bone.<sup>7</sup>

The surgical planning can be performed using the software BBFastView<sup>8</sup> developed by the Center for Technical Studies and Research at the University of Navarra, Spain. It allows finding a correct placement of the BC-FMT according to the patient's anatomy, using a full-scale template, even to measure distances and angles to recommend a possible location for the implant bed, avoiding the sigmoid sinus, dura mater and external auditory canal. This prior radiological planning allows for the programming of the placement of the BCI, preventing possible complications during the surgery. Law *et al.*<sup>9</sup> demonstrated that in the majority of the patients who had undergone a previous radiological study, their implant surgeries were performed according to the initial proposed site.

For adequate fixation of the BC-FMT, the screws must be placed within healthy, corticated and trabeculated bone in the skull to a minimum depth of four mm.<sup>9</sup>

With respect to the radiological planning, three points must be considered in children with previous mastoidectomy: (1) the surgical incision; (2) the thickness of the temporal scale; and (3) the location of the meninges and sigmoid sinus.

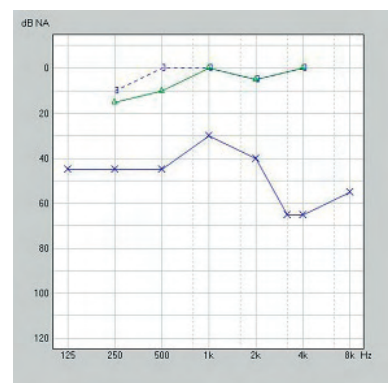


Fig. 2. Green curve: free field audiogram in aided condition three months after implantation. Blue curves: bone and air conduction of left side. Contralateral ear was masked during both measurements.



### 3.1. Surgical incision

Possible surgical problems could arise mainly from the type of the surgical incision, especially when considering previous surgery. To avoid skin vascularization problems by increased pressure in the area, a small incision is made. This is done to avoid touching any part of the implant. The incision starts in the upper projection of area of the CAE and it stretches one cm above. A parallel incision to the temporalis muscle is made in order to create a pocket for the placement of the system, and a small muscle-periostic flap to cover the region of the lower screw, which is facing the mastoid tip, is also created.

### 3.2. The thickness of the temporal scale

A certain thickness of the retrosigmoid area is required to fit the BC-FMT (8.7 mm); exposure and depression of the posterior fossa dura is usually required to fit the BC-FMT, without postoperative complications.<sup>2,4,9,10</sup>

The screws need a minimum of four mm of depth to avoid the soft tissues. In the anatomy of the temporal bone in children under five years, the 1-mm post-sigmoid sinus region is about 20% thicker than the rest of the temporal scale; therefore this region is suitable for placing the screws.

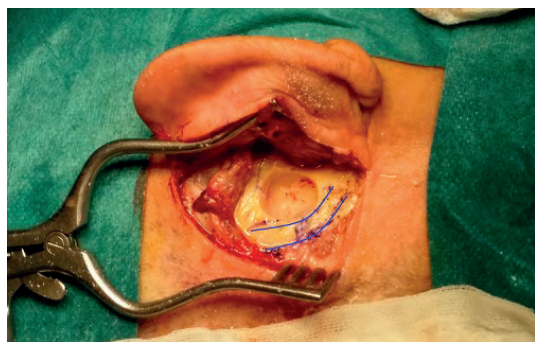

Fig. 3. Upper blue mark: mastoidectomy edge. Area between the marks: sigmoid sinus area.

### 3.3. Meninges and sigmoid sinus location

A cylindrical bed has to be drilled in the area of the meninges and sigmoid sinus. Damaging the meninges and the sinus must be avoided (Fig. 3). Any damage can be caused mainly for two reasons. The first is the consequence of drilling. To prevent this, it is recommended to use diamond burs when drilling close to these structures, and to create a bone island to protect them from aspiration. Also, when drilling at the edge of the implant bed, a cylindrical polished diamond burr and intense irrigation could be used. The second cause of potential damage is injury due to depressing the meninges through inferior traction.

Anteriorly and close to the sinus, the access to the bone is higher and far from the meninges. Therefore, and as an additional protective measure, a lyophilized dura wedge or similar material as spongostan is recommended, allowing for the separation of the lower edge of the drilled bed from the meninges. This protects the meninges itself and allows for greater flexibility when placing the BC-FMT.

The above recommendations for the implant bed creation enable a better BC-FMT adaptability, the creation of sufficient bone space for the screws, and the avoidance of skin pressure – all of which makes the proper placement of the BB possible.

## 7. Conclusion

BONEBRIDGE is a solution for the treatment of the conductive or mixed HL in chronic suppurative otitis media for very young children. The radiological planning is useful in cases of previous mastoidectomies. The surgical procedure in these cases is the retrosigmoid approach. The retrosigmoid approach allows going away from the pathology and subsequent revisions. In this retrosigmoid area is important the manipulation of the previous incision to avoid problems of drilling scarring, constant protective measures when drilling near the dura and avoiding the implant contact with the wound to not increase the pressure on the skin.

Direct drive stimulation from the BB to the bone allows better quality of hearing, without feedback and without pressure on the skin with predictable results.

As transcutaneous system, the skin remains intact and the audio processor location is in the optimal position respecting to the pinna.

## References

1. Kraai T, Brown C, Neeff M, Fisher K. Complications of bone-anchored hearing aids in pediatric patients. *Int J Pediatr Otorhinolaryngol* 2011;75(6):749-753.
2. Hassepass F, Bulla S, Aschendorff A, et al. The BONEBRIDGE as a transcutaneous bone conduction hearing system: preliminary surgical and audiological results in children and adolescents. *Eur Arch Otorhinolaryngol* 2015;272(9):2235-2241.
3. Rahne T, Seiwerth I, Götze G, et al. Functional results after BONEBRIDGE implantation in adults and children with conductive and mixed hearing loss. *Eur Arch Otorhinolaryngol* 2015;272(11):3263-3269.
4. Zernotti ME, Sarasty AB. Active bone conduction prosthesis: BONEBRIDGE(TM). *Int Arch Otorhinolaryngol* 2015;19(4):343-348.
5. Rahne T, Schilde S, Seiwerth I, et al. Mastoid dimensions in children and young adults: consequences for the geometry of transcutaneous bone-conduction implants. *Otol Neurotol* 2016;37(1):57-61.
6. Habesoglu TE, Habesoglu M, Toros SZ, et al. How does childhood otitis media change the radiological findings of the temporal bone? *Acta Otolaryngol* 2010;130(11):1225-1229.
7. Güldner C, Heinrichs J, Weir R, et al. Visualisation of the BONEBRIDGE by means of the CT and CBCT. *Eur J Med Res* 2013;18(1):30.
8. Borro D, Amundarain A, Manrique M. BB Fast View: Implantable devices planning tool. <http://www1.ceit.es/cg/bbfastview> . Accessed November 4, 2016.
9. Law EK, Bhatia KS, Tsang WS, Tong MC, Shi L. CT pre-operative planning of a new semi-implantable bone conduction hearing device. *Eur Radiol* 2016;26(6):1686-1695.
10. Lassaletta L, Calvino M, Zernotti M, Gavilán J. Postoperative pain in patients undergoing a transcutaneous active bone conduction implant (BONEBRIDGE). *Eur Arch Otorhinolaryngol* 2016 DOI 10.1007/s00405-016-3972-y.



# CANAL-WALL-DOWN MASTOIDECTOMY WITH AND WITHOUT AUTOLOGOUS BONE OBLITERATION: A COMPARISON OF RESULTS IN ADULTS

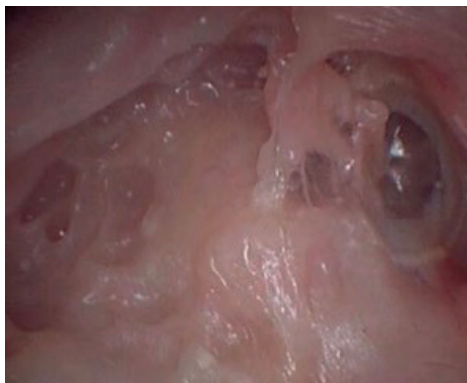Luca O. Redaelli de Zinis, Francesco Mancini, Tommaso Sorrentino, Daniela Tonni

*Department of Medical and Surgical Specialties, Radiological Sciences and Public Health  
Section of Otorhinolaryngology Head Neck Surgery, University of Brescia, Italy*

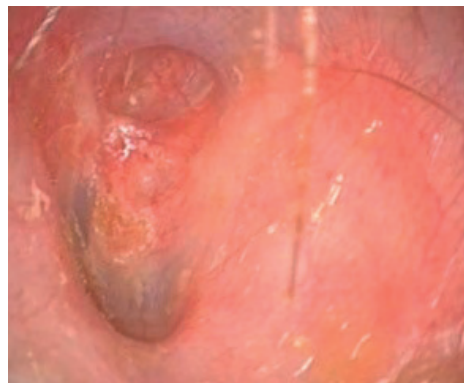
## 1. Introduction

The surgical treatment goals for cholesteatomatous otitis media are complete disease eradication, achievement of a dry and self-cleansing ear, creation of anatomic conditions that prevent recurrence, and preservation of hearing.<sup>1</sup> There are two basic surgical approaches to treat cholesteatoma: canal-wall-up (CWU) and canal-wall-down (CWD) mastoidectomy with tympanoplasty. CWU tympanoplasty has a short healing time, preserves both the normal anatomy of the ear canal and the normal volume of the middle ear and requires less post-operative care.<sup>1</sup>

CWD mastoidectomy is credited to low cholesteatoma recidivism, however, drainage and infection of the mastoid bowl is sometimes a complication of surgery.<sup>1</sup> Obliteration with autologous bone of the mastoid cortex can avoid the disadvantages of the CWD approach by combining the benefits of a smaller cavity less prone to infections. The aim of the study was to compare anatomical and functional results of non-obiterated CWD mastoidectomy (NO-CWDM) (Fig. 1) and obliterated CWD mastoidectomy (O-CWDM) (Fig. 2).



*Fig. 1. Right canal wall-down mastoidectomy: dry irregular surface of the mastoid cavity and deep retraction of the epitympanic region.*



*Fig. 2. Left canal wall-down mastoidectomy with bone pate obliteration of the mastoid bowl: small cavity with smooth surface and mild retraction of the epitympanum.*

## 2. Methods

Consecutive CWDM from 1994 to 2014 have been reevaluated to analyze incidence of postoperative synechiae and recurrent infections of the mastoid bowl, retraction pocket and perforation of the neotympanum, recurrence of cholesteatoma, and hearing threshold change.

Correspondence: Dr. Luca O. Redaelli de Zinis. Piazzale Spedali Civili 1, 25123, Brescia, Italy.  
E-mail: luca.redaellidezinis@unibs.it

*Cholesteatoma and Ear Surgery – An Update 2017, pp. 233 -236*

*Edited by Matthew Yung*

*2017 © Kugler Publications, Amsterdam, The Netherlands*

The surgical approach consisted in total mastoid cell exenteration, mastoid tip removal, lowering of the facial canal ridge, harvest of conchal cartilage by conchomeatoplasty, and lining of the cavity with a pedicled mastoid periosteum flap in both groups of patients. Mastoid cavity obliteration was performed with bone pate obtained from healthy cortical bone that was covered by pedicled mastoid periosteum flap in the group of O-CWDM patients. A postauricular approach under general anesthesia was used in all cases.

Air and bone conduction thresholds were determined before surgery and at the last control visit. Threshold frequencies of 0.5 kHz, 1 kHz, 2 kHz, and 3 kHz were used. Mean threshold differences were calculated for (1) air-bone gap (ABG) and (2) air conduction between pre- and postoperative tests. Mean threshold changes less than 10 dB were considered unvaried.

The impact of the variables was tested by the Pearson Chi-Square Test and the Fisher's Exact Test.

### 3. Results

The study group included 317 adult patients (149 males and 168 females). There were 217 primary surgeries and 100 treatments for a recurrence (33% NO-CWDM and 27% O-CWDM) ( $P = 0.3$ ). The cholesteatoma involved the middle ear in 71 patients, 246 had also a mastoid extension (76% in NO-CWDM and 81% in O-CWDM) ( $P = 0.4$ ). Mastoid obliteration was performed in 88 patients (28%). An intact ossicular chain or a previous ossiculoplasty was present in 17% (38/222 of NO-CWDM and 13/78 of O-CWDM) of both group of patients, whereas an ossiculoplasty was performed in 45% (100/222) of NO-CWDM and in 55% (43/78) of O-CWDM ( $P = 0.3$ ).

#### 3.1. Anatomical results

Dry synechiae developed in 11% (25/229) of NO-CWDM and 16% (14/88) of O-CWDM ( $P = 0.2$ ). Recurrent discharge was observed in 8% (18/229) of NO-CWDM and 3% (3/88) of O-CWDM ( $P = 0.1$ ). Dry and stable retractions developed in 14% (32/229) of NO-CWDM and 11% (10/88) of O-CWDM ( $P = 0.7$ ). Perforation of the neotympanum was observed in 3% (6/229) of NO-CWDM and 3/88 of O-CWDM) of both groups of patients ( $P = 0.7$ ). Cholesteatoma recurred in 2% (4/229) of the NO-CWDM and in none of O-CWDM ( $P = 0.6$ ).

#### 3.2. Functional results

ABG within 20 dB was observed in 29% (61/212) of NO-CWDM and in 49% (29/59) of O-CWDM ( $P = 0.003$ ) and hearing threshold improvement was observed in 28% (59/213) of NO-CWDM and in 61% (36/59) of O-CWDM ( $P = 0.001$ ), impairment was observed in 12% (26/213) of NO-CWDM vs. 14% (8/59) of O-CWDM ( $P = 0.8$ ). When an ossiculoplasty was performed, ABG within 20 dB was observed in 27% of NO-CWDM and in 55% of O-CWDM ( $P = 0.004$ ) and hearing threshold improvement was observed in 37% (34/93) of NO-CWDM and in 68% (21/31) of O-CWDM ( $P = 0.002$ ). In those cases, impairment was observed in 12% (11/93) of NO-CWDM vs. 6% (2/31) of O-CWDM ( $P = 0.5$ ).

### 4. Discussion

The principle behind the idea of mastoid obliteration is the combination the advantages of CWU and CWD techniques. A recent review on mastoid obliteration with autologous bone concluded that it is a safe low-cost technique with low recurrence rates, producing more favorable results in terms of water resistance and quality of life for patients.<sup>2</sup>

Looking for advantages and disadvantages of CWDM with autologous bone pate obliteration in our experiences, we compared anatomical and functional results between NO-CWDM and O-CWDM.

Anatomical complications of the procedures, including neotympanum retraction and perforation, recurrent

discharge and new development of a cholesteatoma were always reduced in O-CWDM. On the contrary, the development of dry synechiae was more frequent in O-CWDM probably because of occasional partial reabsorption of bone pate. Anyway, the different incidence of complication was never statistically significant.

Examining functional results, hearing improvement was significantly more frequent in O-CWDM whereas hearing deterioration was more frequent in NO-CWDM without a statistical significance. Improved hearing advantages in O-CWDM could be due to different distribution of air volumes: middle ear cleft is larger than in NO-CWDM, external ear canal is shorter and narrower than in NO-CWDM. The observation is consistent with the results of a previous report that shows higher hearing improvement after ear surgery when air volumes distribution is closer to that of normal anatomy.<sup>3</sup>

## 5. Conclusions

Our experience on mastoid obliteration is comparable to previous literature resulting in reduced postoperative complication and improved functional results.

## References

1. Redaelli de Zinis LO, Tonni D, Barezzani MG. Single-stage canal wall-down tympanoplasty: long-term results and prognostic factors. *Ann Otol Rhinol Laryngol* 2010;119(5):304-312.
2. Alves RD, Cabral Junior F, Fonseca AC, Bento RF. Mastoid obliteration with autologous bone in mastoidectomy canal wall down surgery: a literature overview. *Int Arch Otorhinolaryngol* 2016;20(1):76-83.
3. Zanetti D, Redaelli de Zinis LO, Campovecchi C, et al. The influence of ear cavities resonances on hearing results of tympanoplasty. *Otorinolaringologia* 2006;56(2):87-92.





# FIRST EXPERIENCE WITH THE CHOLE CLASSIFICATION IN COMBINATION WITH A QOL QUESTIONNAIRE

Christof Rösli, David Bächinger<sup>1,2</sup>, Thomas E Linder<sup>2,3</sup>, Alex M Huber<sup>1,2</sup>

<sup>1</sup>*Department of Otolaryngology, Head and Neck Surgery, University Hospital Zürich, Zürich, Switzerland*

<sup>2</sup>*University of Zürich, Zürich, Switzerland;* <sup>3</sup>*Department of Otolaryngology, Head and Neck Surgery, Luzerner Kantonsspital (LUKS), Luzern, Switzerland*

## 1. Introduction

In otology, surgical outcome is most often assessed by reporting postoperative hearing thresholds. This includes pure tone audiometry and speech audiometry. Subjective complaints are not always and systematically reported although the importance of patient-reported outcomes is increasing in up-to-date clinical outcome research. One possible tool to assess health-related quality of life (HRQoL) is the use of questionnaires. However, generic questionnaires are often not sensitive enough to detect all aspects of HRQoL reliably. Therefore, a specific instrument for chronic otitis media (COM) is required. Few specific paper-based questionnaires exist for adult patients, including the chronic ear survey (CES, English), the Chronic Otitis Media Outcome Test (COMOT-15, German) and the Chronic Otitis Media Questionnaire (COMOQ-12, English).<sup>1-4</sup> The CES covers only disease specific health focusing on restrictions due to hearing impairment. The influence of other ear related symptoms such as discharge, pain, vertigo or tinnitus on quality of life is not individually considered. The COMOT-15 emphasizes HRQoL. It includes only one general question on symptoms besides hearing loss. The COMOQ-12 covers a broad spectrum of signs and symptoms. It is heavily oriented towards the physical dimension. Out of 12 questions, seven of them address signs and symptoms. However, essential general components of HRQoL that may be of importance in COM are not specifically covered. To overcome these issues, we aimed to develop and validate a new German electronic questionnaire for comprehensively measuring HRQoL in adult patients with COM.

Another issue in reporting outcome of ear surgery is the lack of a comparable description of cholesteatoma preoperatively and intraoperatively. Hearing outcome may depend on the state of the ossicles, while risk for persistent or recurrent disease may depend on the extension of the cholesteatoma. The surgical approach may depend on the presence of complications such as abscess, labyrinthitis, facial palsy, or on the pneumatisation and ventilation of the mastoid itself. A classification system, called ChOLE classification,<sup>5</sup> was recently developed by one of the authors (TE. L) taking these four aspects into consideration.

The aim of this study was to correlate the score achieved in the questionnaire to the ChOLE classification system for patients with chronic otitis media cholesteatomatosa.

## 2. Methods

A new questionnaire for comprehensively measuring HRQoL was developed based on existing questionnaires (CES, COMOT-15) and clinical experience with a total of 33 questions. Answers were presented using a 5-point Likert scale (0 corresponding to no emotional or physical impact) to 4 (corresponding to severe emotional or physical impact). An electronic application was chosen to facilitate and accelerate data analysis. In a first step,

Correspondence: Christof Rösli, Frauenklinikstrasse 24, 8091 Zürich, Switzerland.  
E-mail: christof.roesli@usz.ch

*Cholesteatoma and Ear Surgery – An Update 2017, pp. 237 -240*

*Edited by Matthew Yung*

*2017 © Kugler Publications, Amsterdam, The Netherlands*

the questionnaire was tested in a cohort ( $n = 85$ ) with COM. The number of questions was reduced from 33 to 21 using sequential statistical analysis. Then the adjusted questionnaire, called Zurich chronic middle ear inventory (ZCMEI-21) was validated in a second cohort of patients with COM ( $n = 76$ ) and healthy subjects ( $n = 31$ ) as described previously.<sup>6</sup>

Finally, the validated questionnaire was tested in a cohort of patients with chronic otitis media cholesteatomatosa preoperatively to compare HRQoL to the characteristics of the cholesteatoma defined by a newly developed classification of cholesteatoma (ChOLE). The ChOLE classification rates four characteristics of a cholesteatoma.<sup>4</sup> First, the extension of the cholesteatoma is rated from Ch1 to 4. Second, the state of the ossicles is assessed as O0 to O4. Third, life-threatening complications are rated between L0 and L3, and finally, the Eustachian tube ventilation and mastoid pneumatization is assessed as E0 to E3. Due to the low number of subjects included in this preliminary analysis, statistical analysis is not meaningful.

### 3. Results

For the development of the ZCMEI-21, sequential statistical analysis was performed to reduce the number of questions, resulting in 21 questions in the final version. Validation in the second cohort revealed a Cronbach's  $\alpha$  of 0.91, indicating excellent internal consistency. Moreover, the questionnaire was able to discriminate between patients with chronic otitis media and healthy participants ( $p < 0.0001$ ), thus possessing good discrimination validity.

A total of ten patients were included for the comparison of the results of the questionnaire and the ChOLE classification (Table 1). Their age ranges from 20 to 80 years (mean 44 years). Five patients are male, five female.

The stage of the cholesteatoma according to the ChOLE classification correlated well to the total score of the ZCMEI-21. The cholesteatoma was staged as 3c in three, 2a in one, 2c in one, 1c in three, and 1a in two patients. Generally, cholesteatoma with a large extension (rated by Ch1 to 4) tended to impair HRQoL to a larger extent than cholesteatoma confined to the middle ear. The state of the ossicles varied from O0 to O4. However, an intact ossicular chain tended to result in higher HRQoL. No life threatening events (L0 to L3) were present. The pneumatization and ventilation of the mastoid (E0 to E3) varied considerably and did not correlate to the extension of the cholesteatoma or the HRQoL. There was correlation for staging and HRQoL. Patients with a stage 3c had a score in the questionnaire between 36 and 44 (maximum ZCMEI-21 total score: 84). It was staged 1a in two and

Table 1. Total score and subscore of the questionnaire compared to the ChOLE classification.

Questionnaire Total score	Questionnaire subscores				ChOLE				
	symptoms (5 questions)	hearing (5 questions)	psychosocial (8 questions)	medical ressources (3 questions)	Ch	O	L	E	Stage
36	5	12	19	0	3	2	0	3	3c
40	6	14	20	0	3	2	0	2	3c
3	0	0	2	1	1	0	0	0	1a
6	1	1	4	0	1	1	0	0	1a
30	5	9	11	5	2	1	0	0	2a
49	4	15	20	10	2	1	0	3	2c
8	2	2	4	0	1	2	0	3	1c
44	11	3	22	8	3	1	0	3	3c
25	6	5	9	5	1	2	0	2	1c
6	1	3	0	2	1	1	0	2	1c

1c in three patients. These patients had a score in the questionnaire between 3 and 25, however only one patient had a score above.<sup>8</sup> The two remaining patients had a stage 2a (a score of 30), and 2c (score of 49). The number of patients included in this preliminary evaluation is too small for reliable statistical analysis.

#### 4. Discussion

The ZCMEI-21 is a valid instrument to assess HRQoL in patients with COM. It covers several ear symptoms such as pain, discharge, vertigo and balance problems, hearing impairment and tinnitus. Social and psychological aspects are comprehensively assessed. The use of an electronic application has the advantage of better data quality, easy distribution, and facilitated data analysis. A possible disadvantage is the fact that the ZCMEI-21 is only validated for German language. Therefore, validation for other languages is in progress.

The ChOLE classification proved to be a useful tool that is easy to integrate in clinical daily routine for patients with cholesteatoma. Generally, cholesteatoma with a large extension tended to impair HRQoL to a larger extent than cholesteatoma confined to the middle ear. Therefore it seems to be important to include the extension of the cholesteatoma in the rating system. One possible advantage of the ChOLE classification is the integration of the state of the ossicles, because hearing outcome may depend on the presence of an intact ossicular chain, or the presence of the stapes suprastructure. The state the ossicular chain is usually not considered in other suggested classification systems.<sup>7-9</sup> There appeared to be a trend of HRQoL and the state of the ossicles with an intact ossicular chain being in favor for good quality of life. Although we did not have a patient with a complication caused by the cholesteatoma, we feel that it is important to integrate the presence of labyrinthitis, facial palsy or abscess formation in a classification system. The extent of cholesteatoma may be different in different countries and outcome of surgery may depend on the presence of complication. Finally, the pneumatization and ventilation of the mastoid cells did not show a correlation to HRQoL. Analysis on a larger cohort is required to address this issue, as well as to be able to compare the ChOLE classification compared to other classification systems such as the suggested EAONO/JOS classification system.<sup>6</sup>

#### 5. Conclusions

Sufficient information on reliability and validity of the ZCMEI-21 was obtained. It can be applied to quantify HRQoL in patients with cholesteatoma and shows good correlations to the ChOLE classification. Both instruments may improve comparability of surgical outcome of patients with cholesteatoma by (a) describing and staging the cholesteatoma preoperatively; and (b) having the possibility to assess HRQoL additionally to hearing outcome. However, more patients need to be analyzed to be able to do statistical analysis and draw proper conclusions.

#### References

1. Nadol JB Jr, Staeker H, Gliklich RE. Outcomes assessment for chronic otitis media: the chronic ear survey. *Laryngoscope* 2000;110:32-35.
2. Baumann I, Kurpiers B, Plinkert PK, Praetorius M. Development and validation of the Chronic Otitis Media Outcome Test 15 (COMOT-15). Measurement of health-related quality of life in patients with chronic otitis media. *HNO* 2009;57:889-895.
3. Phillips JS, Haggard M, Yung M. A new health-related quality of life measure for active chronic otitis media (COMQ-12): development and initial validation. *Otol Neurotol* 2014;35:454-458.
4. Dubach P, Mantokoudis G, Caversaccio M. Ear canal cholesteatoma: meta-analysis of clinical characteristics with update on classification, staging and treatment. *Curr Opin Otolaryngol Head Neck Surg* 2010;18(5):369-376.

5. Linder TE, Milici N, Shankar S. The ChOLE-Classificaton: A pilot approach to classify tympanomastoid cholesteatome. Chole 2016, Edinburgh 2016.
6. Bächinger D, Rösli C, Ditzen B, Huber AM. Development and validation of the Zurich chronic middle ear inventory (ZCMEI-21): an electronic questionnaire for assessing quality of life in patients with chronic otitis media. Eur Arch Otorhinolaryngol 2016; Feb. 11. [Epub ahead of print]
7. Yung M, Incesulu A, Sudhoff H, et al. EAOMO/JOS joint consensus statements of the Definition, Classification and Staging of Cholesteatoma. Chole 2016, Edinburgh. 2016.
8. Black B, Gutteridge I. Aquired cholesteatoma: classification and outcomes. Otol Neurotol 2011;32(6):992-995.
9. Kitahara T, Mishihiro Y, Sakagami M, et al. Staging-based surgical results in chronic otitis media with cholesteatoma. Nihon Jibiinkoka Gakkai Kaiho 2012;115(2):91-100.

# PATHOGENESIS OF CHOLESTEATOMA: CHANGING CONCEPTS

Letícia P.S. Rosito<sup>1</sup>, M.N.L. Silva<sup>1</sup>, I. Canali<sup>2</sup>, F.A. Selaimen<sup>2</sup>, S.S. Costa<sup>2</sup>

<sup>1</sup>Otology staff, Clinicas Hospital of Porto Alegre, Brazil; <sup>2</sup>Department of Otolaryngology, Federal University of Rio Grande do Sul, Brazil

## 1. Introduction

Since cholesteatoma was first described, many classifications have been proposed based on otomicroscopic appearance,<sup>1</sup> typical growth patterns,<sup>2</sup> disease extension,<sup>3</sup> surgical findings,<sup>4</sup> and otoscopic drum status.<sup>5</sup> However, there are still controversies about the clinical application of each of those classifications. Moreover, the real prevalence of each form of cholesteatoma is still unknown.

In our previous study,<sup>6</sup> we classified the cholesteatomas based on their growth pattern by analyses of the oto-endoscopies and then we described the subtype's prevalence. Posterior epitympanic (34.3%) and posterior mesotympanic (33.8%) were the most frequent types of cholesteatoma observed. Anterior epitympanic type was the least frequent (2%). However, 30% of the cholesteatomas could not be classified as posterior epitympanic, posterior mesotympanic or anterior epitympanic. We observed that in 13.8% both the pars flaccida and the pars tensa are involved, so we called them two routes cholesteatomas. Finally, in 16.2% no precise growth pattern could be identified by video otoscopy. We classified them as undetermined cholesteatomas. Posterior epitympanic cholesteatoma was more prevalent in adults whereas posterior mesotympanic cholesteatoma was more frequent in children. Anterior epitympanic cholesteatoma was only observed in children.

The pathogenesis of acquired middle ear cholesteatoma is still controversial. At present, the four main theories are as follows: metaplasia; migration; invagination; and papillary proliferation.<sup>1</sup> These theories mainly originated from clinical observations and experimental studies<sup>7,8</sup> since well-designed cohorts are difficult to perform because cholesteatoma is an infrequent disease and needs several years to develop.

Since 2008, we have been indirectly studying the pathogenesis of chronic otitis media by examining the contralateral ear (CLE).<sup>9</sup> Our observations have systematically showed a high prevalence of alterations in the CLE in clinical,<sup>9</sup> histopathological,<sup>10</sup> radiological<sup>11</sup> and functional<sup>12</sup> studies. Moreover, our results demonstrated that the frequency of alterations in the CLE was even higher in patients with COM with cholesteatoma.<sup>9</sup> Tympanic membrane retraction and cholesteatoma in the CLE tended to be common in patients with cholesteatoma in the main ear regardless of the growth pattern. So, we also believe that nowadays the analysis of the CLE is the best way to study cholesteatoma pathogenesis in humans.

In our previous study,<sup>13</sup> only about one-third of the CLEs in patients with cholesteatoma in the main ear were considered normal. Moderate-to-severe tympanic membrane retraction and cholesteatoma were undoubtedly the most prevalent pathological changes. Analyzing only those with alterations in CLE we observed that 95.8% of the patients presented retraction or signs of previous retraction (outside-in perforations) or progression of these retractions (cholesteatoma) in the CLE. Interestingly, our results show that there is a strong correlation between growth patterns of cholesteatomas in the main ear and location of TM retractions in the CLE. Therefore it seems plausible to infer that these retractions represent the earlier phases of cholesteatoma formation in the main ear. We still don't know if the tympanic membrane retraction per se is enough to cholesteatoma formation. We believe that other factors that can disrupt the stability of the retraction are essential. Sudhoff and Tos,<sup>1</sup> after observing

Correspondence: Letícia Petersen Schmidt Rosito, Ramiro Barcelos st 2350, Porto Alegre, Rio Grande do Sul, Brazil.  
E-mail: leticiariosito@gmail.com

*Cholesteatoma and Ear Surgery – An Update 2017, pp. 241 -244*

*Edited by Matthew Yung*

*2017 © Kugler Publications, Amsterdam, The Netherlands*



the retraction of both the PT and the PF in some children, proposed a four-step concept for the pathogenesis of cholesteatoma that combines the retraction and proliferation theories: (i) the retraction pocket stage; (ii) proliferation of the retraction pocket, subdivided into cone formation and cone fusion; (iii) expansion of cholesteatoma; and (iv) bone resorption. Although bone erosion can occur earlier in the development of tympanic membrane retraction without cholesteatoma formation, the inflammatory process may be involved in both sustenance of negative pressure in the middle ear and progression of tympanic membrane retraction to cholesteatoma. Jackler *et al.*<sup>15</sup> on the other hand proposed the theory of mucosal traction which is based upon the premise that the squamous pouch is drawn inward by the interaction of opposing motile surfaces of middle ear mucosa.<sup>12</sup> The only point of convergence of these theories is that tympanic membrane retractions were almost universally implied in the first stages of cholesteatoma formation.

## 2. Conclusion

The classification of cholesteatomas according to growth patterns is the most embracing one since is based on pathogenesis and can explain the different aspects in progression and hearing impairment. The contralateral ear is the best method to study the pathogenesis of cholesteatoma in humans. Our studies have shown that the tympanic membrane retractions could be implied in the first stages of cholesteatoma formation in most of our cases.

## References

1. Sudhoff H, Tos M. Pathogenesis of sinus cholesteatoma. *Eur Arch Otorhinolaryngol* 2007;264:1137-1143.
2. Jackler RK. The surgical anatomy of cholesteatoma. *Otolaryngol Clin North Am* 1989;22:883-896.
3. Saleh HA, Mills RP. Classification and staging of cholesteatoma. *Clin Otolaryngol* 1999;24:355-359.
4. Yanagihara N. Surgical treatment of cholesteatoma using intact canal wall tympanoplasty. *Acta AWHO* 1996;15:62-74.
5. Black B, Gutteridge I. Acquired cholesteatoma: classification and outcomes. *Otol Neurotol* 2011;32:992-995.
6. Rosito LS, Netto LF, Teixeira AR, da Costa SS. Classification of Cholesteatoma According to Growth Patterns. *JAMA Otolaryngol Head Neck Surg* 2016;142(2):168-172.
7. Bujia J, Holly A, Antoli-Candela F, Tapia MG, Kastenbauer E. Immunobiological peculiarities of cholesteatoma in children: quantification of epithelial proliferation by MIB1. *Laryngoscope* 1996;106:865-868.
8. Yoon TH, Schachern PA, Paparella MM, Aeppli DM. Pathology and pathogenesis of tympanic membrane retraction. *Am J Otolaryngol* 1990;11:10-17.
9. Da Costa SS, Rosito LP, Dornelles C, Sperling N. The contralateral ear in chronic otitis media: a series of 500 patients. *Arch Otolaryngol Head Neck Surg* 2008;134:290-293.
10. Rosito LP, da Costa SS, Schachern PA, Dornelles C, Cureoglu S, Paparella MM. Contralateral ear in chronic otitis media: a histologic study. *Laryngoscope* 2007;117:1809-1814.
11. Silva MN, Muller Jdos S, Selaimen FA, et al. Tomographic evaluation of the contralateral ear in patients with severe chronic otitis media. *Braz J Otorhinolaryngol*. 2013;79:475-479.
12. Netto LFS, Costa SS, Sleifer P, Braga MEL. The impact of chronic suppurative otitis media on children's and teenagers' hearing. *Int J Pediatr Otorhinolaryngol* 2009;73:1751-1756.
13. Rosito LP, da Silva MN, Selaimen FA, et al. Characteristics of 419 patients with acquired middle ear cholesteatoma. *Braz J Otorhinolaryngol*. 2016 [Epub ahead of print].
14. Sudhoff H, Tos M. Pathogenesis of sinus cholesteatoma. *Eur Arch Otorhinolaryngol*. 2007 Oct;264(10):1137-43.
15. Jackler RK, Santa Maria PL, Varsak YK, Nguyen A, Blevins NH. A new theory on the pathogenesis of acquired cholesteatoma: Mucosal traction. *Laryngoscope* 2015;125 Suppl 4:S1-S14.

16. Rosito LP, Teixeira AR, Netto LS, Selaimen FA, da Costa SS. Cholesteatoma growth patterns: are there audiometric differences between posterior epitympanic and posterior mesotympanic cholesteatoma? *Eur Arch Otorhinolaryngol* 2016, Feb 13. [Epub ahead of print].
17. Rosito LP, Netto LS, Teixeira AR, da Costa SS. Hearing Impairment in Children and Adults With Acquired Middle Ear Cholesteatoma: Audiometric Comparison of 385 Ears. *Otol Neurotol* 2015;36(8):1297-1300.



# CHOLESTEATOMA IN CHILDREN – THE PROFILE OF PAEDIATRIC AND ADULT CHOLESTEATOMA PRESENTING IN A SECONDARY AND TERTIARY CARE SETTING

Robert Nash, Shakeel R. Saeed

*The Royal National Throat, Nose and Ear Hospital, Gray's Inn Road, London, UK*

## Abstract

It is recognized that acquired cholesteatoma has a more aggressive clinical course in children than in adults. Management of cholesteatoma in children may also be complicated by anatomical factors, patient concordance, and poor Eustachian tube function. Elimination of disease, maintenance or reconstruction of hearing, and effective waterproofing of the ear is important.

Patients referred as tertiary referrals had more advanced disease at the time of presentation to our center. They were more likely to have normal hearing, be the only hearing ear, or have better hearing than the contralateral side.

Tertiary referrals arise for many reasons, which include patient convenience, issues with communication between patients and clinicians, and cases with particularly advanced disease. Tertiary referral of challenging cases allows experience of these uncommon cases to be centralized within a region.

## 1. Introduction

Whilst there is debate on the issue,<sup>1</sup> it is generally recognized that acquired cholesteatoma has a more aggressive clinical course,<sup>2-4</sup> and greater tendency for recurrence,<sup>5</sup> in children than in adults. Histopathological studies have demonstrated a greater number of mononuclear inflammatory cells<sup>6</sup> in a thicker perimatrix,<sup>7</sup> with greater angiogenesis and matrix metalloproteinase expression<sup>8</sup> in paediatric disease.

It has therefore been suggested that acquired paediatric cholesteatoma represents a qualitatively different disease not only to congenital cholesteatoma (which is not considered in this article),<sup>9</sup> but also to acquired adult cholesteatoma.<sup>10,11</sup>

Management of paediatric cholesteatoma may also be complicated by poor Eustachian tube function, and a relatively smaller operative field in the mastoid and ear canal. Management aims include the clearance of disease, maintenance of hearing, and 'waterproofing' of the ear.<sup>12</sup> Outcomes are particularly important in the context of a patient still receiving education, who may be impaired by hearing loss or a requirement for regular debridement of a cavity for many years.

It is also thought likely that, in comparison to referrals from general or family practitioners, tertiary referral cases represent a severe end of a spectrum of disease. Patients may be referred to another center for a number of reasons. These include patient related factors, such as convenience, or issues with communication with between the patient and treating clinicians. Disease factors may also be important, and these include failure to clear disease despite a number of interventions, involvement of the petrous apex or dura, or erosion of the facial nerve canal or otic capsule. Management of such cases may be highly challenging, and referral of such uncommon cases allows experience to be centralized within a region.

Correspondence: Robert Nash  
E-mail: mr.robert.nash@gmail.com

*Cholesteatoma and Ear Surgery – An Update 2017, pp. 245 -250*  
*Edited by Matthew Yung*  
2017 © Kugler Publications, Amsterdam, The Netherlands

## 2. Aims

The aim of this study was to determine differences in the presentation of children and adults presenting as secondary and tertiary referrals at a single center.

## 3. Materials and Methods

### 3.1. Study design and setting

Our center is a single specialty ENT hospital. Paediatric and adult cases are managed. We retrospectively searched clinical coding data to identify all patients undergoing tympanomastoid surgery February 1, 2012 onwards. Electronic clinical records were searched, and the patients were divided into secondary and tertiary referrals, where a tertiary referral was defined as a patient referred from another center practicing otologic surgery, or referred by the general practitioner at the specific recommendation of another center practicing otologic surgery. Date of birth and operation dates were used to classify patients as adult or paediatric. Paediatric patients were defined as those below the age of 18 on the date of initial surgery.

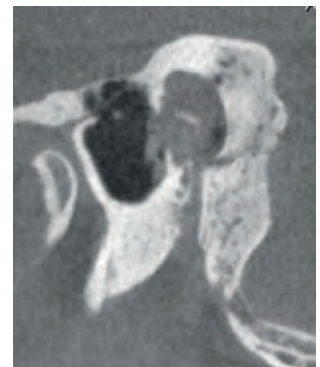
### 3.2. Subjects

Twenty consecutive patients in each of these four groups (secondary adult, secondary paediatric, tertiary adult, tertiary paediatric) were identified. The mean age of paediatric patients at the time of first operation was 11.2 years. The mean age of adult patients was 48.5 years.

### 3.3. Clinical information

The patient records, imaging and operation notes were searched to yield the following information:

- Number of prior tympanomastoid operations on the affected ear.
- Only hearing (if mean recordable thresholds in the contralateral ear were > 100 dB).
- Better hearing (if the contralateral ear did not provide benefit).
- Normal hearing (if the mean recordable thresholds in the affected ear were < 5 dB).
- Presence of inner ear fistula(e) (Fig. 1).
- Petrous apex extension (small / large volume).
- Involvement of dura / history of intracranial complication.
- Involvement or significant dehiscence of the facial nerve.
- Number of prior operations.



*Fig. 1.* Fistula into the vestibule is seen in sagittal section of cone beam CT in a patient with normal hearing.

### 3.4. Statistical analysis

The four groups (paediatric/adult and secondary/tertiary referrals) were compared using Fisher's exact test for categorical data, student's t-test for continuous parametric data (age). The analysis was conducted to see if there was a statistically significant difference between these groups.

Table 1. Factors present in paediatric/adult secondary/tertiary cases on presentation.

	Age	Hearing			Surgery	Markers of Severity			
	Mean Age (years)	Normal	Better	Only	Number of Ops prior to referral	Inner ear fistula	Medial to labyrinth	Facial involvement	Dural involvement
Paediatric Secondary	9.7	2	1	0	3	0	0	4	1
Paediatric Tertiary	12.8	4	5	2	22	5	5	7	3
Adult Secondary	49.6	1	0	0	11	2	1	4	1
Adult Tertiary	47.3	1	4	1	23	3	1	2	5

## 4. Results

### 4.1. Hearing at presentation

Tertiary cases were significantly more likely to have pre-operative hearing thresholds that might make surgery more challenging. Three out of forty procedures were in only hearing ears (there were none in the secondary referral group), and 9/40 were in the better hearing ear (there was one in the secondary referral group) ( $p < 0.05$ ) (Table 1).

### 4.2. Prior surgical intervention

Tertiary referral cases had a non-significantly higher number of prior surgical interventions (Table 1).

### 4.3. Markers of disease severity

There was a statistically significant ( $< 0.01$ ) greater number of disease severity in the tertiary referral group. Greater numbers were seen in all areas, most notably in disease medial to the labyrinth (6/40 in the tertiary referral group and 1/40 in the secondary referral group) (Table 1).

### 4.4. Children and adults

Despite the reported differences between adult and paediatric cholesteatoma, there were no significant differences between the paediatric and adult groups (other than age).

## 5. Discussion

### 5.1. Children and adults

It is interesting that our series did not demonstrate significant differences between paediatric and adult cases. It may be that these differences are not present, although it is perhaps more likely that our sample size was too small to detect such differences. It is also possible that the more aggressive course of paediatric cholesteatoma does not manifest in erosion of the otic capsule, or extension into the petrous apex, but rather in microscopic effects at the margin of cholesteatoma that may lead to greater incidence of residual / recurrent disease.

### 5.2. Secondary and tertiary referrals

As expected, tertiary referrals had a much higher prevalence of markers of severe disease. These cases were more



likely to be referred to allow a concentration of expertise to develop in a region. Furthermore, some aspects of cholesteatoma management – such as the need for neurosurgical intervention in temporal lobe abscess, or cochlear implantation in bilateral profound hearing loss – may necessitate referral. Equally, some patients were referred on for their convenience when they moved, or because of issues with communication with the referring team.

### 5.3. Challenging cases

There were some notably challenging cases, with large volume petrous apex extension of a recurrent/residual cholesteatoma after canal wall down surgery seen in the only hearing ear of a teenage patient (Fig. 2), and one adult seen with recurrent disease eroding into the intracranial space in the internal auditory meatus.

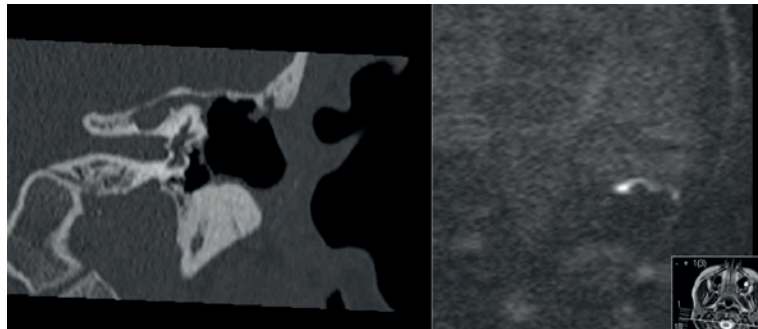


Fig. 2. Petrous apex cholesteatoma seen on CT and diffusion weighted MRI in an only hearing ear.

### 5.4. Surgical approach

There is some debate about the indications for ‘canal-wall-preserving’ and ‘canal-wall-down’ techniques in a paediatric population. For example, Osborn *et al.*<sup>13</sup> have suggested that pervasive Eustachian tube dysfunction, as seen in cases such as cleft palate, are an indication for canal wall removal. Although other studies have demonstrated that the canal wall can be preserved in a majority of patients with cleft palate,<sup>14</sup> and Down’s syndrome.<sup>15</sup> The preference in this series was almost invariably either canal wall preservation, reconstruction, or mastoid obliteration.

## 6. Conclusions

Tertiary referrals for cholesteatoma management have more advanced disease, and more challenging hearing thresholds at the time of presentation. In this series, paediatric and adult cholesteatoma presented similarly.

## References

1. Tos M. Treatment of cholesteatoma in children: a long-term study of results. *J Otol* 1983;4:189-197.
2. Glasscock ME, Dickins JFE, Wiet R. Cholesteatoma in children. *Laryngoscope* 1981;91:1743-1753.
3. Palva A, Karma P, Kärjä J. Cholesteatoma in children. *Arch Otolaryngol* 1997;103(2):74-77.
4. Bujia J, Holly A, Antoli-Candela F, Tapia MG. Immunobiological peculiarities of cholesteatoma in children: quantification of epithelial proliferation by MIB1. *Laryngoscope* 1996;106(7):865-868.
5. Morita Y, Yamamoto Y, Oshima S et al. Acquired cholesteatoma in children: clinical features and surgical outcome. *Auris Nasus Larynx* 2014;41(5):417-421.
6. Quaranta A, Resta L, Santangelo A. Otomastoid cholesteatoma in children: histopathological findings. *Int J Pediatric Otorhinolaryngol* 1986;12(2):121-126.

7. Dornelles CD, Costa SS, Meurer L, Schweiger C. Descrição histológica de colesteatomas adquiridos: comparação entre amostras de crianças e de adultos. *Rev Bras ORL* 2006;72(5):641-648. [in Portuguese]
8. Dornelles C, da Costa S, Meurer L, et al. Comparison of acquired cholesteatoma between pediatric and adult patients. *Eur Arch Otorhinolaryngol* 2009;266:1553-1561.
9. Morita Y, Yamamoto Y, Oshima S, Takahashi K, Takahashi S. Pediatric middle ear cholesteatoma: the comparative study of congenital cholesteatoma and acquired cholesteatoma. *Eur Arch Otorhinolaryngol* 2016;273(5):1155-1160.
10. Dornhoffer J, Friedmana A, Glutha M. Management of acquired cholesteatoma in the pediatric population. *Curr Opin Otolaryngol Head Neck Surg* 2013;21(5):440-445.
11. Smythe JL, Brachman D, Grahm M. Complications of cholesteatoma: a report on 1024 cases. In: *Cholesteatomas of the middle ear. Diagnosis, etiology and complications. Radiol Clin North Am* 1984;22:15-34.
12. Vercruysse J, De Foer B, Somers T, Casselman J, Offeciers E. Mastoid and Epitympanic Bony Obliteration in Pediatric Cholesteatoma. *Otol Neurotol* 2008;29:953-960.
13. Osborn A, Papsin B, A James. Clinical Indications for Canal Wall down Mastoidectomy in a Pediatric Population. *Otolaryngol Head Neck Surg* 2012;147(2) 316-322.
14. Kopcsányi G, Vincze O, Bagdán V, Pytel J. Retrospective analysis of tympanoplasty in children with cleft palate: A 24-year experience. II. Cholesteatomatous cases. *Int J Pediatr Otorhinolaryngol* 2015;79(5):698-706.
15. Nash R, Possamai V, Maskell S, Bailey CM, Albert D. Canal wall reconstruction and preservation in the surgical management of cholesteatoma in children with Down's syndrome. *Int J Pediatr Otorhinolaryngol* 2014;78(10):1747-51.



# ASSESSMENT OF VESTIBULAR FUNCTION IN PATIENTS WITH CHRONIC MIDDLE EAR DYSFUNCTION USING VHIT AND VEMP TESTING

J.S. Sandhu<sup>1,2</sup>, M. Yung<sup>3</sup>, J. Parker-George<sup>4</sup>, B. Kearney<sup>4</sup>, J. Ray<sup>1</sup>

<sup>1</sup>Ear Nose and Throat Department, Royal Hallamshire Hospital, Glossop Road, Sheffield, UK; <sup>2</sup>Sheffield Institute for Translational Neuroscience, University of Sheffield, Sheffield UK; <sup>3</sup>Ear Nose and Throat Department, Ipswich Hospital, Ipswich UK; <sup>4</sup>Department of Audiology, Ipswich Hospital, Ipswich UK

## 1. Introduction

The anatomical proximity between the middle and inner ear structures can allow diseases affecting the middle-ear cavity to cause symptoms of dizziness and vertigo. Although there is a paucity in the published data, incidence rates of dizziness are high ranging from 9-20% in patients with otosclerosis,<sup>1,2</sup> 40% in patients with cholesteatoma<sup>3</sup> and 54% in cases of chronic suppurative otitis media.<sup>4</sup> A major reason for the lack of studies in this area is the ineffectiveness of standard vestibular tools in the presence of middle ear dysfunction. The traditional bi-thermal caloric test has been used to glean some information,<sup>5</sup> however, interpretation is difficult as the thermal transfer function of the middle ear is unknown. Recently, novel vestibular tests have been developed that bypass the middle ear and allow objective evaluation of the entire vestibular end organ. The first of these is the bone-conduction vestibular evoked myogenic potential (VEMP).<sup>6,7</sup> The VEMP relies on bone-conduction mediated delivery of energy into the otoliths and records synchronised myogenic potentials to quantify the response. The VEMP can be recorded using two test paradigms; the cervical VEMP (cVEMP) which reflects saccular function and the ocular VEMP (oVEMP) which is generated by the utricle. The second technique is the video head impulse test (vHIT).<sup>8</sup> During the vHIT, abrupt accelerations are manually made in the plane of the semicircular canal being tested and high speed video goggles are used to monitor the corrective eye movements generated. In the presence of canal dysfunction these eye movements are aberrant as the vestibular ocular response (VOR) gain is inadequate and this information can be objectively recorded. Using these new tests all five subcomponents of the vestibular systems can be assessed in the pre-operative clinical setting.

## 2. Materials and methods

Twenty patients (11 female and nine male) with chronic middle-ear disease were prospectively recruited into the study. The aetiological breakdown for the 20 ipsilateral ears were; cholesteatoma (11), otosclerosis (two), chronic discharging ear (two), perforation (two) and meatal stenosis (one). All patients underwent vHIT assessment of the six semi-circular canals using the GN Otometrics ICS impulse system. The VOR gain was calculated using a minimum of ten head thrusts for each canal concerned. Using age matched normative data,<sup>9</sup> a gain cut off of 0.8 was used for the lateral canal and 0.60 were used for the anterior and posterior canals. Bone-conduction VEMPs were carried out using the GN Otometrics (Taastrup, Denmark) ICS CHARTR EP system coupled to a Bruel and Kjaer Mini-Shaker 4810 driven by a 500 Hz short tone burst with a five-ms rise and fall time at a rate of 5.1 Hz.

Correspondence: Dr. J.S. Sandhu, MPhys MBChB MSc PhD, Ear Nose and Throat Department, Royal Hallamshire Hospital, Glossop Road, Sheffield, UK, S10 2JF, UK.  
E-mail: jassandhu@nhs.net

*Cholesteatoma and Ear Surgery – An Update 2017, pp. 251 -254*  
*Edited by Matthew Yung*  
2017 © Kugler Publications, Amsterdam, The Netherlands

A total of 128 repetitions were collected and averaged to produce the VEMP traces from which amplitude were taken.

### 3. Results

Of the twenty patients enrolled in the study, 12 were on the waiting list for surgery to their left ears and eight for the right. These ears were labelled as the ipsilateral ears (I). In 11 of these patients, middle ear disease had previously been diagnosed in the contralateral ear (C) and nine of these were normal (CN). VEMP and vHIT data were collected from all 40 ears.

The average ocular VEMP amplitudes for I, C and CN groups were  $8.5 \pm 6.9$ ,  $6.6 \pm 6.4$  and  $6.1 \pm 6.4$ . The Wilcoxon Signed-Rank test showed there to be no significant difference between the ipsilateral (I) and contralateral (C) data ( $p = 0.52$ ) or between the ipsilateral (I) and non-diseased contralateral (CN) data ( $p = 0.22$ ). However, in two cases there was a significant paresis ( $> 40\%$ ) present. The average cervical VEMP amplitudes for I, C and CN groups were  $151.7 \pm 32.7$ ,  $173.2 \pm 80$  and  $227.2 \pm 71.0$ . The Student T-Test showed there to be no significant difference between the ipsilateral (I) and contralateral (C) data,  $p = 0.31$ . However, there was a significant difference between the ipsilateral (I) and non-diseased contralateral (CN) data ( $p < 0.05$ ). Examination of the ipsilateral versus contralateral paresis of the cVEMP showed that there was a significant paresis ( $> 40\%$ ) present in three cases. The correlation between the ipsilateral and contralateral ocular and cervical VEMP magnitudes is depicted in Figure 1.

The average VOR gains for the lateral, anterior and posterior canals for the ipsilateral (I), contralateral (C) and contralateral non-disease ears (CN) were compared using the Student T-Test. This showed there to be no statistically significant difference between the gains of the groups of data. Using a gain cut-off of 0.8 for the lateral canals and 0.65 for the vertical canals, seven of the ipsilateral ears were abnormal and six of the contralateral ears were abnormal.

### 4. Discussion

Although it is widely accepted that middle ear pathologies can cause dizziness and imbalance, to date this has remained an area that has largely remained under-investigated. However pre-operative assessment of the vestibular system remains

Important as it may affect surgical planning and certainly has an impact on preoperative counselling. In this study, the combination of vHIT and VEMP uncovered abnormal vestibular function in 16 of the 40 ears tested (40%). This is in close agreement with the 40-56% values derived from published studies that have attempted to use combinations of bi-thermal caloric and rotating chair methodologies.<sup>3,4</sup>

### 5. Conclusion

In summary, this study has confirmed that a combination of vHIT and VEMP testing can provide a practical method of assessing the vestibular apparatus of patients with chronic middle ear pathology. The non-invasive nature of these tests means that patients can have testing done on more than one occasion allowing for serial monitoring to be done if needed. The combination of these new assessment tools heralds a new era in vestibular management for this patient group.

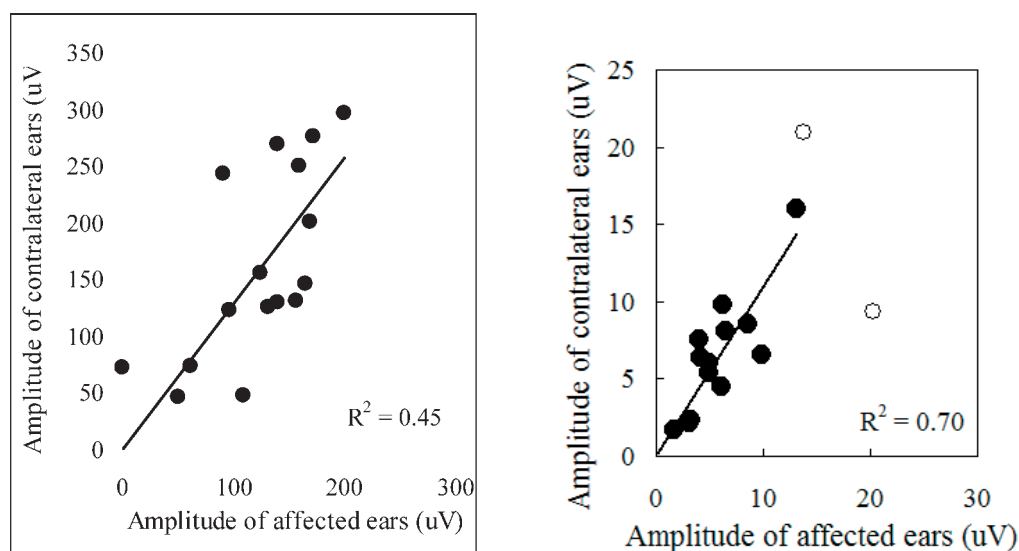


Fig. 1. Comparison of cVEMP (a) and oVEMP (b) amplitudes between ipsilateral and contralateral ears (solid circles). The open circles represent outliers.

## References

1. Vilhena D, Gamboa I, Duarte D, Lopes G. Vestibular Disorders after Stapedial Surgery in Patients with Otosclerosis. *Int J Otolaryngol* Volume 2016, Article ID 6830648, doi 10.1155/2016/6830648.
2. Gros A, Vatovec J, Sereg-Bahar M. Histologic Changes on Stapedial Footplate in Otosclerosis. Correlations Between Histologic Activity and Clinical Findings. *Otol Neurotol* 2003;4(1):43-47.
3. Leonetti JP, Kircher ML, Jaber JJ, Benscoter BJ, Marmora JJ, Feustel PJ. Inner ear effects of canal wall down mastoidectomy. *Otolaryngol Head Neck Surg* 2012;146(4):621-626.
4. Mostafa BE, Shafik AG, El Makhzangy AM, Taha H, Abdel Mageed HM. Evaluation of vestibular function in patients with chronic suppurative otitis media. *ORL J Otorhinolaryngol Relat Spec* 2013;75(6):357-360.
5. Gianoli GJ, Soileau JS. Chronic Suppurative Otitis Media, Caloric Testing, and Rotational Chair Testing. *Otol Neurotol* 2008;29(1):13-15.
6. Colebatch JG, Halmagyi GM and Skuse NF. Myogenic potentials generated by a click-evoked vestibulocollic reflex. *J Neurol Neurosurg Psychiatry* 1994;57(2):190-197.
7. Curthoys IS. A critical review of the neurophysiological evidence underlying clinical vestibular testing using sound, vibration and galvanic stimuli. *Clin Neurophysiol* 2010;121(2):132-144.
8. MacDougall HG, Weber KP, McGarvie LA, Halmagyi GM, Curthoys IS. The video head impulse test: diagnostic accuracy in peripheral vestibulopathy. *Neurology* 2009;73(14):1134-1141.
9. McGarvie, LA, MacDougall, HG, Halmagyi GM, et al. The video head impulse test (vHIT) of semicircular canal function - age-dependent normative value of VOR gain in healthy subjects. *Frontiers Neurol* 2015;6:1-11.





# CT VS CT-MRI FUSION IMAGING IN PREOPERATIVE MASTOID ASSESSMENT FOR CHOLESTEATOMA: IMPLICATIONS FOR ENDOSCOPIC EAR SURGERY

Alexander J. Saxby<sup>1,2</sup>, Laughlin Dawes<sup>3</sup>, Christina Cheng<sup>4</sup>, Samantha Wills<sup>1</sup>, Nicholas Jufas<sup>2,5</sup>, Jonathan Kong<sup>1,2</sup>, Nirmal Patel<sup>2,5</sup>, Simon Greenberg<sup>4</sup>

<sup>1</sup>Royal Prince Alfred Hospital, Sydney, Australia; <sup>2</sup>Sydney Endoscopic Ear Surgery Research Group, Sydney, Australia; <sup>3</sup>Spectrum Medical Imaging, Sydney, Australia; <sup>4</sup>Liverpool Hospital, Sydney, Australia; <sup>5</sup>Kolling Deafness Research Centre, University of Sydney and Macquarie University, Sydney

## Abstract

**Introduction:** Preoperative assessment of cholesteatoma traditionally involves non-contrast temporal bone CT imaging. This can demonstrate opacification of the mastoid cavity, but does not define the boundary between cholesteatoma and sequestered fluid or granulation. Non-echo-planar diffusion-weighted imaging (non-EPI DWI) MRI sequences identify the presence of cholesteatoma, but do not allow precise anatomical localization. Fusion of the two image sets permits estimation of the cholesteatoma/fluid interface which is of preoperative benefit in minimally invasive ear surgery techniques.

**Methods:** Retrospective assessment of CT-MRI Fusion imaging for cholesteatoma over six years. All cases of primary preoperative cholesteatoma which had both plain CT and CT-MRI Fusion imaging were included. Two reviewers assessed the scans independently, in a randomized blinded fashion to determine cholesteatoma extension into the mastoid for each imaging modality.

**Results:** Fifty-eight cases met inclusion criteria. Plain CT imaging demonstrated only 16 cases of cholesteatoma that did not reach the mastoid cavity, predicting feasibility for total endoscopic removal. CT-MRI Fusion imaging identified a further 19 cases that were limited to the middle ear, where the CT imaging had suggested total mastoid opacification. Therefore, CT imaging erroneously predicted mastoid involvement in 45% of cases. Using CT-MRI Fusion as the preoperative measure of mastoid involvement, 60% of cases would be feasible with an endoscopic approach.

**Conclusion:** Cholesteatoma extension beyond the lateral semicircular canal into the mastoid is more accurately predicted by CT-MRI Fusion imaging than plain CT. This tool has high clinical utility, especially in preoperative planning, potentially avoiding unnecessary mastoidectomy with a transcanal endoscopic approach.

## 1. Introduction

Imaging of the temporal bone is a key part of the preoperative assessment of cholesteatoma. It provides the surgeon with critical information in regards to the extent of disease and the potential complications or difficulties which might be encountered during the resection. There now exist a number of well documented and validated approaches to cholesteatoma removal including open approaches using mastoidectomy with wall-up, wall-down and wall reconstructive possibilities as well as minimally invasive techniques such as endaural atticotomy and more recently totally endoscopic transcanal techniques. Knowledge of the extent of disease progression through

Correspondence: Dr Alexander Saxby, Dept of Otolaryngology, Head & Neck Surgery, Royal Prince Alfred Hospital, Sydney, Australia. E-mail: saxbyaj@gmail.com

*Cholesteatoma and Ear Surgery – An Update 2017, pp. 255 -260*

*Edited by Matthew Yung*

*2017 © Kugler Publications, Amsterdam, The Netherlands*

the middle ear and mastoid is therefore of paramount importance in terms of planning the most appropriate approach for the patient and providing them with accurate informed consent.

Non-contrast CT imaging of the temporal bone has been the first choice for preoperative cholesteatoma imaging. Recently there has been increased interest in non-echo-planar diffusion-weighted imaging (non-EPI DWI) with MRI in the assessment of cholesteatoma recidivism, in an effort to avoid unnecessary 'second look' surgery. The reported accuracy of Non-EPI DWI imaging is high with a sensitivity, specificity, positive predictive value and negative predictive value of 91%, 96%, 97% and 85% respectively in a recent systematic review by Jindal *et al.*<sup>1</sup> Both image modalities have their own limitations. CT imaging gives excellent definition of bony structures and demonstrates clearly when there is erosion of important structures such as the ossicular chain, tegmen or otic capsule. However, it is poor at delineating cholesteatoma matrix from fluid which has been sequestered deep to the matrix within the mastoid. Inflamed mesotympanic mucosa and granulation tissue also cannot be differentiated from the cholesteatoma sac and its squamous debris.

Non-EPI DWI can predict cholesteatoma presence down to an accuracy of three to five mm,<sup>2-4</sup> but suffers from poor anatomical localization. It gives an impression of where cholesteatoma resides but in the absence of any bony landmarks, it is not possible to accurately determine the extent of disease with regard to mastoid cavity penetration. Fusion of CT and non-EPI DWI capitalizes on the advantages of each, providing the surgeon with detailed information on both the extent of disease and the anatomical structures involved.

Previous studies have demonstrated excellent correlation of CT-MRI Fusion imaging with regards to operative findings.<sup>2,4-10</sup> This study aimed to look retrospectively at CT-MRI data from the last six years to look specifically at the issue of mastoid penetration. Preoperative imaging by CT alone and with MRI fusion imaging was compared to determine any difference. The consequences of such discrepancies have become more relevant with the advent of the endoscopic approach enabling removal of disease through the ear canal if disease does not extend significantly into the mastoid.

## 2. Methods

### 2.1. Imaging protocol

CT imaging of the petrous temporal bone was acquired with one of two scanners, a Lightspeed VCT 64-detector-row scanner (GE Healthcare, UK), or a Somatom Definition AS+ 128-detector-row scanner (Siemens Healthcare, Germany). Helical scans were performed with a slice thickness of 0.625 mm and field of view 160-190 mm. Tube voltage was 120 kVp. Images were reconstructed on a 512 x 512 pixel matrix.

Diffusion-weighted MRI of the petrous temporal bones was acquired with one of two scanners, an Optima MR360 (GE Healthcare, UK) or Magnetom Assenza (Siemens Healthcare, Germany). Both machines have static field strengths of 1.5T. Gradient strength of the Optima is 33 mT/m and of the Assenza 30 mT/m. Both machines have slew rates of 100 T/m/s. Eight-channel head coils were used for signal reception. Three-mm no-gap non-EPI diffusion-weighted sequences covering the petrous temporal bones were obtained. Field of view was 220 mm. On the Optima, a spin-echo PROPELLER fat-saturated sequence was performed with TR 4600 ms, TE 85 ms, b values of 0 and 1000, for an acquisition time of four minutes. Images were reconstructed on a 256 x 256 pixel matrix. On the Assenza, a HASTE sequence was performed with TR 2000 ms, TE 113 ms, and b value of 1000, for an acquisition time of 5 min 22 seconds. Images were reconstructed on a 384 x 384 pixel matrix.

CT and MR images were then fused using AquariusNet version 4.4 (Terarecon, US). Automated registration was performed. Typically, further manual registration was required. Fused volumes were then reconstructed in axial and coronal planes at 1.3-mm slice thickness and sent to the PACS archive.

### 2.2. Study method

A retrospective assessment CT-MRI Fusion imaging for cholesteatoma from 2010 to 2016. Inclusion criterion was

any image requisition for preoperative cholesteatoma which had both plain CT and CT-MRI Fusion imaging. In the case of bilateral disease, each side was considered independently. Exclusion criteria were any case which had undergone previous surgery, or any case where no diffusion restriction was seen on DWI (i.e., cases which were not in fact cholesteatoma). Two reviewers, one a consultant otologist and one a consultant radiologist, assessed the scans independently. Scans were attributed de-identified codes and assessed in a randomized blinded fashion, first looking only at the CT imaging and then in a newly randomized order, the fusion CT-MRI images were assessed. Therefore the assessment of cholesteatoma extension was not influenced by the alternate method of imaging.

All scans were assessed in the axial plane to determine cholesteatoma extension into the mastoid for each imaging modality. Each scan was categorized as showing disease limited to the attic region and middle ear OR extension into the mastoid cavity. The level of demarcation was taken as the posterior border of the lateral semicircular canal, based on experience showing this to be the limitation of the reach of the endoscopic approach. This coronal plane of demarcation was determined by a horizontal line applied to axial images and intersecting the most posterior aspect of the visualized semicircular canal. Disease anterior to this line was classified as limited to the middle ear, whereas that posterior to the line was considered as invading the mastoid cavity (Fig. 1).

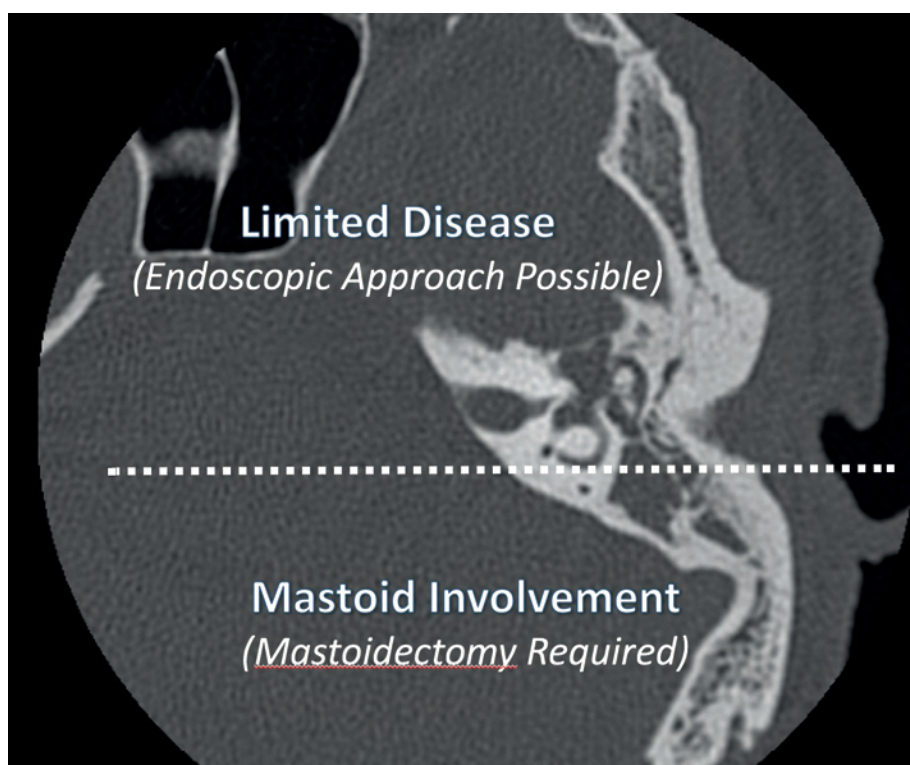


Fig. 1. Line of demarcation used to determine whether disease was limited to the middle ear (feasible for endoscopic approach) or involving the mastoid cavity (necessitating a mastoidectomy). This line was chosen based on experience showing this to be the limit of current endoscopic techniques.

### 3. Results

A total of 58 cases met inclusion criteria; 36 left ear, 22 right ear (five were bilateral). There were 24 female, 34 male ears included. Mean age of patients 40 years (range four to 81 years).

**CT imaging:** Forty-two cases (72%) demonstrated opacification beyond the posterior border of the lateral semicircular canal. Only 16 cases (28%) showed disease limited to the middle ear.

**CT-MRI Fusion imaging:** When the same cases were analyzed with the additional MRI information, the number of cases deemed to have disease limited to the middle ear increased to 35 (60%). Involvement of the mastoid was only evident in 23 cases (40%). Figure 2 illustrates two examples where CT imaging demonstrated complete mastoid opacification but CT-MRI fusion showed disease only limited to the middle ear.

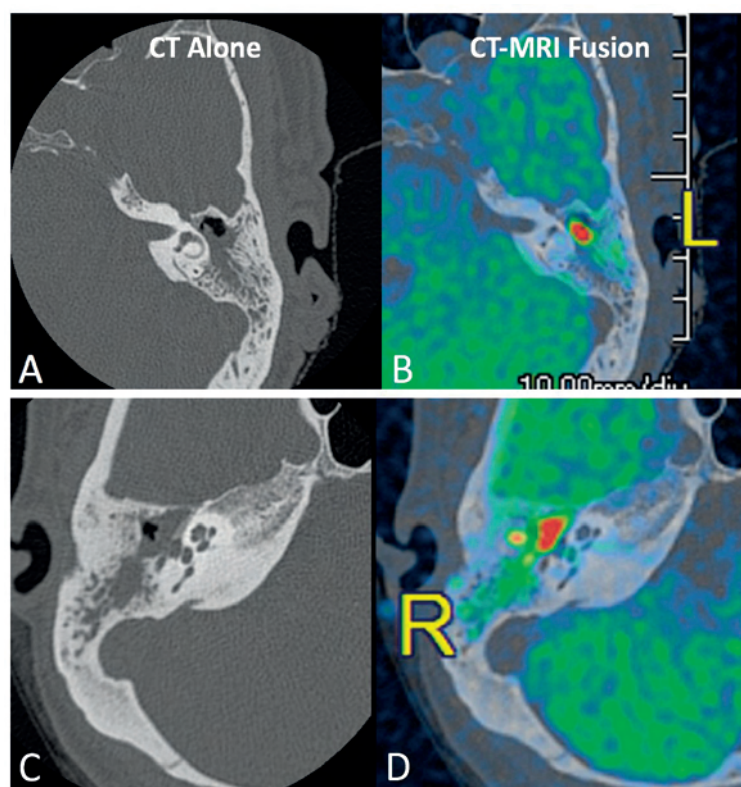


Fig. 2. Two separate examples of cases where the CT scan demonstrated complete opacification of the mastoid cavity but CT-MRI Fusion imaging revealed that the cholesteatoma was limited to the middle ear. Images *B* and *D* show the fused CT-MRI images related to the plain CT images *A* and *C*, respectively.

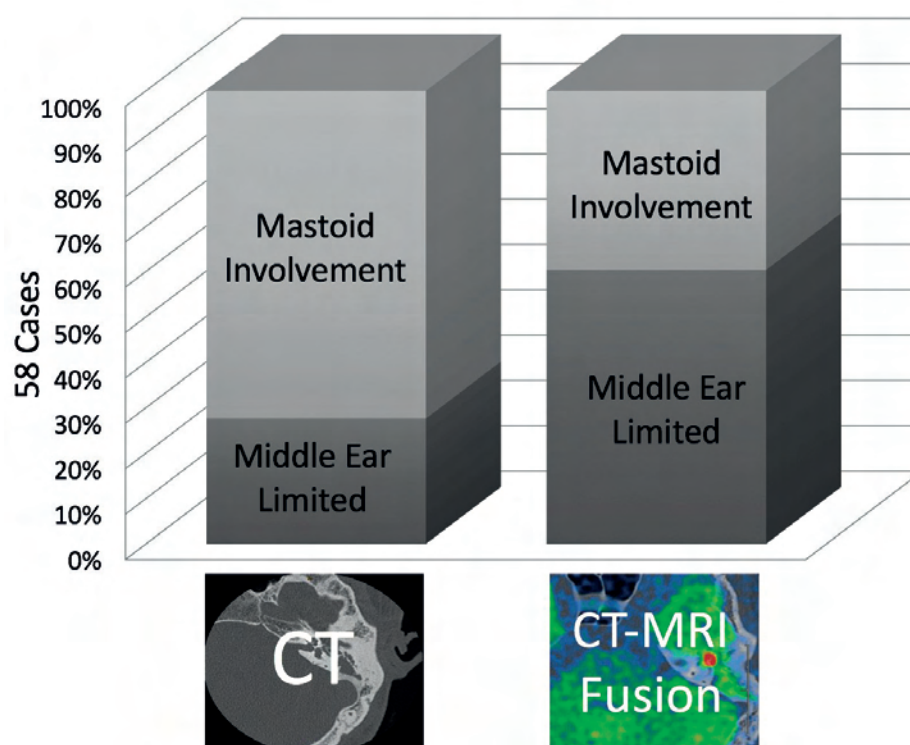


Fig. 3. Bar chart representation of the data series, showing that when CT-MRI Fusion imaging is used to determine mastoid involvement (*right column*), 60% of cases had disease limited to the middle ear and therefore amenable to a totally endoscopic approach. Without the additional Non-EPI DWI information, CT imaging alone (*left column*) suggested that only 28% would be appropriate for the minimally invasive technique.



*Comparison of CT vs CT-MRI Fusion imaging:* CT versus CT-MRI Fusion imaging was discordant in 33% (19/58). However, when just looking at the cases where the CT showed mastoid opacification (42 cases), the percentage of cases where the disease was re-classified as middle ear limited was 45% (19/42). Using CT-MRI Fusion as the pre-operative measure of mastoid involvement, 60% of cases would be feasible with an endoscopic approach (Fig. 3).

In the remaining 23 cases where both CT and CT-MRI Fusion imaging suggested mastoid involvement, the depth of involvement was shown to be less when assessed with CT-MRI Fusion in 35% (8/23). Therefore, in total, CT alone overestimated the mastoid involvement in 47% (27/58).

#### 4. Discussion

In the past, the presence of extensive cholesteatoma mandated a mastoidectomy and so the preoperative assessment of disease extent was of less importance. Surgeons argued that it would be discovered intra-operatively and such information would not change management. More recently there has been a general agreement that preoperative imaging is of benefit in terms of surgical planning for potential complications and informed consent of the patient. A plain CT scan of the temporal bones was adequate for these needs. In recent times with the resurgence of minimally invasive approaches to cholesteatoma, mainly driven by improved endoscopic techniques and equipment, it has become increasingly useful to know the extent of disease penetration of the mastoid, to better plan whether complete excision is feasible by a totally transcanal approach.

This study illustrates that plain CT overestimates mastoid involvement by cholesteatoma because of its inability to differentiate cholesteatoma matrix and squamous debris from sequestered inflammatory fluid or granulation tissue. It was surprising to see that almost half of cases thought to be completely involving the mastoid cavity actually had disease confined to the middle ear and that this could be accurately determined preoperatively.

The choice of the posterior border of the lateral semicircular canal was made based on discussions within the International Working Group of Endoscopic Ear Surgeons (IWGEES) and a general consensus that this represents a reasonable limit of the endoscopic approach, although with further development of the technique this may well change. The authors' experience supports this as a reasonable boundary to use, where disease extending beyond the posterior border necessitates a mastoidectomy approach.

CT-MRI Fusion imaging does not involve any additional radiation to the patient and is a simple and easy to perform investigation. The MRI component is quick, with scans typically taking less than six minutes to perform. Increased cost of the CT-MRI Fusion is a consideration, but this is balanced by the utility of the extra information provided.

The accuracy of any imaging must be considered. While this study clearly points out the potential errors in using plain CT alone in mastoid assessment, it should be noted that MRI can also give erroneous results in the assessment of cholesteatoma. This is particularly the case where a deep retraction pocket has been emptied of its squamous debris, resulting in little diffusion restriction and a failure to positively identify cholesteatoma. However, clinical context and otoscopy also form a crucial aspect of any management decision making. Ultimately the findings at surgery will dictate whether a mastoidectomy is required and preoperative imaging is only a tool to guide surgeons.

Clinical correlation to operative findings was severely limited by the retrospective nature of the study and was not the primary focus of the paper. Poor recording of the extent of disease was found which negated the ability to make any firm correlations. However several previous studies have already shown the accuracy of the CT-MRI fusion in respect to clinical findings.<sup>2,4-10</sup> Future studies will be undertaken looking prospectively with accurate intra-operative documentation to better correlate the imaging findings with specific reference to the limit of the endoscopic approach.



## 5. Conclusion

Fusion of CT with Non-EPI DWI imaging improves the ability to predict mastoid involvement, increasing the numbers of patients who present with apparently extensive cholesteatoma that could be feasibly treated through less invasive transcanal approaches. The finding by this study that almost half of patients whose preoperative CT scan suggests full mastoid involvement actually have more limited disease, is of importance to the surgeon irrespective of their preferred approach.

## References

1. Jindal M, Riskalla A, Jiang D, Connor S, O'Connor AF. A systematic review of diffusion-weighted magnetic resonance imaging in the assessment of postoperative cholesteatoma. *Otol Neurotol* 2011;32(8):1243-1249.
2. Migirov L, Wolf M, Greenberg G, Eyal A. Non-EPI DW MRI in planning the surgical approach to primary and recurrent cholesteatoma. *Otol Neurotol* 2014;35(1):121-125.
3. Ganaha A, Outa S, Kyuuna A, et al. Efficacy of diffusion-weighted magnetic resonance imaging in the diagnosis of middle ear cholesteatoma. *Auris Nasus Larynx* 2011;38(3):329-334.
4. Geoffray A, Guesmi M, Nebbia JF, et al. MRI for the diagnosis of recurrent middle ear cholesteatoma in children--can we optimize the technique? Preliminary study. *Pediatr Radiol* 2013;43(4):464-473.
5. Alvo A, Garrido C, Salas A, et al. Use of non-echo-planar diffusion-weighted MR imaging for the detection of cholesteatomas in high-risk tympanic retraction pockets. *AJNR Am J Neuroradiol* 2014;35(9):1820-1824.
6. Dremmen MH, Hofman PA, Hof JR, Stokroos RJ, Postma AA. The diagnostic accuracy of non-echo-planar diffusion-weighted imaging in the detection of residual and/or recurrent cholesteatoma of the temporal bone. *AJNR Am J Neuroradiol* 2012;33(3):439-444.
7. Kanoto M, Sugai Y, Hosoya T, et al. Detectability and anatomical correlation of middle ear cholesteatoma using fused thin slice non-echo planar imaging diffusion-weighted image and magnetic resonance cisternography (FTS-nEPID). *Magn Reson Imaging* 2015;33(10):1253-1257.
8. Karandikar A, Loke SC, Goh J, Yeo SB, Tan TY. Evaluation of cholesteatoma: our experience with DW Propeller imaging. *Acta Radiol* 2015;56(9):1108-1112.
9. Profant M, Slavikova K, Kabatova Z, Slezak P, Waczulikova I. Predictive validity of MRI in detecting and following cholesteatoma. *Eur Arch Otorhinolaryngol* 2012;269(3):757-765.
10. Watanabe T, Ito T, Furukawa T, et al. The Efficacy of Color-Mapped Diffusion-Weighted Images Combined With CT in the Diagnosis and Treatment of Cholesteatoma Using Transcanal Endoscopic Ear Surgery. *Otol Neurotol* 2015;36(10):1663-1668.

# PRIMARY OBLITERATION OF THE MASTOID CAVITY IN CHOLESTEATOMA SURGERY

Lars P. Schousboe

*Department of Otolaryngology, Vejle Hospital, Denmark*

## Abstract

The necessary access for removal of cholesteatoma extending into the mastoid leaves a cavity. The potential disadvantages of such a cavity include subsequent need for regular cleaning under otomicroscope, difficulty with hearing aids, and insufficient water resistance. In most cases, these disadvantages can be limited by obliteration.

Here is described our strategy for primary obliteration of the mastoid cavity, and our strategy is demonstrated by a presentation of our frequency of obliteration in cholesteatoma surgery. All registered mastoidectomies in the year 2015 were reviewed. Presence of cholesteatoma, canal-wall-up (CWU) or -down (CWD) procedure, obliteration and obliteration material were registered.

Thirty-six mastoidectomies were performed in 2015 on the indications chronic otitis media or suspicion of cholesteatoma. Cholesteatoma was found in 27 cases, four being secondary cholesteatomas. In ten mastoidectomies, the posterior ear canal was preserved (28% CWU), and in the remaining 26 cases the posterior ear canal was removed (72% CWD), thus producing a modified radical cavity. Six out of ten CWU mastoidectomies were obliterated (60%). Twenty-three out of 26 CWD mastoidectomies were obliterated (88%). Cartilage, bone pâté, bone chips or bioactive glass ionomer (four cases) was used for obliteration. Cartilage, perichondrium, fascia or ear canal skin was used to cover the obliteration material in order to facilitate re-establishment the posterior ear canal epithelial lining.

## 1. Introduction

The primary aim of cholesteatoma surgery is eradication of keratinizing epithelium from the middle ear and the mastoid cavity. Secondary goals are prevention of recurrence, restoration of hearing, and reconstruction to produce a dry healthy ear.<sup>1</sup> When the cholesteatoma extends into the mastoid, a mastoidectomy is needed for removal, either from the middle ear into the antrum, or by external opening of the mastoid through the cortex. In open-cavity surgery, the posterior ear canal wall is removed (CWD), forming a modified radical cavity. This technique has the advantage of superior overview and disease control, but known disadvantages such as subsequent need for regular cleaning under otomicroscope, difficulty with hearing aids, and insufficient water resistance.<sup>2</sup> In some cases, the posterior ear canal can be preserved by a combined approach or CWU technique, where the epitympanum is cleared through the ear canal, while the mastoid is approached through the mastoid cortex. This technique offers the obvious advantage of a normal external ear canal, but a higher risk of residual and recurrent disease, presumably because of poorer overview and the risk of renewed retraction.<sup>2</sup> The disadvantages of both techniques can be minimized or avoided by obliteration of the mastoid cavity.<sup>3,4</sup> Here is described our strategy for primary obliteration of the mastoid cavity, and our strategy is demonstrated by a presentation of our frequency of obliteration in cholesteatoma surgery.

Correspondence: Lars P Schousboe, Department of Otolaryngology, Vejle Hospital, Kabbeltøft 25, 7100 Vejle, Denmark.  
E-mail: lars.peter.schousboe@rsyd.dk

*Cholesteatoma and Ear Surgery – An Update 2017, pp. 261 -264*

*Edited by Matthew Yung*

*2017 © Kugler Publications, Amsterdam, The Netherlands*

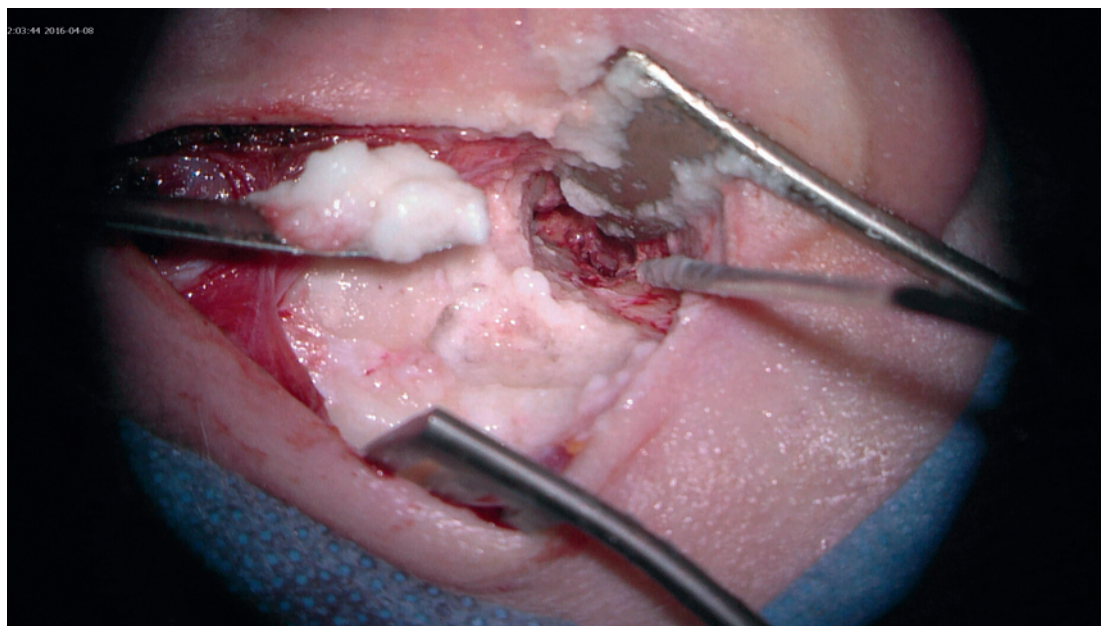


Fig. 1. Cortical bone pâté is collected during the cortical mastoidectomy using a Freer rongeur like a shovel.

## 2. Material and Methods

All registered mastoidectomies in the year 2015 were reviewed. Operations were identified not only by a search of operation codes, but by manual survey of all ear operations listed in our day-to-day operation plans throughout the year 2015. Pure tympanoplasties and myringoplasties were excluded. Presence of primary or secondary (residual or recurrent) cholesteatoma, CWU or CWD procedure, obliteration and obliteration material was registered. The mastoidectomies were performed by two different otosurgeons. Autologous obliteration material was harvested as follows: Cortical bone dust or bone pâté was collected during the cortical mastoidectomy using a rongeur like a shovel (Fig. 1). Collection was done before inflamed or diseased mucosa appeared. Cartilage was taken from the cavum conchae cartilage during the meatoplasty, or from the tragus cartilage, leaving the lateral margin. For fascia, temporal muscle fascia was used. Cortical bone chips from the retro-auricular cranial cortex was occasionally used if there was a shortage of reconstruction material. For secondary obliteration of old cavities, bioactive glass ionomer was used in combination with autologous material for reconstruction of the posterior ear canal.

## 3. Results

Thirty-six mastoidectomies were performed in 2015 on the indications chronic otitis media or suspicion of cholesteatoma. In ten cases the posterior ear canal was preserved (CWU), and in the remaining 26 cases the posterior ear canal was removed (CWD), thus producing a modified radical cavity (Table 1). Six out of ten CWU mastoidectomies were obliterated (60%). Twenty-three out of 26 CWD mastoidectomies were obliterated (88%). Cartilage, bone pâté, bone chips or bioactive glass ionomer (four cases) was used for obliteration. Cartilage, perichondrium, fascia or ear canal skin was used to cover the obliteration material in order to facilitate reestablishment the posterior ear canal epithelial lining. Cholesteatoma was found in 27 cases, four being secondary cholesteatomas.

## 4. Discussion

The necessary access for removal of cholesteatoma extending into the mastoid leaves a cavity. The potential disadvantages of such a cavity can be limited by obliteration in most cases.

*Table 1.* The use of mastoid obliteration in canal-wall-up and canal-wall-down mastoidectomy among 36 mastoidectomies performed in 2015.

	<b>Mastoid obliteration</b>	<b>No mastoid obliteration</b>	<b>Total</b>
Canal-wall-up	6	4	10
Canal-wall-down	23	3	26
Total	29	7	36

In canal wall up surgery, the aim of obliteration is to avoid renewed retraction of the tympanic membrane and cholesteatoma growth into the mastoid antrum. Shaped slices of cartilage from the cavum conchae are fitted into the aditus ad antrum (the communication from the epitympanum to the mastoid antrum) in order to seal off the mastoid cavity from the middle ear. Additionally, the tympanic membrane can be reinforced with thinned cartilage. It could be of concern if closure of the mastoid cavity impedes the pressure regulating capacity of the mastoid. However, as dysfunctional pressure regulation is part of the pathophysiology of cholesteatoma to begin with, and the majority of the mastoid mucosa is removed during drilling, there is hardly any pressure regulating capacity left in a mastoid cavity. Therefore, obliteration of an operated cavity should not be of concern with regards to pressure regulation.

In CWD surgery, the mastoid cavity becomes part of an enlarged external ear canal. Even though simultaneous meatoplasty is performed to secure an equally large opening, the result is often accumulation of cerumen and detritus, problems with inflammation and infection after water exposure, and difficulties with hearing aids due to fitting and moisture. The problems presumably arise because of both impaired self-cleaning capacity of the external ear canal, an enlarged space for detritus accumulation, and the shape of the canal, where the external opening tends to form a relative stenosis. Ideally, the external ear canal should be tract-shaped for optimal detritus removal. We remove the innermost part of the conchal cartilage, incise the canal skin longitudinally and pack the ear canal with gauze and ointment in order to achieve a large opening. Still, the external opening tends to become a relative stenosis.

We collected cortical bone *pâté* simply by using a rougine like a shovel. That is easily done when the irrigation is limited. Other authors use a filter on the suction for collection of bone *pâté*.

An obliterated mastoid could potentially camouflage a later residual or recurrent cholesteatoma and impede secondary surgery, since the material would have to be removed again. Thus the risk of residual or recurrent disease should be taken into consideration before obliteration is decided. In accordance with that it can be noted that none of the four secondary cholesteatomas included here had been obliterated.

Autologous material leaves minimal risk of rejection, inflammation and infection. Some authors soak the material in antibiotic fluid before re-implantation. We do not find that necessary. For obliteration of old cavities, the efforts for and discomfort after harvest of autologous material favor the use of artificial obliteration material.<sup>5</sup>

## References

1. Alves RD, Cabral Junior F, Fonseca AC, Bento RF. Mastoid Obliteration with Autologous Bone in Mastoidectomy Canal Wall Down Surgery: a Literature Overview. *Int Arch Otorhinolaryngol* 2016;20(1):76-83.
2. Harris AT, Mettias B, Lesser TH. Pooled analysis of the evidence for open cavity, combined approach and reconstruction of the mastoid cavity in primary cholesteatoma surgery. *J Laryngol Otol* 2016;130(3):235-241.
3. Cox MD, Dunlap QA, Trinidad A, Dornhoffer JL. Long-term Outcomes After Secondary Mastoid Obliteration. *Otol Neurotol* 2016;37(9):1358-1365.
4. Vercruysse JP, van Dinther JJ, De Foer B, et al. Long-term Results of Troublesome CWD Cavity Reconstruction by Mastoid and Epitympanic Bony Obliteration (CWR-BOT) in Adults. *Otol Neurotol* 2016;37(6):698-703.
5. Bernardeschi D, Pyatigorskaya N, Russo FY, et al. Anatomical, functional and quality-of-life results for mastoid and epitympanic obliteration with bioactive glass s53p4: a prospective clinical study. *Clin Otolaryngol* 2016 Sep 8. [Epub ahead of print]



# CHOLESTEATOMA IN THE DEVELOPING WORLD, WHAT DO WE KNOW, AND WHAT CAN WE DO?

Michael C.F. Smith

*Ear Hospital and Training Centre, International Nepal Fellowship, Green Pastures Medical Complex, Pokhara, Kaski, Nepal*

## 1. Introduction

The developing world is more than just the geography on a map, of principally the more developed northern and the less developed southern nations.

Within the so-called developing countries there are first-rate centers, but the public do not have equal access to them, for many reasons, but mainly cost.

We all want to provide the best and most modern treatments in our units, and those who live and work there are no exception to that.

So, let us take a step back and consider the vast numbers of people in these countries, with no access to even the most basic health care.

I am going to look at the burden of chronic suppurative otitis media in the developing world and in particular that of cholesteatoma, and then consider some ways we might tackle it.

## 2. CSOM incidence/prevalence

- Three hundred thirty million people in the world with CSOM;
- Ninety percent are in Southeast Asia, West Pacific, Africa;
- Lower socio-economic groups;
- Associated risk factors.

It is now well recognised that acute and chronic otitis media are significant public health concerns. CSOM affects hundreds of millions world-wide.

Ninety percent of people with CSOM are in Asia and Africa. Most studies agree that it is commoner in poorer people, many of whom are exposed to risk factors, such as unhygienic and overcrowded living conditions, with frequent URTI's, dietary deficiencies, and smoke exposure. They also have inadequate or delayed access to health care.

Despite all this, CSOM is rarely given priority in health planning.

With our primary health and audiological colleagues we should be the ones to speak out about this, and to provide the answers – if we have them!

We need to consider whether bigger microscopes, endoscopes, lasers, nerve monitors and so on are appropriate. We have to look at cost, longevity, maintenance, the surgical skills required and balance these things with the ambition of the surgeons, like us (we all love a gadget), and the benefits for the patient population.

Correspondence: Michael C.F. Smith, Head and Consultant Otologist, Ear Hospital and Training Centre, International Nepal Fellowship, Green Pastures Medical Complex, Pokhara, Kaski, Nepal.  
E-mail: [mike.smith@earaidnepal.org](mailto:mike.smith@earaidnepal.org)

*Cholesteatoma and Ear Surgery – An Update 2017, pp. 265 -270*

*Edited by Matthew Yung*

*2017 © Kugler Publications, Amsterdam, The Netherlands*



### 3. Prevalence of cholesteatoma in developing countries

- Most large CSOM population studies do not distinguish squamous and mucosal disease;
- Prevalence in developing countries, e.g., Brazil 0.01%, India 0.3-1.2%;
- Overall burden unknown, needs work;
- In Asia, more CSOM is squamous than in Africa or South America;
- CSOM is commoner in certain indigenous racial groups, but these generally have low incidence of cholesteatoma.

There is a great lack of data on ear disease in the developing world. Most studies of CSOM prevalence do not distinguish between cholesteatomatous and non-cholesteatomatous disease. Of the dozen or so that I could find that did, they rarely define their diagnostic criteria or methods. And so prevalence data is very limited and the overall burden is unclear, but given the large populations involved and the backlog of disease, the numbers must be large. Even a conservative prevalence of cholesteatoma in India of 0.3% means three million patients.

The proportion of CSOM due to cholesteatoma is higher in Asia than in Africa or South America. Prevalence rates were similar in countries with very different climates. There are racial variations, some races such as Australian indigenous peoples, Inuit and Navajo have high rates of CSOM, but not of cholesteatoma. Some African studies have stated that cholesteatoma is rare in the developing world, but this is certainly incorrect in the Indian subcontinent, where people seem to be at greater risk.

### 4. Prevention of OM/CSOM/complications

- Primary ear care programs;
- Vaccines;
- Living conditions;
- Antibiotics;
- Early diagnosis and surgery.

So, what can be done?

Primary ear care programs delivered through basic health workers have been shown to be effective in reducing the incidence of CSOM and HI.

Polyvalent pneumococcal vaccines have reduced the incidence of acute otitis media in Western countries.

Improved living conditions and nutrition must help.

Antibiotics have resulted in reduced complications of AOM in developed countries. However, their widespread unscripted use in developing countries, will lead to increasing bacterial resistance.

It is unknown whether reduced AOM or earlier diagnosis can reduce the incidence of cholesteatoma.

### 5. Achieving UN-2030 SDG 3, surgical targets

Global Surgery 2030, Report of the Lancet Commission, 2015.

‘Surgical conditions account for approximately 30% of the global burden of disease [...] provision of surgical care can greatly decrease death and disability.’

‘One quarter of all people who have a surgical procedure will face financial catastrophe as a result of seeking care’

The UN-2030 Sustainable Development Goals replaced the millennium development goals. They have less

emphasis on acute communicable diseases and more on chronic conditions. This potentially helps our case with donors. The Lancet commission report on surgical goals highlights the benefits of surgery, however, no ENT conditions are mentioned.

We need to think carefully about pathways of care, successful interventions and cost-effectiveness if we want to make a strong case for cholesteatoma surgery.

We also need to avoid driving families into medically induced poverty with unnecessary investigations and treatments.

## 6. Access to surgery

Surgical procedures / 100,000 population  
(World Bank 2012)

USA	30,537
Switzerland	25,923
UK	15,280
India	954
Uganda	625
Nepal	451
Malawi	321
Somalia	251

These World Bank figures show the huge inequity in surgical provision in different countries. Whether the gold standard is the UK, Switzerland or the USA I will let you decide!

## 7. Lack of manpower and facilities

- Africa: some nations with no ENT doctors, most with very limited facilities (2009);
- Nigeria survey of ENT Doctors: 41% of ENT units do no ear surgery (2013);
- Central America: gross undersupply of ENT Doctors and facilities (2013).

Surveys such as these from Africa, Nigeria and Central America, show how inequitable the resources are. Within developing countries there is also gross inequity. Doctors and hospitals tend to congregate in profitable cities.

## 8. How can we contribute?

- Data is power;
- Visit, relate, listen, long term;
- Support overseas colleagues and institutions;
- Academic and research support;
- Teach appropriately.

What can those of us based in developed countries do?

For those with a global outlook and concern they can do a great deal. Numbers talk. If we can help collect and analyse data then that information can be used to advocate for patients. Personal visits, and friendships, are vital, especially when long-term. Making links between institutions may benefit both parties. Teaching appropriate methods, under local constraints, such as power cuts may be educational.

## 9. Ear camps, are they effective?

- WHO
- (CSOM, Burden of Illness and Management Options. Role and impact of ear camps and outreach mastoidectomy services, p46-62, WHO, 2004).
- ‘Outreach ear clinics and ear camps are appropriate.’
- Ideally regular, sustained, national led.
- Also advises otological centers, with nationwide referral system.
- They offer several detailed public health scenarios for CSOM.

Some are controversial, *e.g.*, radical mastoidectomy alone as ‘the simplest and safest form of mastoidectomy that would control infection, without necessarily restoring hearing, should be taught to and performed by ENT specialists’.

Many of us have been involved as volunteers on ear camps. Are camps effective for the patients? The WHO in its 2004 review of CSOM management options devotes a lengthy section to this subject and concludes that they are a useful part of the solution. They do provide specialist care for some, but would be best forming part of a national led programme, such as that in Thailand.

The WHO also recommends establishing otological centres and various management scenarios.

We need to be involved in such plans, identifying safe, cost effective, teachable surgeries for common situations. Their recommendation to teach basic radical mastoidectomy alone, does not seem to me to be ideal.

## 10. Nepal rural ear camps

- Ear Camps x 51;
- Patients > 40,000;
- Awareness;
- Relationships.

Having organised and attended over 50 ear camps, I may be biased! However, I have seen a lot of individuals helped, and they raise awareness of the extent of the problem of ear disease and deafness. Working with local organisations and developing long-term relationships is responsible, and avoids accusations of foreigners on ‘surgical safaris’ practising on local people.

## 11. Setting up an ear hospital in Nepal

- Goals;
- Planning phase;
- Opening;
- Running;

- Sustainable financially;
- Keep the vision.

The ear camps showed the need and led to the development of an otological referral center, which opened last year. This was an arduous journey through planning, funding, building, equipping, staffing, visas and even earthquakes. The hospital is now running and we have two Nepali surgeons and one anesthetist, alongside nearly 40 other staff. Sustainability was part of the business model, while offering free treatment to those with inadequate resources. The task now is to further develop training, community work, networking, research and so on.

## 12. Conclusions

- Ears are an underestimated and hidden public health problem, we need to advocate to policy makers;
- Lack of data on cholesteatoma incidence, and outcomes in developing countries;
- Primary health care and health education essential;
- Secondary and tertiary ear care facilities and trained manpower, need development;
- Ear camps and other interventions useful, ideally national led and integrated;
- Volunteers useful as workers, innovators, advisors, encouragers and motivators;
- Need to clarify and teach current best and easiest surgical options;
- Cost effectiveness research, to avoid medically induced poverty;
- Sensitive to local needs, situations and people.



# MRI EVALUATION OF ENDOLYMPHATIC HYDROPS FOR MIDDLE EAR SURGERY

Michihiko Sone, Tadao Yoshida, Satofumi Sugimoto

*Department of Otorhinolaryngology, Nagoya University Graduate School of Medicine, Nagoya, Japan*

## 1. Introduction

Visualization of endolymphatic hydrops (EH) has recently become possible using MRI with contrast agents. EH could be found in cases of candidates for middle ear surgery, such as otosclerosis or ossicular anomaly.<sup>1,2</sup> Preoperative EH could be a risk factor for inner ear disturbances following ear surgeries.<sup>3</sup> We investigated the presence of EH on MRI in ears with clinical otosclerosis or ossicular anomalies, and evaluate the significance of MRI evaluation for the management of middle ear surgery.

## 2. Subjects and methods

Subjects who were diagnosed with having conductive hearing loss, which included otosclerosis or ossicular anomaly, and agreed to MRI examination were randomly recruited in the study. Ears were evaluated by MRI performed four hours after intravenous injection of gadolinium (Gd). The degree of EH in the vestibule and cochlea was classified into three grades (none, mild, and significant). Imaging data were compared with clinical findings. Furthermore in ears operated, imaging data concerning the degree of EH were compared with postoperative clinical courses.

## 3. Results

Varying degrees of EH were observed in the cochleae or the vestibules. Episodes of acute sensorineural hearing loss with rotatory vertigo occurred in some ears that showed significant EH in the cochleae and vestibules. Significant EH, however, was also observed in ears without inner ear symptoms. The postoperative course in ears with no EH in the vestibule was uneventful, with successful improvement of hearing levels, but cases with EH in the vestibule had long period of dizziness. An example case is described next.

### 3.1 Case

A 49-years-old female came to visit our hospital with hearing loss, especially on the left side. She had mixed hearing loss of 70 dB on the left side with 50 dB AB gap in the lower frequencies. Audiological and CT examination revealed that she had bilateral otosclerosis. MRI with Gd showed mild vestibular EH on the left side (Fig. 1). The operation was performed under general anesthesia after obtaining informed consent in terms of the high risk of inner ear disturbance anticipated following stapes surgery. The operative procedure was partial stapedectomy and

Correspondence: : Michihiko Sone, MD, Department of Otorhinolaryngology, Nagoya University Graduate School of Medicine, 65 Tsurumai-cho, Showa-ku, Nagoya 466- 8550 Japan.

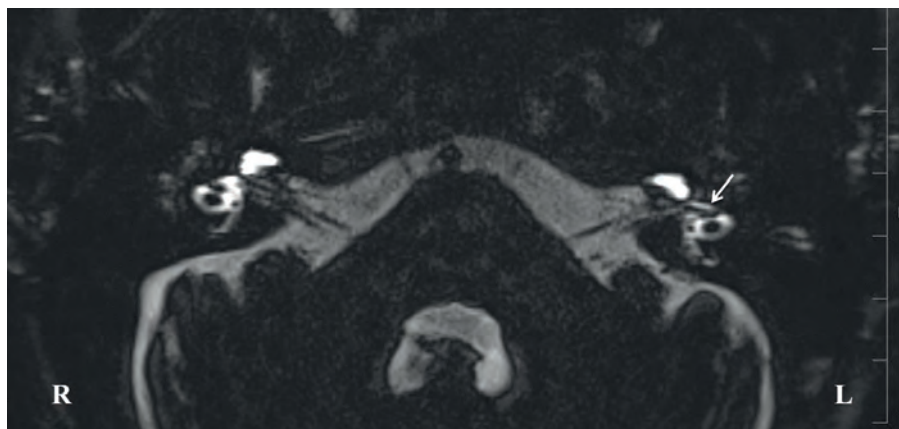
E-mail: michsone@med.nagoya-u.ac.jp

*Cholesteatoma and Ear Surgery – An Update 2017, pp. 271 -272*

*Edited by Matthew Yung*

*2017 © Kugler Publications, Amsterdam, The Netherlands*





*Fig. 1.* The presence of endolymphatic hydrops (EH) can be visualized as black areas surrounded by gadolinium-filled perilymph. Significant EH is present in the vestibule (arrow) on the left ear.

postoperative nystagmus was observed for two days. The patients had dizziness for two weeks, followed by severe vertigo after that.

#### 4. Conclusions

The presence of EH in ears with otosclerosis was clearly visualized in the present patient series. The presence of EH in the vestibule on MRI might be a high risk factor in ears that are candidates for middle ear surgery. Such MRI evaluation could provide useful information for managing symptoms related to EH.

#### References

1. Naganawa S, Yamazaki M, Kawai H, et al. Imaging of Ménière's disease after intravenous administration of single-dose gadodiamide: utility of subtraction images with different inversion time. *Magn Reson Med Sci* 2012;11:213-219.
2. Nakashima T, Naganawa S, Pykkö I, et al. Grading of endolymphatic hydrops using magnetic resonance imaging. *Acta Otolaryngol* 2009;129:5-8.
3. Mukaida T, Sone M, Yoshida T, et al. Magnetic resonance imaging evaluation of endolymphatic hydrops in cases with otosclerosis. *Otol Neurotol* 2015;36:1146-1150.

# ALTERATIONS OF MYC LOCUS IN CHOLESTEATOMA AS AN ANALOGY TO NEOPLASTIC TRANSFORMATION

Krzysztof Szyfter<sup>1</sup>, Małgorzata Jarmuż-Szymczak<sup>1</sup>, Wojciech Gawęcki<sup>2</sup>, Magdalena Kostrzewska-Poczekaj<sup>1</sup>, Witold Szyfter<sup>2</sup>

<sup>1</sup>*Institute of Human Genetics, Polish Academy of Sciences, Poznań, Poland;* <sup>2</sup>*Department of Otolaryngology and Head and Neck Surgery, K. Marcinkowski University of Medical Sciences, Poznań, Poland*

## 1. Introduction

Cholesteatoma is a locally invasive disease, responsible for middle ear and adjacent bone destruction. It is divided into congenital and, much more common, acquired cholesteatoma. Besides its aggressiveness and reoccurring character, cholesteatoma is undoubtedly recognized as being a non-cancerous condition. Concerning etiopathogenesis many theories have been put forward.<sup>1-3</sup> There are many parallel theories, none of which are sufficiently decisive. At least two points require more attention. The first one concerns molecular genetics. Only very recently, modern molecular technologies taking advantage of microarray DNA platforms and proteomics shed more light on the involvement of particular genes and proteins in the process of cholesteatoma formation.<sup>4-6</sup> Other doubts are associated with a role of bacterial infections. A plethora of data is taking bacteria as a casual factor for cholesteatoma.<sup>7</sup> The opposite opinion is linking a bacterial infection to already existing damage in the middle ear canal.<sup>2</sup> Only a microbial infection seems to contribute to aggressiveness, and ongoing proliferation and migration.<sup>2</sup>

The Otolaryngology Clinic at Poznań University is operating annually over 100 cholesteatomas (655 operations in the years 2010-2015). In most cases, the closed-cavity (canal-wall-up, CWU) technique is preferred, however, in some cases the open-cavity (canal-wall-down, CWD) technique is used. The choice of the operation technique depends on many factors like age, actual location and size of cholesteatoma, state of the posterior bony wall of the external auditory canal and pneumatization of the mastoid. Before surgery, a bacteriological examination is done.

On the basis of a literature suggestion of a partial analogy between oncogenesis and cholesteatoma formation<sup>2,4</sup> and our own experience in studies on oncogenes and tumor suppressor genes modulating progression of laryngeal cancer,<sup>9</sup> we have undertaken a molecular analysis targeting for an identification of genetic background of cholesteatoma. The undertaken studies were focused on aberrations and/or rearrangements of *MYC* oncogene harbored in 8q24 chromosome. Literature data have already proven *MYC* deregulation in HNC progression.<sup>10</sup> Also a preliminary evidence for a potential involvement of *MYC* in cholesteatoma pathogenesis has been published.<sup>11</sup>

## 2. Material and Methods

### 2.1. Tissue preparations

Specimens were obtained from 12 patients with acquired cholesteatoma. All the patients showed symptoms of chronic middle ear disease and underwent surgery.

Bacteriologic analysis indicated for *Pseudomonas aeruginosa*, *Proteus mirabilis* and *Staphylococcus aureus* infection as the most commonly detected in middle ear of the studied cases.

Correspondence: K.Szyfter, K. Szyfter, Institute of Human Genetics, Polish Academy of Sciences, 60-479 Poznań, ul. Strzeszyńska 32, Poland.

E-mail: szyfkris@man.poznan.pl

*Cholesteatoma and Ear Surgery – An Update 2017, pp. 273 -276*

*Edited by Matthew Yung*

*2017 © Kugler Publications, Amsterdam, The Netherlands*

Tissue specimens were taken intraoperatively from pathological sites in the mastoid cell or tympanic cavity. Postsurgery explants consisted mostly of epithelium and supporting fibroblasts. Then tissue disintegration was assessed by collagenase digestion (1 mg/ml or 0.5 mg/ml for 42 hours in 37° C).

## 2.2. DNA visualization

A suspension of dead and vivid cells released by explants were stained by 4',6-diamidino-2-phelylindole.2HCl (DAPI) ( $2 \mu\text{gL}^{-1}$  in distilled water).

## 2.3. Fluorescent *in-situ* hybridization (FISH)

Interphase FISH was performed on the fixed cells using commercially available regular and break apart probe IGH/MYC/CEP8 (Vysis, Abbott Molecular, Downers, Grove, IL). Fifty cells were scored per case. The cutoff value for *c-MYC* changes was 1%. Slides were analyzed with a Zeiss Axioimager.A microscope (Carl Zeiss Jena, Germany) and Isis imaging system (MetaSystems).

## 3. Results

The study material contained in each case a large number of dead cells. Using DAPI staining it was established that cells appeared mostly as 'ghost-cells' with membrane associated and traces of nuclear DNA (not shown).

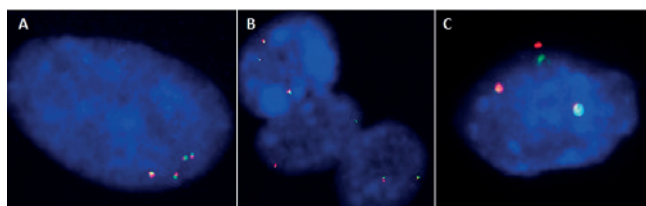


Fig. 1. Demonstration of aberrations and rearrangement of chromosome 8q24 harboring MYC gene by FISH technique. A. Example of a cell with tetrasomy. B. Two cells with the regular signal and one cell with trisomy. C. Trisomic cell with rearrangement of MYC oncogene.

It means that cholesteatoma cells are a subject of progressive degradation by nucleases released in the course of necrosis. Genotoxic damaging activity of bacterial infection is also to be taken into account.

FISH analysis in the studied fibroblasts provided two types of MYC oncogene changes. First tetrasomy (Fig. 1A) and trisomy (Fig. 1B) of the studied fragment were detected as aberrations. It means a gain of DNA copy number in 8q24 was detected by the probe specific for MYC. Further, using dual color probe the translocation within 8q24 band was demonstrated (Fig. 1C).

## 4. Discussion

The results of the study group did not differ from other reports. At least bacterial infection was comparable with the results reported from another region of Poland.<sup>8</sup> At this point it is worth mentioning that cholesteatoma-associated bacterial infection, initially recognized as a disease of lower socio-economical classes, was recently proven to occur in all social groups.<sup>12</sup>

In the study a molecular cytogenetic technique was applied to analyze 8q24 chromosome region to estimate an amplification and/or potential rearrangement(s) of MYC oncogene. FISH technique with the use of specific DNA probes (regular fluorescent, break apart) demonstrated a gain of the DNA copy number in the region harboring *c-MYC* oncogene. This is in agreement with the findings of Ozturk *et al.* using a similar technique on Turkish patients.<sup>13</sup> The Hungarian group went further showing by quantitative PCR an increased expression of MYC gene in acquired cholesteatoma.<sup>14</sup> A higher number of gene copies is usually predestinating increased gene expression that in turn could indicate a fast cell/tissue growth.

It has been shown that uncontrolled cell growth, differentiation and aggressiveness is at least to some extent connected with upregulation of certain oncogenes.

## References

1. Olszewska E, Wagner M, Bernal-Sprekelsen M, et al. Etiopathogenesis of cholesteatoma. *Eur Arch Otorhinolaryngol* 2004;261(1):6-24.
2. Kuo Ch-L. Etiopathogenesis of acquired cholesteatoma: Prominent theories and recent advances in biomolecular research. *Laryngoscope* 2015;125(1): 234-240.
3. Maniu A, Harabagiu O, Schrepler MP, et al. Molecular biology of cholesteatoma. *Rom J Morphol Embryol* 2014;55(1):7-13.
4. Klenke C, Janowski S, Borck D, et al. Identification of novel cholesteatoma-related gene expression signatures using full-genome microarrays. *PLOS One* 2012;7(12):e52718.
5. Britze A, Birkler AID, Gregersen N, Ovesen T, Palmfeldt J. Large-scale proteomics differentiates cholesteatoma from surrounding tissues and identifies novel proteins related to the pathogenesis. *PLOS One* 2014;9(8):e104103.
6. Randall DR, Park PS, Chau JK. Identification of altered protein abundances in cholesteatoma matrix via mass spectrometry-based proteomic analysis. *J Otolaryngol Head Neck Surg* 2015;44:e50.
7. Massanta WO, Hinz R, Zautner AE. Infectious causes of cholesteatoma and treatment of infected ossicles prior to reimplantation by hydrostatic high-pressure inactivation. *Biomed Res Int* 2015; article ID 761259, pp. 234-240.
8. Likus W, Siemianowicz K, Markowski J, et al. Bacterial infections and osteoclastogenesis regulators in men and women with cholesteatoma. *Arch Immunol Therap Exp* 2016;64(3):241-247.
9. Szyfter K, Wierzbicka M, Hunt JL, et al. Frequent chromosomal aberrations and candidate genes in head and neck cancer. *Eur Arch Otorhinolaryngol* 2016;273(2):537-545.
10. Liu Y, Gong LP, Dong XL, Liu HG. Detection of c-MYC oncogene translocation and copy number change in the normal-dysplasia-carcinoma sequence of the larynx by fluorescence in situ hybridization. *Diagnostic Cytopathol* 2012;41(6):515-519.
11. Holly A, Sittlinger M, Bujia J. Immunohistochemical demonstration of c-myc oncogene product in middle ear cholesteatoma. *Eur Arch Otorhinolaryngol* 1995;252(6):366-369.
12. Khalid-Raja M, Tikka T, Coulson C. Cholesteatoma: a disease of the poor (socially deprived). *Eur Arch Otorhinolaryngol* 2015;272(10):2799-2805.
13. Ozturk K, Yildirim MS, Acar H, Cenik Z, Keles B. Evaluation of c-MYC status in primary acquired cholesteatoma by using fluorescence in situ hybridization technique. *Otol Neurotol* 2006;27(5): 588-591.
14. Palkó E, Pólska S, Csákányi Z, et al. The c-Myc protooncogene expression in cholesteatoma. *Biomed Res Int* 2014; 2014:639896. doi: 10.1155/2014/63989.



# OPEN MASTOIDECTOMY AND SOFT-WALL RECONSTRUCTION

Haruo Takahashi

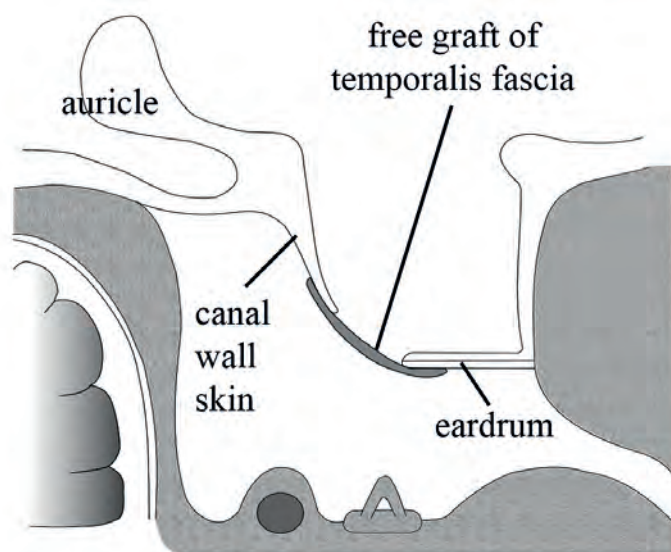
*Department of Otolaryngology - Head and Neck Surgery, Nagasaki University Graduate School of Biomedical Sciences, Nagasaki, Japan*

## 1. Introduction

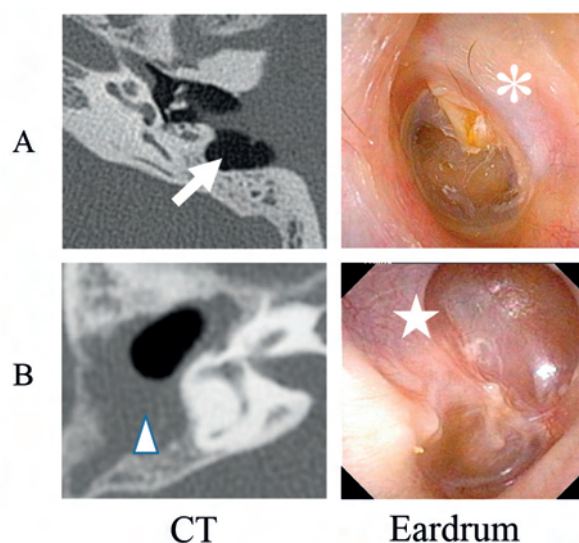
In this session, soft-wall reconstruction (SWR), a versatile method for canal-wall reconstruction after open mastoidectomy, as well as its optional procedures, is introduced.

## 2. Methods

In this procedure, first reported by Smith and colleagues in 1986,<sup>1</sup> the defect of the eardrum and/or ear canal skin after removal of cholesteatoma with the canal-wall-down (CWD) technique is reconstructed only with a piece of a soft tissue like temporalis fascia (Fig. 1). Thus, the posterior canal wall contains no bony tissue (hence the name of this procedure). It is a simple and easy procedure.



*Fig. 1.* Illustration showing the soft-wall reconstruction procedure. The defect in the bony posterior canal wall and the eardrum is reconstructed by a free graft of temporalis fascia.



*Fig. 2.* Condition of mastoid and behavior of the soft wall after surgery. When mastoid mucosa was preserved (A), mastoid aeration recovers in the soon after surgery (arrow) and the soft wall keeps a proper position without retraction (asterisk), while after mastoidectomy (B), mastoid aeration does not recover (arrowhead) and the soft posterior wall skin retracts to be like a radical mastoid cavity (star).

Correspondence: Haruo Takahashi, MD, Department of Otolaryngology – Head and Neck Surgery, Nagasaki University Graduate School of Biomedical Sciences, Sakamoto 1-7-1, Nagasaki City, 852-8501 Japan.  
E-mail: htak0831@nagasaki-u.ac.jp

*Cholesteatoma and Ear Surgery – An Update 2017, pp. 277 -280*

*Edited by Matthew Yung*

*2017 © Kugler Publications, Amsterdam, The Netherlands*



Table 1. Advantages of soft-wall reconstruction procedure.

	CWU	CWD & open mastoid	SWR
Wound healing	early	late	early
Radicality	poor	good	good
Residual lesion	not rare	rare	rare
Recurrent lesion not rare	not rare	rare	rare

### 3. Results

The behavior of the soft wall after surgery is quite interesting (Fig. 2).<sup>2</sup> If we could preserve the mastoid mucosa during surgery, mastoid aeration would recover in the early postoperative stage, and the soft posterior canal wall does not retract, but is shaped like after canal-wall-up (CWU) procedure, by which the mastoid is expected to recover as an aerated cavity. This was the case in about 70% of the patients in our observation. Whereas, after mastoidectomy, mastoid aeration does not recover, and the soft posterior canal wall retracts, thus shaped like after CWD and open mastoid procedure, by which the mastoid is abandoned as a dead space. This is the case in about 80% of the patients. Even if the posterior wall retracts, it is not like a risky pocket, but the whole posterior wall retracts like after a CWD and open mastoid procedure. Their correlation was so high that we could almost predict the postoperative behavior of the soft wall during surgery. Important is that the soft wall chooses its position according to the conditions (capacity) of the mastoid mucosa after surgery. This is why recurrent cholesteatoma is not frequent after this procedure in our series of patients, and, as the bony posterior canal wall is removed, residual lesions are not frequent either.

Furthermore, as the open wound is usually small after this procedure like after CWU, early wound healing is another advantage of this procedure comparing with CWD and open mastoid procedure. Thus, this procedure has advantages of both CWU and CWD and open procedures, as shown in Table 1.<sup>3</sup>

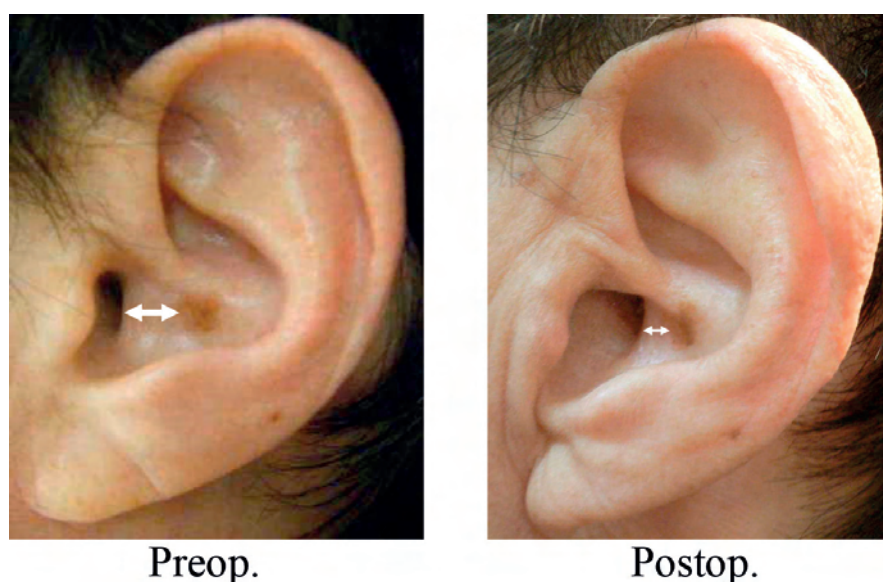


Fig. 3. Findings of entrance of external meatus before (preop) and after (postop) M-meatoplasty. The distances between the posterior edge of the meatal entrance and the pigmentation (both-sides arrows) becomes apparently short after surgery, indicating the entrance was considerably widened by M-meatoplasty.

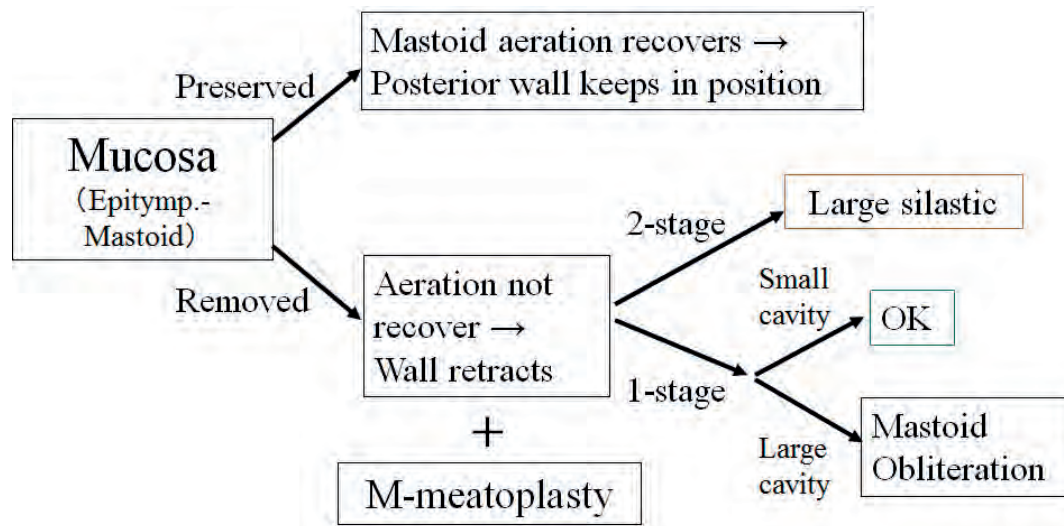


Fig. 4. Algorithm of selection of optional procedures in addition to soft-wall reconstruction. See text for detail.

#### 4. Discussion

This procedure, however, cannot solve all the problems, and several optional procedures help solving those problems.

- After mastoidectomy, the soft wall often retracts to form a radical-mastoid-cavity-like space, and if the space is large, it may cause a cavity problem. In this case, combination of SWR and mastoid obliteration by bone pâté is a good option.<sup>4</sup> After surgery, a posterior canal wall smoothly transiting to the eardrum is formed. When available, usage of a pedicled temporalis fascial flap in addition to bone pâté is more promising.
- It is ideal if the mastoid aeration recovers even after mastoidectomy. In case of planned two-stage surgery, placement of a large-sized silicone sheet covering the Eustachian tube, meso-epitympanum and mastoid, results in a better recovery of mastoid aeration and prevention of retraction of the soft wall. In a significantly higher percentage of patients ( $\pm 60\%$ ), mastoid aeration recovered significantly better, even after mastoidectomy, than in cases without using the sheet.<sup>5</sup>
- The last problem left unsolved is that the entrance of the ear canal remains narrow even in cases with retracted posterior canal skin after mastoidectomy. If we open the posterior canal skin widely as we do during the open method, a large area of open mastoid wound is exposed to the outer ear, and a big advantage of SWR is lost; it takes much time to heal, and also patients suffer from pain for a longer period. To solve this problem, a combination of SWR and M-meatoplasty developed by Mirck seems the best solution.<sup>6</sup> M-meatoplasty consists of extensive removal of subepithelial tissue and cartilage in the cavum concha and coverage of the wound surface by three triangular skin flaps like in Z-meatoplasty, and we can obtain good widening of the meatal entrance without delay of the wound healing (Fig. 3). We use it almost as a routine optional procedure in case after mastoidectomy.

The algorithm of all the optional procedures for the SWR procedures is given in Figure 4.

#### References

1. Smith PG, Stroud MH, Goebel JA. Soft-wall reconstruction of the posterior external ear canal wall. *Otolaryngol Head Neck Surg* 1986;94:355-359.
2. Takahashi H, Honjo I, Naito Y, et al. Cause of posterior canal wall retraction after surgery from viewpoint of mastoid conditions. *Am J Otol* 1998;19:131-135.

3. Takahashi H, Hasebe S, Sudo M, et al. Soft-wall reconstruction for cholesteatoma surgery – reappraisal. *Am J Otol* 2000;21:28-31.
4. Takahashi H, Iwanaga T, Kaieda S, et al. Mastoid obliteration combined with soft-wall reconstruction of posterior ear canal. *Eur Arch Oto-Rhino-Laryngol* 2007;264:867-871.
5. Kazama K, Takahashi H, Kaieda S, et al. Effect of a large-sized silicone sheet upon recovery of mastoid aeration after mastoidectomy. *Otolaryngol Head Neck Surg* 2008;138:738-742.
6. Mirck PGB: How I do it – The M-meatoplasty of the external auditory canal. *Laryngoscope* 1996;106:367-369.

# CLINICAL IMPLICATION OF THE MIDDLE-EAR PRESSURE-REGULATION FUNCTIONS

Haruo Takahashi

*Department of Otolaryngology - Head and Neck Surgery, Nagasaki University Graduate School of Biomedical Sciences, Nagasaki, Japan*

## 1. Introduction

In the keynote lecture, it was discussed how the pathophysiology of various middle-ear (ME) diseases are clinically implicated when viewed from ME pressure-regulation functions, and also how we can use that knowledge in the management of ME diseases. Furthermore, a similar analysis was made in order to discuss the appropriate surgical procedure according to the pathophysiological conditions of ME pressure-regulation functions in each ear.

## 2. Physiology of ME pressure regulation

The ME pressure is regulated by two systems; one is the Eustachian tube (ET) and the other is transmucosal gas exchange (TMGE), mainly in the mastoid. Less is known about TMGE than about the ET.

Both macroscopic and microscopic structural features of the mastoid air cells are similar to those of the lung, where all the gases are exchanged smoothly. In the mastoid, gases are always moving passively between blood and air space, and they move more from where their partial pressure is higher to where it is lower, and this is the way in which ME pressure is regulated.

The TMGE function can be assessed by using nitrous oxide used for general anesthesia.<sup>1</sup> When nitrous oxide is inhaled, it moves quickly towards a closed space like the mastoid. At the same time, the other gases tend to move to the opposite way, but their velocities are slower than that of nitrous oxide. Therefore, the ME pressure increases. As TMGE is the permeability of gases through the ME mucosa, the presence of a rise in pressure in the mastoid indicates a positive TMGE function. We confirmed that TMGE is working in all normal ears.

## 3. Clinical implication of pathophysiology viewed from middle-ear pressure-regulation functions

### 3.1. Otitis media with effusion (OME)<sup>2</sup>

The TMGE function was examined in 84 ears with OME in children, and was found impaired in half of them. Interesting was, that the majority of the ears with an airspace anywhere in the ME in any slice of CT had TMGE, while the majority of the ears without airspace did not have TMGE; the correlation between them was so high that we knew the TMGE function can be assessed by the presence or absence of ME airspace on the CT.

As the ET function is impaired in almost all the ears with OME, ears filled with effusion without airspace should easily get into a dead-locked condition, where the ME is not ventilated via any route. This was confirmed by our other clinical study<sup>3</sup> examining the correlation between the presence or absence of ME airspace (TMGE

Correspondence: Haruo Takahashi, MD, Department of Otolaryngology – Head and Neck Surgery, Nagasaki University Graduate School of Biomedical Sciences, Sakamoto 1-7-1, Nagasaki City, 852-8501 Japan.  
E-mail: htak0831@nagasaki-u.ac.jp

*Cholesteatoma and Ear Surgery – An Update 2017, pp. 281 -284*

*Edited by Matthew Yung*

*2017 © Kugler Publications, Amsterdam, The Netherlands*

function) and the efficacy of conservative therapy in OME ears by antibiotics, and we found that OME ears without airspace in ME are more intractable. We also found that the impairment of the function was reversible in most of ears. Furthermore, we found this dead-locked condition can be detected by a pneumatic otoscope on the basis of a rationale that gases change their volume by the change of pressure while liquids do not. In other words, the eardrum moves when there is an airspace in the ME, while it does not without airspace in the ME, and this was confirmed clinically.

The eardrum mobility test has been regarded as a tool for just diagnosing OME, but it was found to be a good tool for detecting an intractable group of OME without airspace in the ME. Thus, the loss of eardrum mobility could be one of the indicators for surgical treatment of OME, such as tympanostomy tube (TT) insertion.

### **3.2. Non-cholesteatomatous chronic otitis media (COM) with eardrum perforation**

It has been said that the ET function is important for tympanoplasty, but there have been many papers reporting both positive<sup>4-8</sup> and negative<sup>9-12</sup> relationships between preoperative ET function and the outcome of tympanoplasty. A hypothesis was drawn that assessment of both ME pressure-regulation systems may give us good preoperative information, and we conducted a retrospective clinical study, examining the correlation between ME pressure-regulation functions and outcome of type-I tympanoplasty.<sup>13</sup> We found two important results: (1) tympanoplasty was unsuccessful in all four ears with complete obstruction of ET, and it was reconfirmed that ears with obstructed ET are contra-indicated for tympanoplasty; (2) ears in which all three ME pressure-regulation functions, including positive and negative ME pressure equalization of the ET and impaired TMGE function (loss of mastoid airspace), were impaired, had a significantly poor outcome; the ME of ears in this group is not ventilated via any route. Thus, it was found that assessment of both functions may predict the outcome of a tympanoplasty.

The question was, what can we do to handle those factors disturbing the pressure regulation of the ME such as obstruction of ET or soft tissue in the mastoid? We have found that administering low-dose long-term macrolides (macrolide therapy) is effective. Macrolide therapy was effective in 53% of patients with ET stenosis and 51% of those with soft tissue in the mastoid. Since we do not need an emergency surgery when we treat non-cholesteatomatous COM with eardrum perforation, preoperative conservative treatment is likely to be appropriate when there is some factor impairing ME physiological functions, and it may enable us to recover or even improve the conditions, and to minimize surgical intervention.

### **3.3. Middle-ear cholesterol granuloma**

Pathogenesis of the primary ME cholesterol granuloma manifesting the blue eardrum includes ET stenosis or obstruction and poor aeration in the ME, and its pathology consists mainly of granulation formation against foreign body with few infection.<sup>14</sup> This is why we cannot expect the efficacy of antibiotics, but steroids having the strongest anti-inflammatory effect may suppress secretion and improve tubal stenosis. We tried to give 1 mg/kg/day of prednisolone tapering for ten-14 days, and TT was inserted at the end of steroid course.<sup>14,15</sup> In the majority of the younger population, complete cure can be attained, but the efficacy was not so impressive in adults. We found that this treatment should be done in an early stage.<sup>15</sup>

## **4. Mastoid surgery viewed from middle-ear pressure-regulation physiology**

The first important thing we should know would be what happens to the mastoid after tympanomastoid surgery, and our more concrete question was if the TMGE function recovers after mastoidectomy or not. We examined it at the second-stage surgery in patients with planned staged tympanoplasty.<sup>16</sup> Under general anesthesia, we put a micro-pressure sensor into the mastoid and sealed the entrance. Then nitrous oxide was applied, and it was observed if the mastoid pressure would rise. We found that none of four mastoidectomized ears showed a rise in pressure, and that the TMGE function is lost after mastoidectomy.



Then, we drew an algorithm for appropriate selection of procedure viewed from ME pressure-regulation physiology. When the mastoid mucosa could be preserved, canal-wall-up (CWU), with which mastoid is preserved as a functioning cavity, sounds reasonable, whereas when mastoidectomy was done, canal-wall-down (CWD), with which mastoid is abandoned as a dead space, seems to make sense.

A problem is, that it is difficult to precisely judge if the mastoid mucosa can be preserved or not in each case during surgery. Soft-wall reconstruction (SWR) solves the problem.<sup>17</sup> It is interesting that if we could preserve the mastoid mucosa, the mastoid aeration recovers in an early postoperative stage, and in the majority the soft wall does not retract keeping the shape like after a CWU procedure, by which the mastoid is expected to recover as an aerated cavity. Whereas, the soft wall retracts after mastoidectomy in the majority and thus shaped like after CWD and open procedure, by which the mastoid is abandoned as a dead space.<sup>18</sup> Their correlations were quite high, and we can almost predict the postoperative behavior of the soft wall during surgery, and important is that the soft wall chooses its position according to the conditions (capacity) of the mastoid mucosa after surgery. Another advantage of this procedure is that, even when the posterior wall retracts, it is not like a pocket, but the whole posterior wall retracts like after CWD and open mastoid procedure. This is why recurrent cholesteatoma is not frequent after this procedure, and, as the bony posterior canal wall is removed, residual lesions are not frequent either.<sup>19</sup>

## References

1. Takahashi H, Sugimaru T, Honjo I, et al. Assessment of gas exchange function of middle ear using nitrous oxide - a preliminary study. *Acta Otolaryngol (Stockh)* 1994; 114:643-646.
2. Tanabe M, Takahashi H, Honjo I, et al. Gas exchange function of middle ear in otitis media with effusion. *Eur Arch Oto-rhino-laryngol* 1997; 254:453-455.
3. Takahashi H, Honjo I, Hasebe S, et al. The diagnostic and prognostic value of eardrum mobility in otitis media with effusion. *Eur Arch Otorhinolaryngol* 1999; 256:189-191.
4. Holmquist J. The role of the Eustachian tube in myringoplasty. *Acta Otolaryngol (Stockh)* 1968; 66:289-295.
5. Siedentop KH, Tardy ME, Hamilton LR. Eustachian tube function. *Arch Otolaryngol* 1968; 88:386-395.
6. MacKinnon DM. Relationship of pre-operative eustachian tube function to myringoplasty. *Acta Otolaryngol (Stockh)* 1970; 69:100-106.
7. Andreasson L. Correlation of tubal function and volume of mastoid and middle ear space as related to otitis media. *Acta Otolaryngol (Stockh)* 1977; 83:29-33.
8. Honjo I, Fujita A, Sato H, Naito Y, Nakamura H. Eustachian tube function in patients with cholesteatoma. In: Tos M, Thomsen J, Peitersen E, editors. *Cholesteatoma and mastoid surgery*. Amsterdam: Kugler & Ghedini; 1989. P. 455-458.
9. Cohn AM, Schwaber MA, Anthony LS, Jerger JF. Eustachian tube function and tympanoplasty. *Ann Otol Rhinol Laryngol* 1979; 88:339-347.
10. Virtanen H, Palva T, Janhiainen T. The prognostic value of eustachian tube function measurements in tympanoplastic surgery. *Acta Otolaryngol (Stockh)* 1980; 90:317-323.
11. Sheehy JL. Testing Eustachian tube function. *Ann Otol Rhinol Laryngol* 1981; 90:562-564.
12. Fradis M, Podoshin L, Ben-David J. Eustachian tube function as a prognostic tool in tympanoplasty. In: Sade J, editor. *The eustachian tube*. Amsterdam: Kugler Publications; 1987. P. 149-152.
13. Takahashi H, Sato H, Nakamura H, et al. Correlation between middle-ear pressure-regulation functions and outcome of type-I tympanoplasty. *Auris Nasus Larynx (Tokyo)* 2007; 34:173-176.
14. Takahashi H, Honjo I, Kurata K, et al. Steroid and tube insertion for cholesterol granuloma - a preliminary study. *Proceedings of the 6th International Symposium on Recent Advances in Otitis Media*, BC Decker Inc, Toronto, 1997, 414-416.
15. Takahashi H. Middle ear cholesterol granuloma (CG) viewed from ME pressure regulation. *Middle Ear Disease and Surgery Viewed from the Physiology of Pressure Regulation*. Kugler Publication, Amsterdam, The Netherlands, 2017:51-61



16. Takahashi H, Honjo I, Naito Y, et al. Gas exchange function through the mastoid mucosa in ears after surgery. *Laryngoscope* 1997; 107:1117-1121.
17. Smith PG, Stroud MH, Goebel JA. Soft-wall reconstruction of the posterior external ear canal wall. *Otolaryngol Head Neck Surg* 1986; 94:355-359.
18. Takahashi H, Honjo I, Naito Y, et al. Cause of posterior canal wall retraction after surgery from viewpoint of mastoid conditions. *Am J Otol* 1998; 19:131-135.
19. Takahashi H, Hasebe S, Sudo M, et al. Soft-wall reconstruction for cholesteatoma surgery - reappraisal. *Am J Otol* 2000; 21:28-31..

# CLINICAL INCIDENCE AND MANAGEMENT OF OTITIS MEDIA WITH EFFUSION IN VIETNAMESE CHILDREN

Tran Le Thuy, Huynh Ba Tan

*Tran le Thuy, Thuy Tran ENT Clinic, Vietnam; Huynh Ba Tan, Danang Hearing International Center, Vietnam*

## Abstract

**Objective:** Research how often otitis media with effusion (OME) occurs together with other diseases of recurrent upper respiratory infections (RURIs) and gastro esophageal reflux disease (GERD) in small Vietnamese children and finding the active management of this disease group.

**Study:** Retrospective review study.

**Materials and Method:** The Thuy Tran Technique<sup>1</sup> (TTT) had been used. Three hundred RURIs patients aged six months to seven years at the Thuy Tran Otolaryngology Clinic in Hanoi from September 2008 to April 2015 were included. The different diseases in the number of 300 RURIs included OME, recurrent nasopharyngitis (RN), and adenoiditis. Tonsillitis was considered a symptom of RN and is not shown in this statistics. Besides RURIs, gastro esophageal reflux disease (GERD) was found in the research. Diagnosis, and active treatment of the disease group by classical procedures combined with the TTT, limited use of antibiotics and without corticoid.

**Results:** (1) Incidence of OME/RURIs was 234/300: 78.2%, GERD/OME was 161/234: 68%; (2) Infections were gone with hearing recovery in all of 234 OME, follow-up evaluation 12 months after treatment: 7/234 cases recurred, improved later, without complications; (3) RN occurred in all 234 cases of OME; (4) Tonsillitis was gone without tonsillectomy; (5) The health of patients quickly improved.

**Discussion:** (1) In small children, the incidence of OME/RURIs and GERD/OME is high; (2) Indication of ventilation tube insertion (VTI) and adenoidectomy by the classic opinion and combined TTT; this is an active management of OME and RURIs; (3) Tonsillectomy is not necessary; (4) Antibiotics use limited and without corticoid.

**Conclusions:** (1) Today, with antibiotics resistance the classical treatment procedure of OME is inadequate, the combination of TTT is necessary. TTT can control the infectious situation of nasal passage and Eustachian tube; (2) Bacterial and mucosal biofilm research in RURIs in children should be performed; (3) A national program of OME epidemiology in today's polluted environment should be considered; (4) Education of the public about OME and GERD in children is necessary.

## 1. Introduction

In the etiology and pathology of the disease group involved, dysfunctional Eustachian tube (DET) is a key component<sup>2</sup> of the problem. Especially in small children, the Eustachian tube is short, horizontal, weak, easily opened for infectious liquid of RN and GERD coming up to the middle ear.<sup>2-6</sup> Margaretha said that OME is not only a disease of modern times, but it has been a major health problem in many societies.<sup>6</sup> Many research projects<sup>5-8</sup> have been done but the serious hearing complication of OME still occurs often. The classical procedures of middle ear endoscopic, tympanometry, VTI, adenoidectomy, tonsillectomy and using long-term antibiotics are developed.

Correspondence: Thuy Tran Le MD, Number 6 Do Quang st. Cau Giay District, Hanoi, Vietnam.  
E-mail: thuyent12@gmail.com

*Cholesteatoma and Ear Surgery – An Update 2017, pp. 285 -292*

*Edited by Matthew Yung*

*2017 © Kugler Publications, Amsterdam, The Netherlands*

What is the problem we have today? Antibiotics resistance, biofilm, allergies and a seriously polluted environment have developed. OME always hides behind the RURIs; the patient comes to visit an otologist too late with serious obstruction of the airways. The main purpose of this study is to find the best management of OME and which classical procedures should be combined for an active treatment of RURIs.

In Vietnam, some epidemiology research has been done as follows: According to Son,<sup>9</sup> in the study program of acute respiratory infection (ARI) in children of one to 13 years old in different areas of Vietnam, the incidence of otitis media (OM) was 4.8%, ARI was 70.7%. An<sup>10</sup> found that the rate of OME was 8.9% for the children of Hanoi city, one to 14 years old. Son<sup>11</sup> found that the rate of OME was 7.1% in children of the Cu Chi district of Southern Vietnam from six months to ten years old. Recently, Xuong's thesis stated that the incidence of OM is 11.1% in Hanoi children aged to five years.<sup>12</sup> In all of the above-mentioned reports, there was a lack of researched incidence of OME per RURIs. This is a big issue because with small children OME was silent with a symptomatic disease,<sup>13,14</sup> it is difficult to know the onset and time of resolution of each new episode of OME, particularly since the symptoms of RURIs and GERD patients were kept for a long time in the clinic of pediatricians before coming to visiting an Otologist. Closer to our research is the study of Zara *et al.*,<sup>15</sup> who found that the rate of OME/RURI was  $147/350 = 42\%$ .

What is an active treatment? Classical treatment of OME by medicine and VTI, has been mentioned by Bluestone, Schuknecht and others.<sup>3-5,10</sup> Recently, Margaretha and Ellen<sup>6</sup> have advised that the treatment of OME including decongestant/antihistamine, antibiotics, steroids, insertion of ventilation tubes and avoidance of GERD; authors also explained that OME was considered as a complication of RURIs. However, in our infant-children patients of OME, the RURIs happened in serious situations in most cases. Because of that pathological relation we have emphasized that an active treatment of OME would be an active treatment of RURIs. Besides the management of OME by the classical method with VTI, adenoidectomy if indicated<sup>5,6</sup> a method of radical resolution of infection of nasal passage is necessary regarded here as TTT.

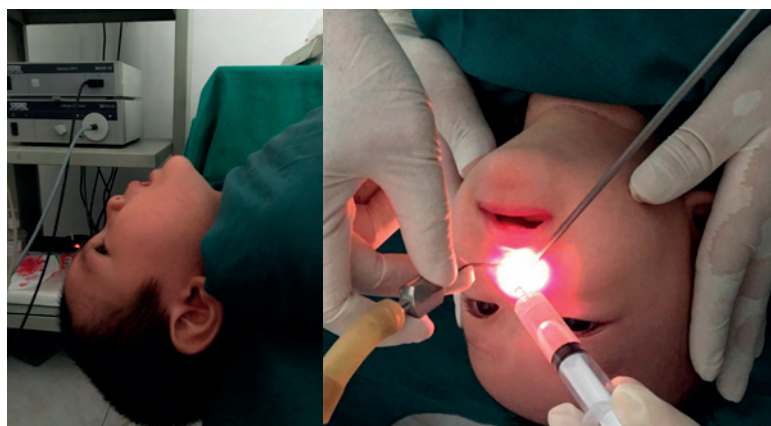


Fig. 1. (a) The endoscopic position of patient of TTT on the Thuy endoscopic bed, with (b) endoscopic system of Karl Storz.



Fig 2. Thuy suction tubes 1.5 mm diameter PV 586015-1, 586015-2, syringes, container of Natri clorid 0.9% and antibiotic solution.

*Position of patient:* With the help of an assistant, the body of the child is surrounded by a soft cotton towel; the child is lying flat on the endoscopic bed with neck reclining at the end of the bed, head down. Under the lighting endoscopic system with hard telescope 2.7 mm, Thuy suction tubes were applied. Ear and throat of the child are examined and then with a quick irrigation cleaning of the nasal passage, the Eustachian tube<sup>7,8</sup> and throat wall are opened with Natri Clorid 0.9% solution. This should take about 60-120 seconds. Infectious secretions of the nasal passage of the patient will be examined. For treatment: after irrigation, a solution of antibiotics is administered into the nasal passage of child. This process is done every day for five to ten days, sometimes longer, until the infection has gone. This is a safe process with excellent results and without complications. The ventilation of the airway and the health of this child quickly improved.

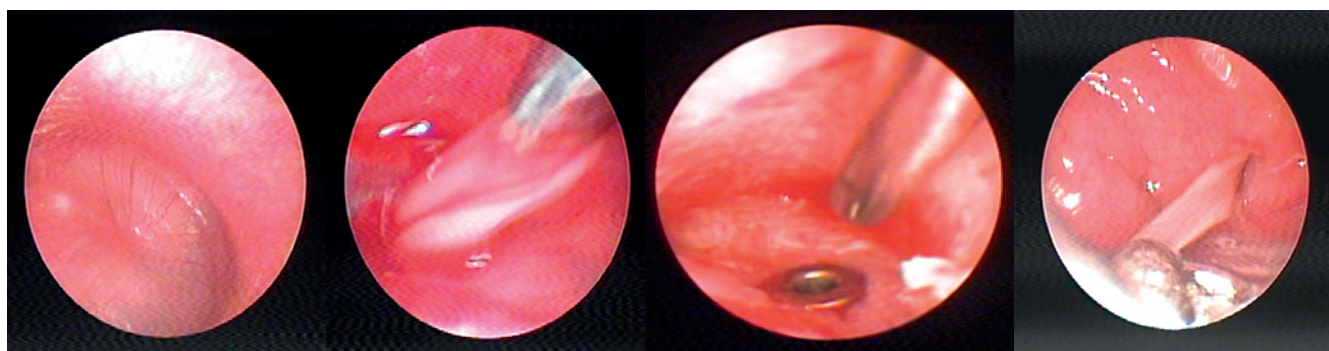


Fig. 3. OME.

Fig. 4. Middle ear opened.

Fig. 5. Ventilation tube insertion.

Fig. 6. Infectious liquid from the left Eustachian tube opening.

TTT has been designed by Thuy Tran Le in 2003, the certificate copyright of the author received from the Vietnamese government in December 2013. This is a special technique of endoscopic irrigation cleaning nasal passage for diagnosis and topical treatment of chronic rhinosinusitis (CRS) in adults and upper respiratory infections (URIs) in infants and children.

## 2. Material and method

This is a retrospective review study with the TTT used. Based on the data collection of 300 patients of RURIs aged six months to seven years, from September 2008 to April 2015 at the Thuy Tran Clinic we research the incidence of OME per RURIs, GERD per OME and suggest an active management for OME and other diseases if this group. The main diseases of RURIs group were OME, RN, adenoiditis, tonsillitis, besides these were symptoms of GERD. An active method will be used in the program, which includes some classical procedures (Figs. 3, 4, 5) and TTT (Figs. 1, 2, 6); with limited antibiotics without corticoid. There will be an evaluation of the effect of the TTT in diagnosis and active treatment of OME. We also have researched the role of the TTT with GERD and tonsillitis. In this context, tonsillitis is considered a symptom of RN and because of that, tonsillectomy was not indicated. Figures 1, 2 and 6 are showing the TTT, and how it may control the infectious nasal passage; purulent is coming out from sinuses and the Eustachian tube opening by Thuy suction tube (produced by the Storz Company).

## 3. Results of diagnosis

Table 1. Incidences of OME per RURIs and other diseases.

1. OME / RURIs =  $234/300 = 78.2\%$ .
2. GERD / OME =  $161/234 = 68\%$ .
3. RN / OME =  $234/234 = 100\%$ .
4. Adenoiditis/OME =  $164/234 = 70\%$ .

Table 2. Four pathology groups detached in 234 OME cases.

1. OME + RN + adenoiditis + GERD: 115 cases.
2. OME + RN + adenoiditis: 49 cases.
3. OME + RN + GERD: 46 cases.
4. OME + RN: 24 cases.

Table 3. Third pathology groups detached in 66 of RURIs without OME (300 RURIs-234 OME = 66 cases).

1. RN + adenoiditis + GERD: 22 cases.
2. RN + adenoiditis: 33 cases.
3. RN + GERD: five cases.

Dominant clinical symptoms of the child are chronic cough, runny nose, nasal obstruction, and vomiting, with a history of RURIs and antibiotics treatment for more two months before our management. Endoscopy of tympanic drum for diagnosis of OME and TTT for control of the infectious situation of nasal-passage finding RURIs and GERD. Tympanogram and subjective audiogram have been made but not in all cases of OME. Depending on the characteristics of the infectious liquid of the middle ear we have an indication for VTI. The result of diagnosis may be found in Tables 1, 2, and 3. Tonsillitis is not shown in these statistics.

#### 4. Results of treatment

Table 4. Active treatment of 234 OME cases.

1. Treatment by VTI: 192/234 OME cases; without VTI: 42 cases (234-192 = 42).
2. Adenoiditis: 164 cases; adenoidectomy: 109/164.
3. ERD treated, eating guide 161/234 OME.
4. Treatment of RN by TTT on all of 234 OME cases.
5. Limited antibiotics, oral seven to ten days, without corticoid.

Table 5. Active treatment of 66 cases without OME.

1. Adenoiditis: 55 cases; adenoidectomy: 43/55 cases.
2. GERD treated, eating guide 27/66 cases.
3. Treatment RN by TTT in all 66 cases.
4. Limited antibiotics, oral seven to ten days. Without corticoid: five.

Comparison between classical (Table 6) procedures and active treatment (Table 7) in 234 OME cases.

Table 6. Classical treatment of OME.

1. VTI (if indicated).
2. Adenoidectomy.
3. GERD treatment.
4. Tonsillectomy.
5. Antibiotics, corticoid long-term, > two months.

Tables 4, 5, and 7 show our active management of OME: three classical procedures, *i.e.*, VTI, adenoidectomy, GERD if indicated; and two procedures of our treatment: TTT and limited antibiotics by oral for seven to ten days, without corticoid. Excellent treatment results in all of 234 OME cases were achieved. The comparison between the classical and our active treatment is shown in Tables 6 and 7.

Excellent results were achieved in all 300 RURIs cases including 234 OME and 66 cases without OME. (1) All of the 234 OME patients have improved completely, including hearing recovery. In 192/234 VTI was performed, and automatically removed after insertion in one to six months. There were 42/234 OME patients without VTI,



Table 7. Our active treatment of OME and RN; comparison of GERD and TTT.

CLASSICAL Procedures	1. VTI: 192/234 OME 2. Adenoiditis: 164/234 OME; Adenoidectomy: 109/164 3. GERD treatment	if indicated
OUR TREATMENT by TTT	4. TTT treatment of RN on all of 234 OME 5. Antibiotics limited, oral seven to ten days on all of 234 OME, without corticoid; Without tonsillectomy	

who have improved well after treatment of the infectious diseases of the airway by TTT. (2) There was excellent improvement in the group of 66 RURIs cases without OME. (3) The tonsillitis, symptoms of RN and adenoiditis were gone. (4) The health of patients improved dramatically. (5) There were no complications.

## 5. Follow-up

After following-up on 234 cases of OME after treatment 12 months, the results are as follows: In the group of 192 VTI cases, seven cases had a recurrence, ventilation tubes were replaced, after which they improved. All of the seven cases of recurrent OME had GERD in the long run. The group of 42 OME cases that received TTT treatment without VTI completely improved.

Hearing recovery: The hearing improved at once after treatment in all of 234 OME cases. In the seven most serious cases, who had recurrence of OME after one year, with GERD long runs, ventilation tubes replaced, the hearing of patient completely improved in the audiogram although some of tympanogram is not yet total normal. This might be explained by the fact that their tympanic membrane is still thick due to the long period of DET, and the scars of VTI.

## 6. Discussion

RURIs in infants and children is a serious pathological problem in which OME is the most common complication.<sup>6-8,14</sup> RN occurred in all 234 OME cases. Besides the classical technique for treating OME with VTI, an active management of RN by TTT is necessary. In the child, the mucosa membrane of nasal passage is thinner and softer than in adults, the empty area of the nasal passage is rather large and the Thuy small suction tube with a smooth head is easy to use. This process quickly irrigates and cleans infectious liquid out of the nasal passage in two minutes. We see the airway of the child change rapidly, even after a long period of infection. TTT is a safe technique of active management with minimal intervention reaching the maximum result in diagnosis and treatment of RURIs in very young patients.<sup>1</sup>

The incidence of OME/RURIs was high,  $234/300 = 78.2\%$  compared to the result of the research by Raza *et al.*<sup>15</sup> which was  $147 \text{ OME}/350 \text{ RURI} = 42\%$ . OME was covered by the symptoms of RURIs, found in a very late stage. This problem has also been recognized by new American guidelines in 2015, OME which overlap with the symptom of viral URI.<sup>16</sup> Otolaryngologists and pediatricians should work together to find OME sooner in children with RURIs.

The incidence of GERD/OME cases was high:  $161/234 = 68\%$ , is the risk factor of OME, seven patients of 234 OME got infectious recurrence after 12 months with GERD over the long runs. Asian authors report an incidence of  $48.4\%$ ;<sup>17</sup> European authors report that of the  $52/65$  OME cases, effusion of OME gave a positive result with the anti-pepsin antibody, recognized pepsinogen; the pepsin in OME is almost certainly due to GERD.<sup>18</sup>



## 7. Conclusion

The incidence of OME per RURIs is  $234/300$  cases = 78.2%, GERD/OME =  $161/234$  = 68%. These numbers may explain that today, OME is always developing with bacterial infections although this study still lacks bacterial and biofilm research. Infections of the nasal passage area become big problems for OME development and re-occurrence. The classical procedure of VTI and medicine is inadequate, the active management of RURIs and GERD is necessary. We state that TTT is the best method, giving excellent results and being safe for RURIs. We also believe that the TTT irrigation cleaning process may treat the mucosal biofilms of OME and RURIs but we do not have the results to demonstrate this supposition. However, research has shown that Biofilm involving H influenza requires low oxygen conditions such as occurs during chronic OME, but they do not form at normal oxygen concentrations.<sup>17</sup> We hope that with an active treatment of blocked infectious airway with the TTT and VTI, the normal oxygen environment of the middle ear, Eustachian tube and nasal passage is reached. Winth *et al.*<sup>19</sup> have determined that in cases of bacterial and biofilm in adenoid tissue and in mucus overlying the adenoid, adenoidectomy and TTT will be the best solution. Biofilm was seen in 92% of the mucosa of children with chronic and recurrent otitis media and in the nasopharynx of children with OM.<sup>20</sup>

Besides excellent results in the treatment of OME, this study shows other benefits of TTT. Tonsillectomy is not necessary and the infection was gone. Tonsils located in the lateral wall of the mouth do not block the airway in all cases when infected. Tonsillitis is considered a symptom of RN. After active treatment of RN with TTT, the tonsillitis was cured.

Finally, we state that in CRS and GERD patients the Politzer test, the Toynbee test or the Valsalva test should not be used because of the possibility of bringing the infectious secretions from the nasal passages through the Eustachian tube to the middle ear.<sup>7,21</sup>

## References

1. Thuy TL. Thuy Tran Technique for diagnosis and topical treatment of Chronic Rhino Sinusitis. Journal of the Yearly Scientific Meeting of Otolaryngology Society of Viet Nam. Hue city, 8-9 June 2012;180-185.
2. Bluestone CD, Klein JO. Otitis Media in Infants and Children. 4th ed. Hamilton, Canada: B.C. Decker Inc. 2007, pp. 21-40.
3. Schuknecht HF. Pathology of the Ear. 2nd ed. Lea & Febiger 1993, pp. 77-79.
4. Casselbrant ML, Mandel EM. Acute Otitis Media and Otitis Media with Effusion. In: Flint PW, Haughey, BH Lund VJ, et al. (eds.), Cummings Otolaryngology – Head and Neck Surgery, 6th ed., pp. 1761-1777. Canada: Mosby Elsevier 2015.
5. Bluestone CD, Klein JO. Otitis Media in Infants and Children, Chapter 8. 4th ed. Hamilton, Canada: B.C. Decker Inc. 2007.
6. Margaretha LC, Ellen MM. Acute Otitis Media and Otitis Media with Effusion. In: Flint PW, Haughey, BH Lund VJ, et al. (eds.), Cummings Otolaryngology – Head and Neck Surgery, 6th ed., pp. 3019-3037. Canada: Mosby Elsevier 2015.
7. Robert CO, Jessica Levi. Anatomy and Physiology of The Eustachian Tube. In: Flint PW, Haughey, BH Lund VJ, et al. (eds.), Cummings Otolaryngology – Head and Neck Surgery, 6th ed., pp. 2027-2037. Canada: Mosby Elsevier 2015.
8. Gates GA. Surgery of Ventilation and Mucosal Disease. Otolologic Surgery, pp. 86-101. Saunders Company 1994.
9. Son NH. Epidemiology and Risk Factors of Acute Upper Respiratory in the different areas of Vietnam. Medical PhD Thesis. ID: 3.01-30, Journal of Hanoi Medical University 1996.
10. An NH. Otitis Media with Effusion of Hanoi children. Medical PhD thesis. Hanoi Medical University 2006.
11. Son DH. The Incidence of Otitis Media with Effusion in Children of Cu Chi District. Journal of The XIIth Scientific Conference of Ho Chi Minh Medical - Pharmacy University, 1997;22-25.
12. Xuong NT. Characteristics and risk factors of hearing loss among children aged 2 to 5 years old in public preschools in inner Ha Noi. Major: Epidemiology, Code: 62.72.01.17, pp. 28. 2014.
13. Bluestone CD, Klein JO. Otitis Media in Infants and Children. 4th ed., pp. 41-72. Hamilton, Canada: B.C. Decker Inc. 2007.
14. Bluestone CD, Klein JO. Otitis Media in Infants and Children. 4th ed., pp. 101-126. Hamilton, Canada: B.C. Decker Inc. 2007.

15. Razw M, Jalil J, Shafique M.,Ghafoor T. Frequency of Otitis Media with Effusion in recurrent upper respiratory tract infections in children. *J Coll Physicans Surg Pak* 2008;18(4):226-229. 04.2008/JCPSP.226229
16. Casey JR, Pichichero MF, American Academy of Family Physicans, Acute otitis media: Update 2015.
17. Miura MS, Mascaro M, Rosenfeld RM. Association between otitis media and Gastro esophageal reflux: a systematic review. *Otolaryngol Head Neck Surg* 2005;133(3):357-361.
18. Tasker A, Dettmar PW, Paneti M, et al. Is gastric reflux a cause of otitis media with effusion in children? *Laryngoscope* 2002;112(11):1930-1934.
19. Winther B, Gross BC, Hendley JO, Erly SV. Location of bacterial biofilm in mucus overlying the adenoid by light microscopy. *Arch Otolaryngol Head Neck Surg* 2009;135(12):1239-1245.doi:10.1001/archoto.2009.186
20. Margaretha L, Casselbrandt, Ellen MM. Acute Otitis Media and Otitis Media With Effusion. In: Flint PW, Haughey, BH Lund VJ, et al. (eds.), *Cummings Otolaryngology – Head and Neck Surgery*, 6th ed., pp. 2019-2022. Canada: Mosby Elsevier 2015.
21. Thuy TL. Dysfunctional Eustachian Tube in the Pathology of Rhinosinusitis, *Vietnam J Otorhinolaryngol - Head Neck Surgery* 2013;58-18(6):66-71.



# INTRODUCTION OF THE JAPAN OTOLOGICAL SOCIETY WORK ON CLASSIFICATION AND STAGING OF CHOLESTEATOMA: THE NATIONWIDE SURVEY OF CHOLESTEATOMA SURGICAL CASES IN JAPAN

Tetsuya Tono<sup>1</sup>, Masafumi Sakagami<sup>2</sup>, Hiromi Kojima<sup>3</sup>, Yutaka Yamamoto<sup>3</sup>, Keiji Matsuda<sup>1</sup>, Manabu Komori<sup>4</sup>, Naohito Hato<sup>5</sup>, Yuka Morita<sup>6</sup>, Sho Hashimoto<sup>7</sup>; The Committee on Nomenclature of the Japan Otological Society

<sup>1</sup>Department of Otolaryngology, Faculty of medicine, University of Miyazaki, Miyazaki, Japan; <sup>2</sup>Department of Otolaryngology, Hyogo College of Medicine, Kobe, Japan; <sup>3</sup>Department of Otolaryngology, Jikei University School of Medicine, Tokyo, Japan; <sup>4</sup>Department of Otolaryngology, National Center for Child Health and Development, Tokyo, Japan; <sup>5</sup>Department of Otolaryngology, Faculty of Medicine, Ehime University, Ehime, Japan; <sup>6</sup>Department of Otolaryngology, Faculty of Medicine, Niigata University, Niigata, Japan; <sup>7</sup>Department of Otolaryngology, National Sendai Medical Center, Sendai, Japan

## 1. Introduction

Because pathophysiological conditions of middle ear cholesteatoma vary considerably from case to case, the operating surgeon is required to make a subjective decision regarding the most appropriate surgical technique for the individual situation, to achieve optimal surgical goals, including disease eradication and subsequent functional and anatomical stabilization. Classification and staging of cholesteatoma provide a standardized assembly of a relatively homogenous group of patients, allowing rational interpretation of surgical results based on respective pathophysiological conditions of the disease process. Needless to say, proper classification criteria can only be created by a consensus-based approach, preferably with the support of an academic society, and should undergo revision over time.

The Japan Otological Society (JOS) staging system for middle ear cholesteatoma has been developed over the past eight years through a consensus-based process led by the steering group of the Committee on Nomenclature of the JOS. The original version of the criteria was prepared for pars flaccida cholesteatoma in 2008. The staging systems for pars tensa cholesteatoma were subsequently developed in 2010 using the same principle. The multi-center study conducted by the steering group confirmed that there was a good correlation between the surgical outcome of cholesteatoma and the staging.<sup>1</sup> The system was initially designed exclusively for retraction pocket cholesteatoma, *i.e.*, pars flaccida and pars tensa cholesteatomas. This was extended to include non-retraction cholesteatoma including cholesteatoma secondary to a tensa perforation and congenital cholesteatoma in a subsequent update as the 2015 JOS staging system<sup>2</sup> (Fig. 1).

## 2. Materials and Methods

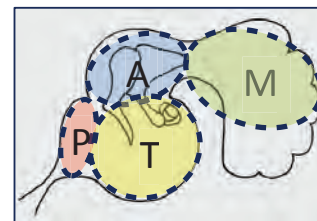
Using the 2015 JOS Staging System, a nationwide survey was conducted to capture the prevalence of cholesteatoma types and stages of surgical cases operated in the year of 2015. The operative methods employed in each case were also included to reveal the current trends of cholesteatoma surgery in Japan. Medical information of the

Correspondence: Tetsuya Tono, MD, Department of Otolaryngology, Faculty of Medicine, University of Miyazaki, 5200 Kihara, Kiyotake, Miyazaki 889-1692, Japan.  
E-mail: [tono@med.miyazaki-u.ac.jp](mailto:tono@med.miyazaki-u.ac.jp)

*Cholesteatoma and Ear Surgery – An Update 2017*, pp. 293 -296  
Edited by Matthew Yung  
2017 © Kugler Publications, Amsterdam, The Netherlands

## 1. Division of middle ear space: PTAM system

The tympanomastoid space is divided into four sections in order to represent the extent of cholesteatoma as shown in this schematic drawing. **P**: Protympanum (Eustachian tube/supratubal recess); **T**: Tympanic cavity (meso-, hypo-, retrotympanum and sinus tympani); **A**: Attic (epitympanum); **M**: Mastoid (mastoid antrum and cells).



## 2. Cholesteatoma staging system

Applicable to the following four types: pars flaccida cholesteatoma; pars tensa cholesteatoma; cholesteatoma secondary to a chronic tensa perforation and congenital cholesteatoma.

### Stage I: Cholesteatoma localized in the primary site

The site of cholesteatoma origin, *i.e.*, the attic (A) for a pars flaccida cholesteatoma and the tympanic cavity (T) for pars tensa cholesteatoma, congenital cholesteatoma and cholesteatoma secondary to a tensa perforation.

### Stage II: Cholesteatoma involving two or more sites

### Stage III: Cholesteatoma with intratemporal and extracranial complications

Facial palsy (FP), labyrinthine fistula (LF): with conditions at risk for membranous labyrinth, labyrinthine disturbance (LD): scale out BC values for more than two speech frequencies (0.5, 1, 2 kHz), canal wall destruction (CW): more than half the length of the bony ear canal, adhesive otitis (AO): total adhesion of the pars tensa, petrous bone or skull base destruction (PB), neck abscess (NA).

### Stage IV: Cholesteatoma with intracranial complications

Purulent meningitis, epidural abscess, subdural abscess, brain abscess, sinus thrombosis.

## 3. Cholesteatoma classification

Acquired cholesteatoma

Retraction pocket cholesteatoma

- a. Pars flaccida cholesteatoma
- b. Pars tensa cholesteatoma
- c. Combination of pars flaccida and pars tensa cholesteatoma

Non-retraction pocket cholesteatoma

- a. Cholesteatoma secondary to a chronic tensa perforation
- b. Transplanted cholesteatoma following trauma or otologic procedures

Congenital cholesteatoma

Unclassifiable cholesteatoma

## 4. Subdivision of stage I for respective cholesteatoma types

### Pars flaccida cholesteatoma and pars tensa cholesteatoma

- Stage Ia: A retraction pocket with epithelial self-cleaning function
- Stage Ib: A retraction pocket with persistent accumulation of keratin-debris

### Cholesteatoma secondary to a tensa perforation

- Stage Ia: Epithelial invasion confined to the underside of the pars tensa
- Stage Ib: Epithelial invasion extending to the tensor tympani tendon and the promontorial wall

### Congenital cholesteatoma

- Stage Ia: Cholesteatoma confined to the anterior half of the tympanic cavity
- Stage Ib: Cholesteatoma confined to the posterior half of the tympanic cavity
- Stage Ic: Cholesteatoma involving both of sides of the tympanic cavity

Fig. 1. The JOS staging and classification criteria for middle ear cholesteatoma.

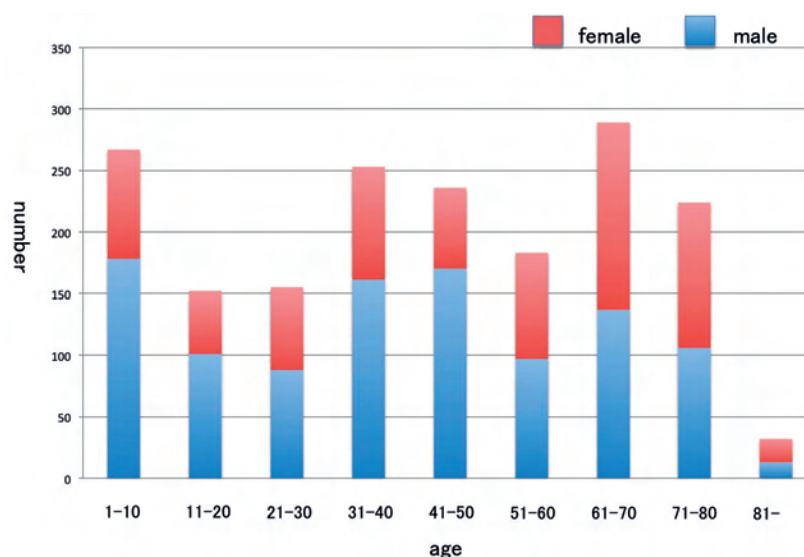


Fig. 2. Age and sex distribution of registered patients (N = 1791).

patients were anonymized and registered through the JOS website voluntarily between 1 January and 29 February 2016.

### 3. Results

One thousand seven hundred ninety-one cases from 74 hospitals from all over Japan have been registered. Age and sex distribution of registered patients are shown in Fig. 2.

The incidence of cholesteatoma types were as follows: pars flaccida cholesteatoma, 1133 cases (63.3%); pars tensa cholesteatoma, 233 cases (13.0%); cholesteatoma secondary to a tensa perforation, 100 cases (5.6%); congenital cholesteatoma, 234 cases (13.1%); and unclassifiable cholesteatoma, 91 cases (5.1%).

Figure 3 presents the distribution of stages in each cholesteatoma type. Stage II was predominant in retraction pocket cholesteatoma, *i.e.*, pars flaccida and pars tensa cholesteatoma, which frequently involve the mastoid, whereas about half of the cases fell into stage I in non-retraction pocket cholesteatoma including cholesteatoma secondary to a tensa perforation and congenital cholesteatoma. In congenital cholesteatoma, stage Ib in which cholesteatoma is confined to the posterior half of the tympanic cavity, slightly dominated over stage Ia where cholesteatoma is located in the anterior half of the tympanic cavity.

Among stage III elements (intratemporal or extracranial complications), labyrinthine fistula was found to be the most common, followed by adhesive otitis, canal wall destruction, petrous bone/skull base destruction, labyrinthine disturbance and facial palsy. Intracranial complications (Stage IV) occurred in only 0.3 % (6 cases) of all cases.

### 4. Discussion

Successful promotion of the use of the JOS staging system for middle ear cholesteatoma has allowed us to conduct a nationwide survey, serving an epidemiological database for international or time-dependent comparison. The current study showed that pars flaccida cholesteatoma occurred with the greatest frequency among four types of middle ear cholesteatoma, accounting for 63.3 % of the surgical cases in Japan. The incidence rate of pars tensa cholesteatoma was about one fifth of that of pars flaccida type and was coincident with that of congenital chole-



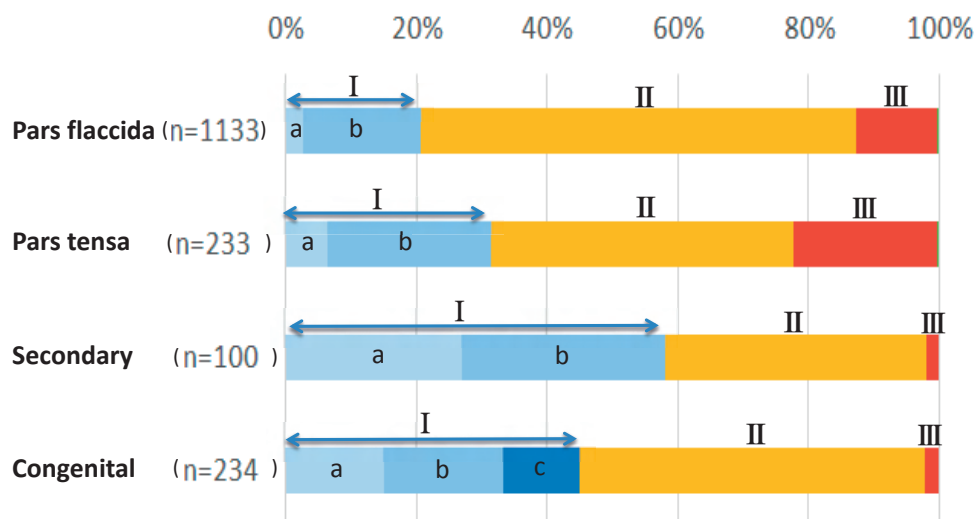


Fig. 3. Distribution of stages (I–IV) in each cholesteatoma type. Stage I is further sub-classified into Ia and Ib for pars flaccida, pars tensa and secondary cholesteatoma and Ia, Ib and Ic for congenital cholesteatoma.

teatoma. It is of note that congenital cholesteatoma were more often found in the posterior half than in the anterior half of the tympanic cavity. This finding is contradictory to several academic studies abroad showing that the typical location of congenital cholesteatoma is in the anterior superior quadrant of the tympanic cavity.<sup>3,4</sup>

The JOS staging system has been widely used in clinical studies of cholesteatoma in Japan, allowing standardization not only in reporting of surgical outcomes but also in clinical communications between physicians and patients based on the respective stage of cholesteatoma. The number of medical articles referring to the JOS system has gradually increased in Japanese literature during the past eight years. Although further revisions may be required for universal acceptance of these criteria, we hope our staging system will open the way for international consensus on staging and classification of middle ear cholesteatoma in the near future.

## 5. Acknowledgements

The authors acknowledge the contribution of JOS members to the vigorous cultivation of the JOS staging system over the past eight years, and the contribution of the members of the Cholesteatoma Guidelines Group of EAONO, Nuri Özgirgin, Ewa Olszewska, Matthew Jung, Armagan Incesulu, Jeff Mulder and Holger Sudhoff for the collaborative dialogue towards future consensus between the EAONO and the JOS on this project.

## References

1. Matsuda K, Tono T, Kojima H, et al. Practicality analysis of the staging system proposed by the Japan Otological Society for acquired middle ear cholesteatoma: A multicenter study of 446 surgical cases in Japan. Submitted to *Auris Nasus Larynx*.
2. Tono T, Sakagami M, Kojima H, et al. Staging and classification criteria for middle ear cholesteatoma proposed by the Japan Otological Society. *Auris Nasus Larynx*. 2017;44:135-140
3. Koltai PJ, Nelson M, Castellon RJ, et al. The natural history of congenital cholesteatoma. *Arch Otolaryngol Head Neck Surg* 2002;128:804-809.
4. Potsic WP, Samadi DS, Marsh RR, Wetmore RF. A staging system for Congenital Cholesteatoma. *Arch Otolaryngol Head Neck Surg* 2002;128:1009-1012.

# POVERTY AND ETHNICITY IN THE AETIOLOGY OF CHOLESTEATOMA; PRELIMINARY DATA FROM NEW ZEALAND'S NORTH CENTRAL REGION

S.C. Toynton<sup>1</sup>, D. Schreiber<sup>2</sup>

<sup>1</sup>Hawke's Bay Fallen Soldiers' Memorial Hospital, Hastings, Hawke's Bay, New Zealand; <sup>2</sup>Central Technical Advisory Services (Central TAS), Wellington, New Zealand

## Abstract

**Introduction:** Indigenous populations have a greater incidence of chronic ear disease, however, it is difficult to separate deprivation and ethnicity as aetiological factors. This preliminary study attempts to do this by examining the surgical intervention rate for several otological conditions, particularly cholesteatoma. New Zealand's official bicultural society provides an ideal opportunity to study this. The separation of these factors is important as it may enable more effective targeting of limited health resources.

**Method:** Surgical intervention data from the six Central North Island District Health Boards (DHBs) was examined for the interventions of myringotomy with or without grommets, myringoplasty, and cholesteatoma related surgery. The patients' ethnicities and address areas were also obtained from this source. NZDep2013 is a census derived deprivation score from which small local areas (mesh blocks) are designated a decile of 1-10 (1 = least deprived). Cross tabulation of the data enables preliminary analysis of four ethnic groups and ten levels of deprivation within the three surgical interventions.

**Results:** Preliminary data showed that Myringotomy/grommet interventions increase substantially with deprivation score (9.2 to 17.7 per 1000 population; decile 1-10 respectively), Maori having more than double the intervention rate per deprivation decile. Maori and Pacific Island Peoples have similar cholesteatoma intervention rates (12-16 per 10,000 per annum) which is more than double that of New Zealand Europeans. This pattern is consistent across the parameters described.

**Conclusions:** Consistent results have been obtained suggesting that ethnicity and deprivation are independent factors, both increasing the surgical intervention rates for grommet insertion, myringoplasty and cholesteatoma surgery.

**Learning Objectives:** Appreciation of social factors such as deprivation and ethnicity are important as targeting health care interventions within ethnic groups is more effective.

## 1. Introduction

It is well established that chronic otitis media is more prevalent in indigenous populations. Those that have been particularly studied are Inuit (12-46%), Australian Aboriginals (12-25%), native North American and Pacific Island people including Maori (4-8%).<sup>1,2</sup> Lowest rates are reported in the UK, some parts of the Middle East and Scandinavia at less than 1%.<sup>1</sup> It is likely that the figures are considerable underestimations in certain areas. Studies which aim to identify the epidemiology of chronic ear disease are necessarily hampered by diagnostic uncertainty,

Correspondence: S.C. Toynton, Dept. Otolaryngology, Hawke's Bay Fallen Soldiers' Memorial Hospital Omaha Road, Hastings 4156, Hawke's Bay, New Zealand.

E-mail: stephen.toynton@hbdhb.govt.nz

*Cholesteatoma and Ear Surgery – An Update 2017, pp. 297 -300*

*Edited by Matthew Yung*

*2017 © Kugler Publications, Amsterdam, The Netherlands*

non-specialist researches and non-representative control groups. There is often little differentiation made between the different types of otitis media, with otitis media with effusion often being included with mucosal CSOM with perforation, and cholesteatoma. A surgical incidence, whilst having its limitations as a measure, aims to differentiate between these types of otitis media whilst also estimating the clinical load of the conditions. This may help in identifying health service provision for the future.

Measures of deprivation are often arbitrary rather than verified measurements. It has been difficult to control for deprivation within ethnic groups, which is crucial to such investigations, as there is a disproportionate representation of indigenous populations within lower socioeconomic groups. This association is clearly demonstrated in the results of the 2013 New Zealand national census.<sup>3</sup> This study aims to identify both deprivation and ethnicity as separate factors by using population derived statistics.

New Zealand has an unusual advantage in that it is a formal bicultural society formed by Treaty. Ethnic sensitivities are openly discussed which enables an unusual degree of statistical and socio-ethnic transparency. Both census data and health statistics are in the public domain. We have derived methods by which such information may be obtained by combining health and census data, taking advantage of the large population samples provided. We hope that this will lead to the development of a straightforward tool which will enable the extraction of similar data in the future.

## 2. Methods

The concept of poverty is measured using a 'consensual model'. This is a measure of perceived deprivation within a defined population. Questionnaire based studies measure the public's perception of minimal need, or a 'lack of socially required necessities'. These perceptions may change from country to country and therefore measures of perceived deprivation may vary. Deprivation measurements are considered a surrogate for poverty, based on these perceptions.<sup>3</sup> From the 2013 New Zealand National Census, a deprivation score (NZDEP13) was derived.

Census data in New Zealand may be analysed according to geographical area: regions, territories, area units and mesh blocks. Mesh blocks are the smallest areas targeted to consist of approximately 60 households. Average deprivation scores are obtainable down to this smallest unit. These scores, from every mesh block in New Zealand, are ranked and then divided into deciles. Subsequently each mesh block is allocated a deprivation decile.

Health statistics are acquired via similar methodology, the smallest block being a health domicile. This is equivalent to a mesh block in census terms, however, is not identical. This is due to immigration and emigration into and out of mesh blocks, declining local populations and other factors. A statistical software solution has been developed to match mesh block and health domicile data enabling the compilation of average scores within these small areas to make them more representative (Central TAS).

Various data, including a declaration of ethnicity, are captured during an individual's health registration process. Coding information relating to procedures and baseline data, without identifiers, is collected centrally. Data extraction from the centralised database was performed by using ICD10 codes (H71.X) that identifies cholesteatoma related procedures. Data was also collected separately for myringoplasty and for myringotomy and ventilation tube insertion. A single patient intervention record relates the procedure to their ethnicity and this is matched by address to the mesh block deprivation decile.

A ten-year period from 2005 to 2016 was sampled that included data from all five District Health Boards.

## 3. Preliminary results

Pivot plots were created comparing deprivation deciles with cholesteatoma interventions and normalised to a rate per 100,000 population per annum. A clear trend was observed whereby all interventions examined were

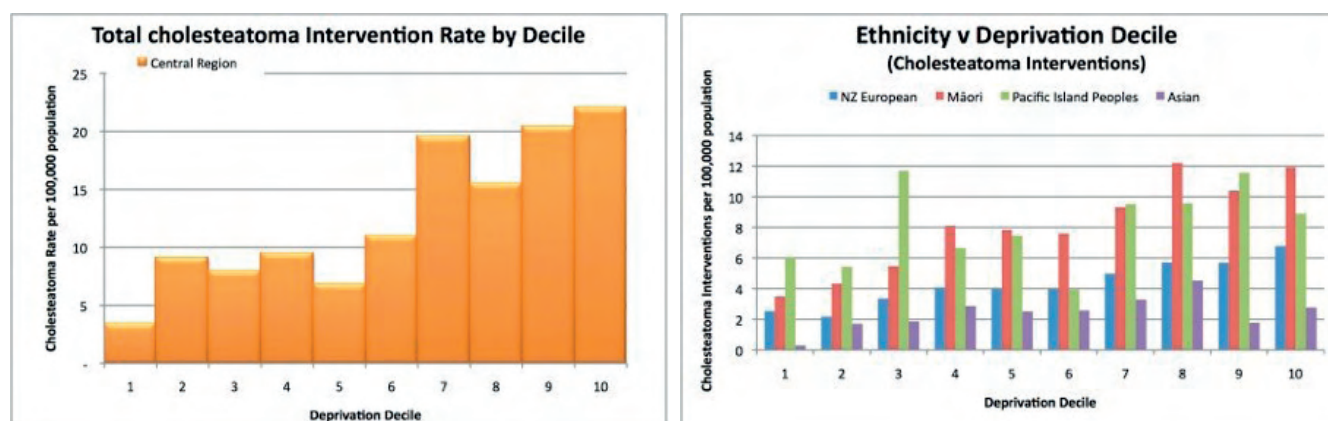


Fig. 1. Surgical Interventions for Cholesteatoma by Deprivation Decile (Note: decile 1 is least deprived) Fig.2. Surgical Interventions for Cholesteatoma, Deprivation Deciles split by Ethnicity

less frequent within deprivation decile 1 (least deprived) and progressively increased with each consecutive deprivation decile.

The number of surgical interventions within each deprivation decile were plotted (Fig. 1). This data was then split by ethnicity into Maori and New Zealand European, Pacific Island peoples, and Asian groups (Fig. 2).

#### 4. Discussion

Although these preliminary results require further statistical evaluation there appears to be a clear trend for both ethnicity and deprivation acting as separate factors. With increasing deprivation there is a progressive increase in the number of cholesteatoma (and other otological) interventions. This is consistent across all of the racial groups studied, except for the Asian group where the trend was far less pronounced. Pacific Island Peoples and Maori appear to have a very similar trend in most of the deprivation centile groups. These have approximately double the intervention rates, at all deciles, compared to New Zealand Europeans, although Asian people appear to have about half their rate. This may reflect their relatively low numbers, health access issues or, perhaps more likely, an inherent relative resistance to ear disease.

The methodology used in this study has at least three distinct advantages: (1) The use of pooled data from large population samples; (2) Specialist-obtained diagnostic data that may be more accurate than those obtained in screening studies; and (3) The ability to look at patient data on a large scale without identifying any individual.

There are, however, a number of potentially confounding factors. Coding, although performed by trained DHB coders, may not be consistent between hospitals and regions. Several surgical interventions, on the same patient, will be counted as separate records. Surgeons in different regions, and even those within individual DHBs, may have differing views regarding the surgical management of cholesteatoma. This may result in repeat planned procedures for staged surgery occurring with a higher frequency in some places. For this reason examining the data by smaller regions, DHB or even individual surgeon would decrease the study validity. This epidemiological technique aims to diminish the impact of these inherent variations.

The advantage of the concept of surgical incidence is that it utilises data which is reasonably robust, already exists and is easily accessible. It assumes that access to surgical care is the same across the ethnic groups and also within the deprivation deciles. Regrettably, this is unlikely to be the case, although the predicted bias would be in favour of those with poorer health access, *i.e.*, the indigenous ethnic groups and higher deprivation deciles.

In common with many public service studies a source of potential bias is the absence of any private surgical data. This may result in an underestimate of interventions in lower deprivation deciles, and possibly also in mid deciles where private insurance is provided for company staff. This may explain the relatively flat nature of the histograms in the mid-centile data (Figs. 1 and 2).

The declaration of ethnicity in census and health data is complex. Individuals being able to declare more than

one ethnicity, however when analyzed, deference is made to the indigenous ethnicity (Maori in this case) even if not placed in top position.<sup>4</sup> This may mean that there is an over representation of non Maori within the Maori groups, although this would be expected to decrease the observed effect of ethnicity on the results.

## 5. Conclusions

Deprivation and ethnicity both appear strongly related to interventional rates for cholesteatoma across the decile ranges. The method used enables very large numbers of interventions to be analysed against census and other community health parameters. Previous studies have shown an increased effectiveness of health care interventions if delivered in an appropriate cultural context and that addressing the general health burden decreases the prevalence of otitis media with time.<sup>5</sup>

This study is preliminary and although the trends appear very convincing, further formal statistical analysis and validation is in progress.

## Declarations

1. The work and views expressed in this study are those only of the authors.
2. Central TAS is an organisation which works to support district health boards with various aspects of healthcare planning, systems and analysis.(<http://centraltas.co.nz>)
3. This work is based on/includes Statistics New Zealand's data which are licensed by Statistics New Zealand for re-use under the Creative Commons Attribution 4.0 International licence. Statistics New Zealand provide free online public access of census data as used in this study.(<http://www.stats.govt.nz>)
4. No identifiable individual patient level data has been used in this study.
5. For reasons of consent, jurisdictions and statistical accuracy, no comparative analysis of individual health districts or geographical areas has been analysed in this study,
6. No comparative analysis of individual interventions by health district has been analysed as consent has not been obtained from individual surgeons, departments or Health Boards for this purpose.

## References

1. Acuin J. Chronic suppurative otitis media: burden of illness and management options. Dept. of Child, Adolescent Health, Development, WHO Programme for the Prevention of Blindness, and Deafness, World Health Organization 2004:13-17.
2. Daly KA, Hoffman HJ, Kvaerner KJ, et al. Epidemiology, natural history, and risk factors: Panel report from the Ninth International Research Conference on Otitis Media. *Int J Pediatr Otorhinolaryngol* 2010;74:231-240.
3. Atkinson J, Salmond C, Crampton P. NZDep2013 index of deprivation. University of Otago 2014.
4. Didham R, Callister P. The effect of ethnic prioritisation on ethnic health analysis: a research note. *N Z Med J* 2012;125:58-66.
5. Giles M, Asher I. Prevalence and natural history of otitis media with perforation in Maori school children. *J Laryngol Otol* 2007;105:257-260.

# EPIDEMIOLOGY OF PEDIATRIC OTITIS MEDIA IN TAIWAN

Mao-Che Wang

*Department of Otolaryngology Head Neck Surgery, Taipei Veterans General Hospital, School of Medicine, Yang-Ming University, Taipei, Taiwan*

## 1. Introduction

Otitis media with effusion is a very common pediatric otologic problem. We try to report the epidemiology of pediatric otitis media with effusion and common comorbidities by using ventilation tube insertions as a surrogate. We also studied surgical and medical preventions of pediatric ventilation tube insertions.

## 2. Methods

We retrieved study objects from Taiwan National Health Insurance Research Databank (NHIRD). We analyzed characteristics and comorbidities of all children who received ventilation tube insertion from July, 2000 to December 2009. We also analyzed the recurrent pattern by following the year 2000 and 2001 birth cohort for eight or nine years.

## 3. Results

From July, 2000 to December 2009, 11042 ventilation tube insertions were done in Taiwan. For all children who had a ventilation tube insertion, the mean age at insertion was  $5.4 \pm 3.3$  years. Thirty-six percent of them had concurrent adenoidectomy, 15.4% with cleft palate, 7% with Down syndrome (Fig. 1). For the 2000 and 2001 birth cohort, 1755 (0.393%) children received a ventilation tube insertion and 111 (6.3%) had tube re-insertions before they were eight or nine years old. Adenoidectomy had a protective effect on pediatric ventilation tube re-insertions for otitis media with effusion. (Fig. 2).<sup>1</sup> Administering a pneumococcal conjugate vaccine may have a protective effect on pediatric ventilation tube insertions for otitis media with effusion (Fig. 3).<sup>2</sup>

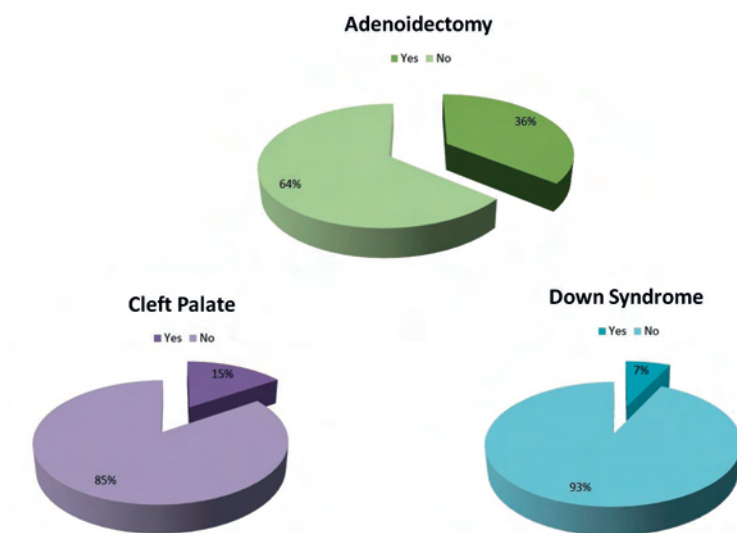


Fig. 1. Comorbiditis of pediatric ventilation tube insertions.

Correspondence: Mao-Che Wang, MD, 201 Sec 2 Shih-Pai Rd, Taipei Taiwan.  
E-mail: wangmc@vghtpe.gov.tw

*Cholesteatoma and Ear Surgery – An Update 2017, pp. 301 -304*  
*Edited by Matthew Yung*  
2017 © Kugler Publications, Amsterdam, The Netherlands



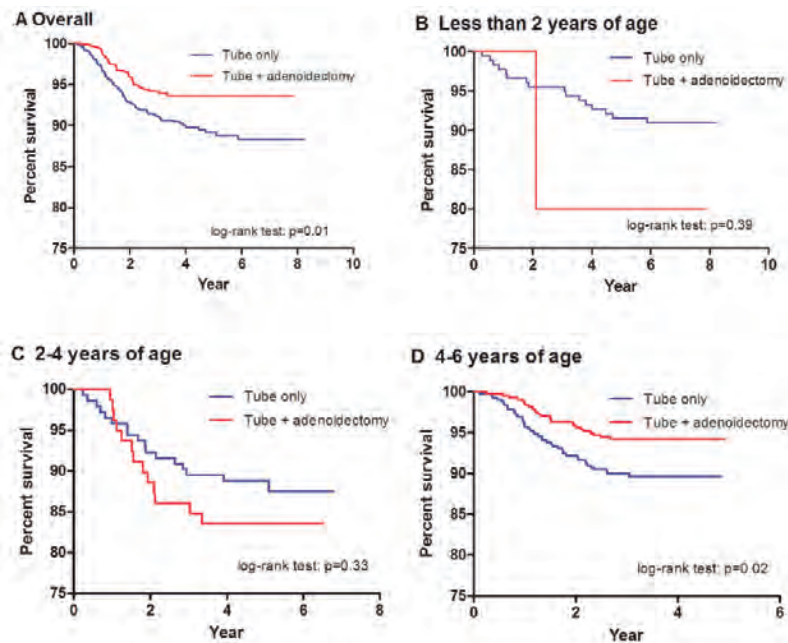


Figure 2. Survival curve of tube re-insertions. (A) Overall recurrence. (B) (C) and (D) Recurrence stratified by age.  
Fig. 2. Survival curves of tube re-insertion with or without adenoidectomy.

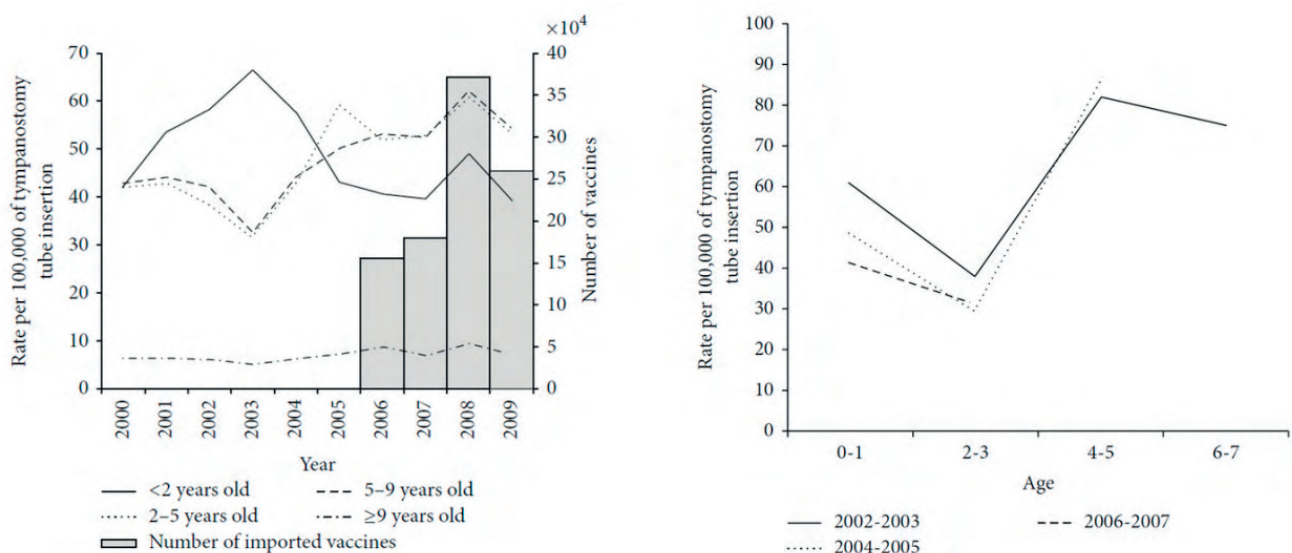


Fig. 3. The protective effect of pneumococcal conjugate vaccine on pediatric ventilation tube insertions.

#### 4. Conclusion

We included around 1200 children who received ventilation tube insertions in Taiwan in our study, and a good portion of them had comorbidities such as cleft palate, Down syndrome. Six point seven percent of children may have tube re-insertions.

Learning objectives: By using the population based database NHIRD, we can accurately report the epidemiology of pediatric otitis media with effusion with ventilation tube insertions as a surrogate. We can also conduct studies to find out risk factors and prevention methods for pediatric otitis media with effusion by using the population-based database NHIRD.

## References

1. Wang MC, Wang YP, Chu CH, et al. The Protective Effect of Adenoidectomy on Pediatric Tympanostomy Tube Reinsertions: A Population-Based Birth Cohort Study. *Plos One* 2014 ;9: e101175
2. Wang MC, Wang YP, Chu CH, et al. Impact of Pneumococcal Conjugate Vaccine on Pediatric Tympanostomy Tube Insertion in Partial Immunized Population. *The Scientific World Journal* 2015; 2015: Article ID 248678



# **PRACTICALITY ANALYSIS OF JOS STAGING SYSTEM FOR CHOLESTEATOMA SECONDARY TO A PARS TENSA PERFORATION: JAPAN MULTICENTER STUDY (2009-2010)**

Yutaka Yamamoto<sup>1</sup>, Tustuya Tono<sup>2</sup>, Hiromi Kojima<sup>1</sup>, Yuka Morita<sup>3</sup>, Masafumi Sakagami<sup>4</sup>, Yasuo Mishiro<sup>4</sup>, Taeko Okuno<sup>5</sup>, Yasuyuki Hinohira<sup>6</sup>, Keiji Matsuda<sup>2</sup>, Sho Hashimoto<sup>7</sup>

<sup>1</sup>Jikei University School of Medicine, Japan; <sup>2</sup>Miyazaki University, Japan; <sup>3</sup>Niigata University, Japan; <sup>4</sup>Hyogo College of Medicine, Japan; <sup>5</sup>Mitsui Memorial Hospital, Japan; <sup>6</sup>Kamio Memorial Hospital / Syowa University, Japan; <sup>7</sup>National Sendai Medical Center, Japan

## **1. Introduction**

The committee on Nomenclature of the Japan Otological Society (JOS) was appointed in 2004 to create a cholesteatoma staging system widely applicable in Japan. In this paper, the clinical features of the cholesteatoma secondary to a pars tensa perforation and congenital cholesteatoma were evaluated and the pathogenesis of the disease was discussed by analyzing the data of a multi-center pilot study carried out between 2009 and 2010.

## **2. Methods**

Between 2009 and 2010, a total of 599 ears that underwent surgery for fresh cholesteatoma at six institutions in Japan were recruited and cases with cholesteatoma secondary to a pars tensa perforation and congenital cholesteatoma were selected. Incidence of the disease and clinical characteristics were evaluated retrospectively. We evaluated the progression of cholesteatoma according to the 2015 JOS cholesteatoma staging and classification systems.

### **2.1. 2015 JOS cholesteatoma staging and classification system for cholesteatoma secondary to a pars tensa perforation**

Stage I: Cholesteatoma localized in the tympanic cavity

Stage Ia: Epithelial invasion confined to the underside of the pars tensa

Stage Ib: Epithelial invasion extending to the tensor tympani tendon and the promontorial wall

Stage II: Cholesteatoma involving two or more sites

Stage III: Cholesteatoma with intratemporal complications and/or pathologic conditions

Stage IV: Cholesteatoma with intracranial complications

### **2.2. 2015 JOS cholesteatoma staging and classification system for congenital cholesteatoma**

Stage I: Cholesteatoma localized in the tympanic cavity

Stage Ia: Cholesteatoma confined to the anterior half of the tympanic cavity

Stage Ib: Cholesteatoma confined to the posterior half of the tympanic cavity

Stage Ic: Cholesteatoma involving both of sides of the tympanic cavity

Stage II: Cholesteatoma involving two or more sites

Correspondence: Yutaka Yamamoto, MD, 3-25-8 Nishi-shinbashi, Minato-ku, Tokyo 105-8461, Japan.

E-mail: entyama@jikei.ac.jp

*Cholesteatoma and Ear Surgery – An Update 2017, pp. 305 -306*

*Edited by Matthew Yung*

*2017 © Kugler Publications, Amsterdam, The Netherlands*

Stage III: Cholesteatoma with intratemporal complications and pathologic conditions

Stage IV: Cholesteatoma with intracranial complications

### **3. Result 1: cholesteatoma secondary to a pars tensa perforation**

Twenty-three ears of 23 patients with cholesteatoma secondary to a pars tensa perforation were identified. Incidence of the disease was 4.1% of all of the cholesteatoma cases or 5.2% of all of the acquired cholesteatoma cases. One ear was classified for Stage Ia, nine ears for Ib, 12 ears for II and one ear for III. Characteristics of the disease were represented as follows: high incidence in elder women, low rate of undeveloped mastoid air cell system, severe destruction of the stapes, and complex extension pathway.

### **4. Result 2: congenital cholesteatoma**

Seventy-one ears of 599 ears were diagnosed for congenital cholesteatoma and 37 ears of 71 have been studied. Six ears were classified for Stage Ia, 11 ears for Ib, one ear for Ic, 17 ears for II and two ears for III. Concerning the pathology of stapes in Stage I, the missing rate of stapes superstructure was 0%, 54.5% and 100% in Stage Ia, Ib and Ic, respectively.

### **5. Conclusions**

The pathogenesis of cholesteatoma secondary to a pars tensa perforation is very different from that of other types of cholesteatoma. This disease should be clearly categorized as a different type of cholesteatoma and we need to recognize the nature and behavior of this disease.

Congenital cholesteatoma which was limited in tympanic cavity was different in stapes status by the part of existence of cholesteatoma. Especially in this study, Stage Ib was most common in Stage I.

Our staging system which is classified from point of the cholesteatoma extent is simple and useful. Additional storage of the data and detailed analysis by the multi-center study should be continued.

# INFLAMMATORY, INVASIVE AND NEOPLASTIC FEATURES OF PRIMARY AND SECONDARY CHOLESTEATOMAS: IMMUNOHISTOCHEMICAL AND HISTOLOGICAL FINDINGS

Nadir Yildirim<sup>1</sup>, Ayşe Nur Deger<sup>1</sup>, Onur Erdogan<sup>1</sup>, Semra Külekci<sup>2</sup>

<sup>1</sup>Dumlupınar University Medical Faculty Department of ORL-HNS, Kütahya, Turkey; <sup>2</sup>Fatih Sultan Mehmet Eğitim ve Araştırma Hastanesi Department of ORL-HNS, Istanbul, Turkey

## Abstract

**Objective:** Etiopathogenesis of middle ear cholesteatoma has not been wholly understood. Acquired cholesteatomas are conventionally classified into epitympanic/primary acquired cholesteatoma (PAC) and mesotympanic/secondary acquired cholesteatoma (SAC) subtypes. With our study, we aimed to investigate the expression of multiple inflammatory/invasive and neoplastic markers in cholesteatomas using immunohistochemistry (IHC) and hematoxylin-eosin (H&E) staining with special reference to the PAC, and SAC, through which we expect to shed light over the differences in the biological behaviors and pathogenesis of these sub-types.

**Material and Method:** We statistically compared 74 (33 primary, 41 secondary) cholesteatoma matrices and normal (control) skin samples harvested from operated cholesteatoma patients for ten different markers within and between the subgroups using IHC and H&E staining. The evaluating pathologist was blinded.

**Results:** Statistically, staining scores for IHC markers of Ki67, proliferating cell nuclear antigen (PCNA), keratinocyte growth factor (KGF), fibronectin (FN), interleukin1 $\alpha$  (IL-1 $\alpha$ ), tumor necrosis factor- $\alpha$  (TNF- $\alpha$ ); and staining with H&E for vascularization and lymphocyte numbers were significantly higher in cholesteatomatous tissues than the control samples in both subgroups except for collagen type IV and collagen type VII, for which the scores were lower and non-different statistically in cholesteatomas comparing to control materials respectively.

However, no significant differences were found between the subgroups.

**Discussion and Conclusion:** There are publications that suggest PAC and SAC are different clinical entities both in terms of etiopathogenesis and biological behavior. However, our results indicate that acquired cholesteatoma is pathologically the same invasive, inflammatory and hyperproliferative disease, irrespective of its location and etiopathology. Normal expression of collagen type VII in cholesteatoma might be related to its undermost location in the basal membrane where epithelium and subepithelial connective tissue interface, which would indicate the limit of the pathology. Reduced collagen Type IV expression is possibly related to its recidivistic character. This divergent role of two basal membrane collagens in cholesteatoma should be further studied.

## 1. Introduction

Middle ear cholesteatomas have various classifications. Widely accepted are ‘congenital’ and ‘acquired’ according to the time and mode of occurrence; and acquired cholesteatomas are conventionally divided into attic or primary and tensa or secondary by their origin of tympanic membrane (TM) portion.<sup>1,2</sup> Attic cholesteatomas (pars flaccida cholesteatomas) are also referred to as primary acquired cholesteatoma (PAC) and pars tensa cholesteatomas as

Correspondence: Prof. Dr. Nadir Yildirim, DPU Evliya Çelebi EAH, Ek Bina, KBB-BBC Bölümü, Saray Mah. Fatih Sultan Mehmet Bulvarı, 43100, Kütahya, Turkey.  
E-mail: nadir\_yildirim@yahoo.com

*Cholesteatoma and Ear Surgery – An Update 2017, pp. 307 -314*

*Edited by Matthew Yung*

*2017 © Kugler Publications, Amsterdam, The Netherlands*



secondary acquired cholesteatoma (SAC).<sup>1</sup> Current etiopathogenetic theories of cholesteatoma are (a) epithelium invasion or invagination of the TM or external ear canal (EAC) epithelium into the middle ear; (b) invasive hyperplasia of the basal layer of the TM epithelium; and (c) invagination or retraction pocket formation of TM into the middle ear due to chronic Eustachian tube dysfunction.<sup>2,3</sup> Of these possible mechanisms, retraction and papillary proliferation in PAC, invasion with retraction and adhesion of the whole or part of pars tensa in SAC stand out.<sup>2-4</sup>

Although they follow somewhat divergent courses of growth, no difference of complications and clinics at the advanced stage of the disease between both subtypes of the pathology has been found. Furthermore, some cholesteatomas carry the future of both types and cannot be categorized under either of the subgroups.<sup>5,6</sup> Retraction pocket cholesteatomas also tend to be taken as separate subgroups by some authors.

PAC is known with its more insidious course, less infectious findings, intact pars tensa and more association with complications.<sup>5,7</sup> On the other hand, SAC is frequently associated with rather recurring infections, purulent drainage and intensive granulation tissue formation.<sup>4,6</sup> Despite the possible differences in the pathogenesis, both sub-types also display some common biological characteristics, which are epithelial hyperproliferation, migration, disordered cellular differentiation and recidivism.<sup>8,9</sup> In order to solve this biological puzzle, clinical, animal experimental, cell and tissue culture studies have been conducted through various methods including immunohistochemistry and polymerase chain reaction (PCR). In these studies, especially the questions of how the keratocytes, prominent cells in the cholesteatoma pathology, can uncontrollably proliferate, how the polyps and granulation tissues generate, what are the biological bases of destructive and recurrent nature of the disease, have been addressed.<sup>4</sup>

In the immunohistochemical studies conducted in this context, numerous marker antigens have been used. Of those, the immunohistochemical markers of KGF, an inflammatory cytokine and a growth factor;<sup>10</sup> PCNA, an essential factor for cell replication;<sup>9</sup> Ki67, a marker of neoplastic cell proliferation;<sup>11,12</sup> basal membrane proteins of collagen type IV, VII and FN; inflammatory cytokines of IL-1 $\alpha$  and TNF- $\alpha$ <sup>11,13</sup> can be counted. In these studies, expressions of the above markers in cholesteatoma matrices and perimatrices have been compared with their expression in the normal skin tissue.

In our study, we compared cholesteatoma matrices in general and in both sub-types with adjacent normal skin in terms of intensity of expression for the aforementioned eight IHC markers as well as the vascularization and lymphocyte infiltration in the perimatrix on the H&E-stained slides.

## 2. Materials and Methods

In the years of 2014 and 2015, we used the cholesteatoma matrix and perimatrix granulomatous materials removed from 74 patients for our study, and normal skin materials at the diameters of 1 x 2-3 mm harvested during the meatoplasties from the same patients as control materials and these were sent for histopathologic examination through H&E staining and IHC methods. The cholesteatoma tissues that typically originate from the pars flaccida of the TM are classified as PAC, and the samples taken from the pars tensa cholesteatomas with intact pars flaccida were classified under SAC. The patients whose TM retraction or adhesions had not yet become cholesteatoma, those patients whose cholesteatoma involved both pars tensa and flaccida or could not be differentiated either as PAC or SAC and the patients with unequivocal retraction pocket cholesteatomas have been excluded from the study. The pathologists who studied the pathologic samples were blinded. Informed consent from the partaking patients and DPU Medical Faculty Clinical Studies Ethics Committee approval has been obtained.

For the IHC and H&E staining for microscopic examination, cholesteatoma tissue samples were used along with perimatrix granulomatous materials and external ear canal skin samples, harvested from each patient fixed with formalin. Following 24-hour fixation, tissue follow-up and paraffin embedding procedures were completed. Tissue samples were sectioned at five  $\mu$ -thick sections for H&E staining and then four  $\mu$ -thick serial sections were

obtained for IHC staining. The antibodies used as markers were:

- Ki67 primary antibody
- PCNA primary antibody
- KGF antibody
- Collagen IV primary antibody
- Collagen VII primary antibody
- Fibronectin primary antibody
- TNF- $\alpha$  primary antibody
- IL1-  $\alpha$  primary antibody

Before the histologic examination of IHC stained sections, general deparaffinization and dehydration in the order of with absolute alcohol, 96% alcohol, 90 % alcohol and 70% alcohol was done. For the retrieval of the antibody, EDTA buffer (PH8) in 1/10 dilution was used.

Primary antibody for Ki67, PCNA, KGF, collagen IV, collagen VII, FN (for the basal membrane and perimatrix samples), TNF- $\alpha$  primary antibody, IL1- $\alpha$  primary antibody were applied for one hour. For the IHC staining, 'Ultravision Quanto Detection HRP polymer system' kit was applied for one hour. Light microscope (Olympus CX41) was used for histomorphological and IHC examinations and photography.

For the PCNA and Ki67 evaluation, positively stained cells were counted in the epithelium and stroma in randomly selected three fields (X400 HPF). Nuclear staining was taken as criteria of positivity. For the each tissue sample (cholesteatoma and skin), PCNA and Ki67-positive cell proportions were assessed in percentages. For the KGF evaluation, positively reacted fibroblasts were counted in the cholesteatoma perimatrix and skin at 0.239 mm<sup>2</sup> [X400 HPF (high providing field area)] area. In the collagen type IV and collagen type VII evaluation, three randomly selected areas were examined (3HPF X400).

According to the intensity of positive reactions in the basal membrane, the cases were classified into four groups:

- 0 No reaction in the basal membrane
- 1 Focal basal membrane reaction
- 2 Moderate positive reaction
- 3 Diffuse positive reaction

Basal membrane in the sub-epithelium of the blood vessels in the cholesteatoma perimatrix staining was taken as positive. The control skin basal membranes were also diffusely positively stained. Basal membrane fibronectin staining was examined likewise. Cholesteatoma epithelium basal membranes were diffusely positively stained at some places. Cholesteatoma perimatrices were intensely stained in the stroma. Basal membranes in the control skin samples were not stained. In the stromal fibroblasts of the skin samples, few cells were positively stained.

Vascular structures and lymphocytes were counted on H&E stained slides at three randomly selected areas of 0.239 mm<sup>2</sup> [X400 HPF (high providing field area)] in both cholesteatoma perimatrices and control skin samples.

We used IBM SPSS Statistics 22.0 program in the statistical analysis. In the comparison of descriptive and parametric variables and arithmetic averages (mean, standard deviation) in both subgroups, the Mann-Whitney U-Test was used. We used the Wilcoxon sign test to statistically compare cholesteatoma and control materials. Significance level was taken as  $p < 0.05$ .

### 3. Results

We conducted the study in 33 PAC and 41 SAC (total: 74) patients. The ages of the patients were between eight and 65, and mean and median ages were 39.5 and 42.5 in the PAC group; and 41.87 and 45.5 in the SAC group

respectively. The number of pediatric patients was relatively small (two patients in the SAC group and six patients in the PAC group) and removing their parameters did not alter the overall statistical results. The staining intensity scores for the study and control materials assessed by the aforementioned methods have been recorded. Grouping cholesteatomas under PAC or SAC were done according to the clinical and operative findings (some patients were excluded on the ground of above given exclusion criteria). The cumulative scores for each marker are statistically compared between the study (cholesteatoma) and control (skin) materials within the subgroups as to compute significance scores. Then, the significance scores for both subgroups have been statistically compared with each other.

In both groups, staining scores for Ki-67 (%), PCNA (%), KGF and FN [for both matrix and perimatrix], TNF- $\alpha$ , IL1- $\alpha$  and vascular structure and lymphocyte counts (in H&E stained slides) have been found significantly higher in the study materials (cholesteatoma matrix and/or perimatrix) than the control materials ( $p > 0.001$ ). However, for the collagen type IV the staining score was lower in cholesteatomas than the control materials ( $p > 0.001$ ), and non-different for collagen type VII, for which the  $p$  score was  $<0.05$ . However, the scores of significance have not been found different at statistically significant level between the subgroups for any of the studied markers (Table 1).

Table 1. Statistical analysis of PAC and SAC staining for immunohistochemical markers and H&E for lymphocyte infiltration (Lymph) and vascularization (Vas).

cholesteatoma		Primary acquired cholesteatoma			Secondary acquired			P
		n	Average (SD)	Median (Min-Max)	n	Average (SD)	Median (Min-Max)	
Ki-67 (%)	Cholesteatoma <sup>#</sup>	33	25,04 $\pm$ 10,32	22,92(10,71-46,48)	41	27,35 $\pm$ 14,11	23,52(10-62,5)	0,802
	Control <sup>#</sup>	33			41	12,37 $\pm$ 5,74	11,42(3,1-32,93)	0,561
PCNA (%)	Cholesteatoma <sup>+</sup>	33	11,53 $\pm$ 4,58	11(6,25-29)	41	41,8 $\pm$ 15,46	41,96(12,44-73,81)	0,596
	Control <sup>+</sup>	32	43,69 $\pm$ 14,87	42,3(22-84,21)				
FN	Cholesteatoma <sup>#</sup>	33	24,47 $\pm$ 8,86	24,33(8,7-45)	41	25,44 $\pm$ 11,83	25(5-51,28)	0,700
	Control <sup>#</sup>	33	44,58 $\pm$ 24,61	40(6-94)	41	41,29 $\pm$ 28,72	38(8-132)	0,408
FN- BM	Cholesteatoma <sup>#</sup>	33	6 $\pm$ 10,11	2(0-46)	41	5 $\pm$ 6,56	3(0-25)	0,903
	Control <sup>#</sup>	33	2 $\pm$ 0,9	2(0-3)	41	1,73 $\pm$ 0,95	2(0-3)	0,225
Collagen IV	Cholesteatoma <sup>#</sup>	33	0,12 $\pm$ 0,33	0(0-1)	41	0,02 $\pm$ 0,16	0(0-1)	0,101
	Control <sup>#</sup>	33	1,52 $\pm$ 1,06	2(0-3)	41	1,51 $\pm$ 0,87	2(0-3)	0,899
KGF	Cholesteatoma <sup>+</sup>	33	2,88 $\pm$ 0,33	3(2-3)	41	2,78 $\pm$ 0,52	3(1-3)	0,509
	Control <sup>#</sup>	33	44,03 $\pm$ 14,25	45(18-75)	41	45,15 $\pm$ 19,63	43(13-93)	0,785
H&E Vas	Cholesteatoma <sup>#</sup>	33	11,15 $\pm$ 7,09	8(2-32)	41	12,46 $\pm$ 6,6	11(3-28)	0,261
	Control <sup>#</sup>	33	22,69 $\pm$ 8,97	20(10-45)	41	19,88 $\pm$ 8,72	20(3-43)	0,218
H&E Lymph	Cholesteatoma <sup>#</sup>	33	7 $\pm$ 5,19	6(2-24)	41	6,34 $\pm$ 3,94	5(1-20)	0,886
	Control <sup>#</sup>	33	42,47 $\pm$ 22,52	42,5(12-88)	41	42,02 $\pm$ 20,53	40(10-86)	0,978
IL	Cholesteatoma <sup>#</sup>	33	2,9 $\pm$ 5,82	0(0-30)	41	2,46 $\pm$ 2,81	2(0-10)	0,573
	Control <sup>#</sup>	33	11,59 $\pm$ 10,77	8(0-45)	41	10,59 $\pm$ 9	8(0-40)	0,955
TNF	Cholesteatoma <sup>#</sup>	33	0,82 $\pm$ 2,2	0(0-12)	41	0,44 $\pm$ 1,21	0(0-5)	0,323
	Control <sup>#</sup>	33	15,03 $\pm$ 11,33	13(2-45)	41	11,78 $\pm$ 7,92	9(3-35)	0,184
Collagen VII	Cholesteatoma <sup>#</sup>	33	1,84 $\pm$ 3,39	0(0-15)	41	1,32 $\pm$ 1,84	0(0-7)	0,975
	Control <sup>#</sup>	33	1,22 $\pm$ 1,04	1(0-3)	41	1,34 $\pm$ 1,11	1(0-3)	0,661
	Control <sup>#</sup>	33	1,25 $\pm$ 1,08	2(0-3)	41	1,37 $\pm$ 1,18	2(0-3)	0,637

<sup>+</sup> Student *t* test; <sup>#</sup> Mann-Whitney *U* test.

#### 4. Discussion

It has been suggested that middle ear cholesteatoma, with the characteristics of non-coordinated proliferation, alteration in differentiation, aggressiveness and recidivism of especially the keratinocytes of the squamous epithelium, mimics a low-grade neoplasm.<sup>11,14</sup> Ki-67, an active proliferation marker, widely used in the assessment of tumor proliferation rate, has been found at moderately high level in cholesteatoma.<sup>11,14</sup> This finding has been confirmed by our findings. However, the significance level of this expression has not been high enough to interpret cholesteatoma as a neoplastic disease.

Proliferating cell nuclear antigen (PCNA), is a protein the level of which indicates the rate of cellular proliferation and in this context of the proliferation capacity of the keratinocytes.<sup>15-17</sup> In cholesteatoma, the rate of the cells with PCNA expression has been found to be significantly higher than in the normal EAC skin.<sup>16-18</sup> Moreover, PCNA is suggested to be used as a marker in cholesteatoma classification, recurrence risk and destruction degree.<sup>16</sup> Our study results also showed high PCNA expression in cholesteatoma without any difference between subgroups.

Keratinocyte growth factor, an inflammatory cytokine, is synthesized and secreted in the epithelial stromal cells.<sup>15,19,20</sup> KGF has been demonstrated to increase along with IL1- $\alpha$ , also an inflammatory cytokine that causes epidermal proliferation and deregulation differentiation.<sup>14,19-21</sup> In immunohistochemical and PCR studies, KGF has been found highly markedly expressed in cholesteatoma matrix in comparison with normal skin.<sup>10,14</sup> Our results also confirmed the results of these studies and the role of inflammation in the etiopathogenesis of cholesteatoma. Tumor necrosis factor alpha (TNF- $\alpha$ ), another pro-inflammatory cytokine, has been shown to increase in cholesteatoma,<sup>22</sup> as the results of our study also indicated.

The basal membrane constitutes the interface between the squamous epithelium and subepithelial connective tissue. It contains proteoglycans, glycoproteins, collagens, and adhesion molecules such as laminine and fibronectin.<sup>23,24</sup> Type-IV collagen is a non-fibrillary collagen in the squamous epithelium located also in the dermal-epidermal junction (basal membrane) that constitutes the structural scaffold in the extracellular matrix. It has been demonstrated that this collagen is discontinuous focally and their immunoreactivity is reduced in cholesteatoma cases that infiltrate underlying connective tissue and with severe inflammation.<sup>3</sup> Our study results also showed that in both cholesteatoma sub-groups (PAC and SAC), immunoreactivity scores of collagen type IV were reduced in comparison to control materials as to indicate discontinuity of the basal membrane, which is most likely connected with the invasive character of the disease. On the other hand, the other collagen we studied, collagen type VII, which is located at the undermost layer of the basal membrane and functions as anchoring fibril,<sup>25</sup> has been found unaltered when compared with normal skin in contrast to the findings of the some other studies.<sup>9,26</sup> This is another finding as to refute the neoplastic etiopathogenesis theory of cholesteatoma and also indicates that discontinuity and distribution alterations in the basal membrane do not progress deeper than this level, which should be further studied.

Fibronectin, a non-collagen glycoprotein, plays a role in the wound healing by inducing invasion of platelets that leads to migration and adhesion of neutrophils, monocytes, fibroblasts and epithelial cells and formation of granulation tissues.<sup>27</sup> It has been assessed that this molecule has markedly increased immunoreactivity at the dermal-epidermal junction of the cholesteatoma matrix in comparison to the normal skin. This appears to be related to the recidivism or 'non-healing wound' nature of the cholesteatoma.<sup>9</sup> The results of our study also indicate that FN is increased in both cholesteatoma matrix and perimatrix.

Although there is a plethora of reports over the destructiveness of cholesteatoma and its mechanisms, no biologically based distinction has been made between its sub-groups in this respect. More aggressive and destructive course of PAC than SAC is most likely related to its location and different invasion pattern.<sup>5,7</sup> Inflammatory changes in the cholesteatoma perimatrix with increased angiogenesis and lymphocyte infiltration as to result in granuloma formation is well-known<sup>28,29</sup> and confirmed by the results of our study.

## 5. Conclusion

Although the immunohistochemical features of cholesteatoma have been studied to compare congenital and acquired and adult and paediatric cholesteatomas, we have not been able to find any publication comparing the immunohistochemical reactivity of PAC and SAC. The results of the present study indicate that inflammatory stimuli in both subgroups of cholesteatoma play an important role in the induction of the disease, most likely through cytokines. On the other hand, cholesteatoma facilitates associated chronic inflammation. Thus, it is possible to state that there is a positive feed-back between these two clinical entities. The results of this study suggest that PAC and SAC subtypes pretty much reflect 'different locations' rather than 'different forms' of cholesteatoma. Another conclusion of this study is apparent non-involvement of collagen type VII in cholesteatoma pathology in contrast to reduction in the level of other basal membrane collagen, collagen type IV. This is a finding that requires further, possibly ultrastructural studies.

## References

1. Meyerhoff WL, Truelson J. Cholesteatoma staging. *Laryngoscope* 1986;96:935-939.
2. Tos M, Lau T. Late results of surgery in different cholesteatoma types. *ORL J Otorhinolaryngol Relat Spec* 1989;51:33-49.
3. Sudhoff H, Tos M. Pathogenesis of attic cholesteatoma: clinical and immunohistochemical support for combination of retraction theory and proliferation theory. *Am J Otol* 2000;21:786-792.
4. Olszewska E, Wagner M, Bernal-Sprekelsen M, et al. Etiopathogenesis of cholesteatoma. *Eur Arch Otorhinolaryngol* 2004;261:6-24.
5. Vikram BV, Udayashankar SG, Naseeruddin K, et al. Complications in primary and secondary acquired cholesteatoma: a prospective comparative study of 62 ears. *Am J Otolaryngol Head Neck Med Surg* 2008;29:1-6.
6. Yamamoto Y1, Takahashi K, Morita Y, Takahashi S. Clinical behaviour and pathogenesis of secondary acquired cholesteatoma with a tympanic membrane perforation. *Acta Otolaryngol* 2013;133:1035-1039.
7. Yıldırım N, Külekçi S, Sivas Zeybek Z, Kucur C. Comparison of primary and secondary cholesteatomas in terms of ossicular destruction and complications *Turk Arch Otolaryngol* 2014;52:121-125.
8. Tos M. *Manual of middle ear surgery*. Stuttgart, New York: Thieme 1993.
9. Sudhoff H, Bujía J, Borkowshi G, et al. Basement membrane in middle ear cholesteatoma. Immunohistochemical and ultrastructural observations. *Ann Otol Rhinol Laryngol* 1996;105:804-810.
10. Ishibashi T, Shinogami M, Kaga K, Fukaya T. Keratinocyte growth factor and receptor mRNA expression in cholesteatoma of the middle ear. *Acta Otolaryngol* 1997;117:714-718.
11. Albino AP, Kimmelman CP, Parisier SC. Cholesteatoma: a molecular and cellular puzzle. *Am J Otol* 1998;19:7-19.
12. Mallet Y, Nouwen J, Lecomte-Houcke M, Desautly A. Aggressiveness and quantification of epithelial proliferation of middle ear cholesteatoma by MIB 1. *Laryngoscope* 2003;113:328-331.
13. Dornelles C, da Costa SS, Meurer L, et al. Comparison of acquired cholesteatoma between pediatric and adult patients. *Eur Arch Otorhinolaryngol* 2009;266:1553-1561.
14. Ferlito A. A review of the definition, terminology and pathology of aural cholesteatoma. *J Laryngol Otol* 1993;107:483-488.
15. Shieh TJ, Ho KY, Kuo WR, et al. Evaluation of proliferative activity in middle ear cholesteatoma using proliferating cell nuclear antigen. *Kaohsiung J Med Sci* 1999;15:468-474.
16. Liu W, Ren H, Ren J, et al. The role of EGFR/PI3K/Akt/cyclinD1 signalling pathway in acquired middle ear cholesteatoma. *Mediators Inflamm* 2013;651207.
17. Sikka K, Sharma SC, Thakar A, Dattagupta S. Evaluation of epithelial proliferation in paediatric and adult cholesteatomas using the Ki-67 proliferation marker. *J Laryngol Otol* 2012;126:460-463.
18. Park K, Park HJ, Chun YM. Immunohistochemical study on proliferative activity of experimental cholesteatoma. *Eur Arch Otorhinolaryngol* 2001; 258:101-105 .

19. Tanaka Y, Kojima H, Miyazaki H, Koga T, Moriyama H. Roles of cytokines and cell cycle regulating substances in proliferation of cholesteatoma epithelium. *Laryngoscope* 1999;109:1102-1107 .
20. Akimoto R, Pawankar R, Yagi T, Baba S. Acquired and congenital cholesteatoma: determination of tumor necrosis factor- $\alpha$ , intercellular adhesion molecule-1, interleukin-1- $\alpha$  and lymphocyte functional antigen-1 in the inflammatory process. *ORL J Otorhinolaryngol Relat Spec* 2000;62:257-265.
21. Finch PW, Rubin JS, Miki T, Ron D, Aaronson SA. Human KGF is FGF related with properties of a paracrine effector of epithelial cell growth. *Science* 1989;245(4919):752-755.
22. Raffa S, Leone L, Scrofani C, et al. Cholesteatoma-associated fibroblasts modulate epithelial growth and differentiation through KGF/FGF7 secretion. *Histochem Cell Biol* 2012;138:251-269.
23. Chan LS. Human skin basement membrane in health and in autoimmune diseases. *Front Biosci* 1997;15:343-352.
24. Stark T, Sudhoff H, Fisseler-Eckhoff A, et al. Alterations of basement membrane in middle ear cholesteatoma. In: Sanna M (ed) Fifth international conference on cholesteatoma and mastoid surgery, pp. 238-247. CIC Edizioni Internazionali, Rome 1997.
25. Eady RA. The basement membrane. Interface between the epithelium and the dermis: structural features. *Arch Dermatol* 1988;124:709-712.
26. Stammberger M, Bujía J, Schulz P. Correlation of vascular morphology with clinical types in cholesteatoma of the middle ear. *Am J Otol* 1994;15:380-382.
27. Sudhoff H, Dazert S, Gonzales AM, et al. Angiogenesis and angiogenic growth factors in middle ear cholesteatoma. *Am J Otol* 2000;21:793-798.
28. Stammberger M, Bujía J, Schulz P. Correlation of vascular morphology with clinical types in cholesteatoma of the middle ear. *Am J Otol* 1994;15:380-382.
29. Sudhoff H, Dazert S, Gonzales AM, et al. Angiogenesis and angiogenic growth factors in middle ear cholesteatoma. *Am J Otol* 2000;21:793-798.





# SIMPLE UNDERLAY MYRINGOPLASTY

Yu Yuasa

*Sendai Ear Surgicenter*

## 1. Introduction

Simple underlay myringoplasty (SUM) has been widely performed over the last 27 years in Japan as a less invasive procedure of myringoplasty than conventional methods. SUM has been introduced into not only this conference but also AAO-HNS (American Academy of Otolaryngology – Head and Neck Surgery) for the last ten years annually as a lecture of instruction courses. Additionally, several articles in English regarding the detail of this method were published.<sup>1,2</sup> Therefore, SUM has been gradually recognized in the world.

## 2. Surgical procedures

A transcanal approach is applied. No skin incision is necessary except to harvest subcutaneous connective tissue for the graft from the retro-auricular region. After the topical anesthesia of the tympanic membrane, the perforation margin is removed for both the debridement and the vascularization to the graft (Fig. 1A). Calcified tissue around the perforation is also removed. When the perforation edge involves the malleus handle, the mucosa behind the handle is removed. The pressed graft is inserted into the tympanic cavity through the perforation, and then the graft is elevated to touch the perforation edge. The graft is fixed to the tympanic membrane with a little fibrin glue (Fig. 1B). Packing is not necessary either in the tympanic cavity or in the external auditory canal. The surgery is performed under local anesthesia except in cases with children because thirty minutes is sufficient to accomplish the surgery for one ear by this method. For the persistent perforation after this method, re-closure is attempted in the outpatient clinic by the same procedure using frozen autologous tissue which has been harvested in the initial surgery. This method is generally performed through an ear speculum under a microscope. Recently an endoscope is sometimes applied for ear surgeries in the transcanal approach. Although the endoscope is also

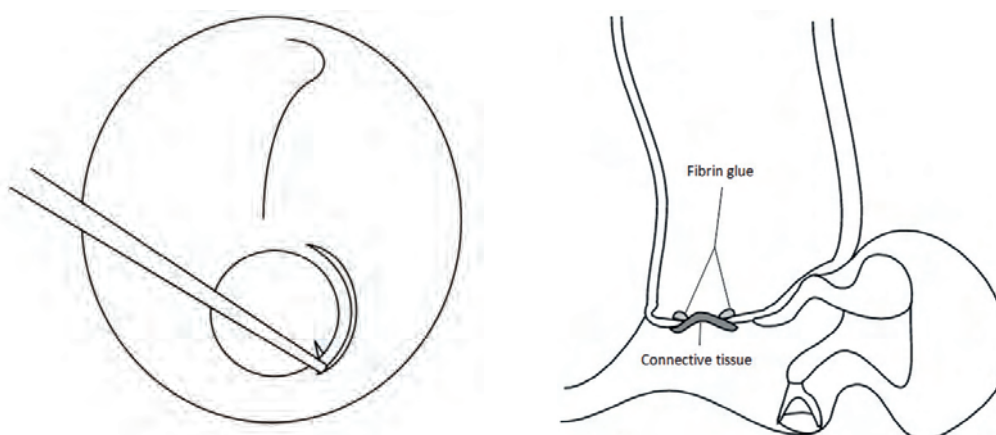


Fig. 1. Scheme of surgical procedures. (A) Remove the perforation margin. (B) Graft by underlay method.

Correspondence: Yu Yuasa, MD, 10-12-1-2, Shougen, Izumi-ku, Sendai 9813132, Japan.  
E-mail: [yyuasa@sendai-surg.gr.jp](mailto:yyuasa@sendai-surg.gr.jp)

*Cholesteatoma and Ear Surgery – An Update 2017, pp. 315 -318*

*Edited by Matthew Yung*

*2017 © Kugler Publications, Amsterdam, The Netherlands*

applied for SUM method particularly for the case that the anterior part of the perforation edge cannot be treated under the microscope due to a protrusion of the anterior region of the external auditory canal, the anesthesia of the external ear canal skin by an infiltration of 1% lidocaine is necessary because the scope and other instruments sometimes touch the narrow ear canal.

### 3. Results

The closure rate of the perforation was 478/621 (77.0%). Overall success rate after the re-closure for the persistent perforation at the outpatient clinic was 595/621 (95.8%). There was no significant difference of the success rate among any size of the perforation or any frequency of otorrhea. The postoperative air-bone gap less than or equal to ten dB was found in cases of 493/610 (80.8%). There was no serious complication such as a postoperative hearing deterioration more than ten dB.

### 4. Indications

SUM is indicated for the case as follows: (1) Any size of the central dry perforation; (2) No pathology in the tympanic cavity; (3) A sufficient hearing gain after the preoperative patch test using thin wet cotton. The case of cholesteatoma or adhesive otitis media is contraindicated. Because the postoperative hearing deterioration is extremely rare, SUM is also indicated for cases with the only hearing ear or with the same day surgery for bilateral diseases.<sup>2-3</sup>

### 5. Modification to tympanoplasty

Although SUM is a good indication to repair the tympanic membrane perforation, the closure rate at the initial surgery is not high comparing to conventional methods. Modified procedures of SUM as shown in Figure 2 have been introduced to increase the closure rate. The anterior part of the graft is set under the remnant tympanic membrane and the posterior part is set between the meatal bone and the tympanomeatal flap. The graft is fixed by fibrin glue as same as the original SUM method. The closure rate of the perforation after these modified procedures at the initial surgery increased to 385/444 (86.7%).

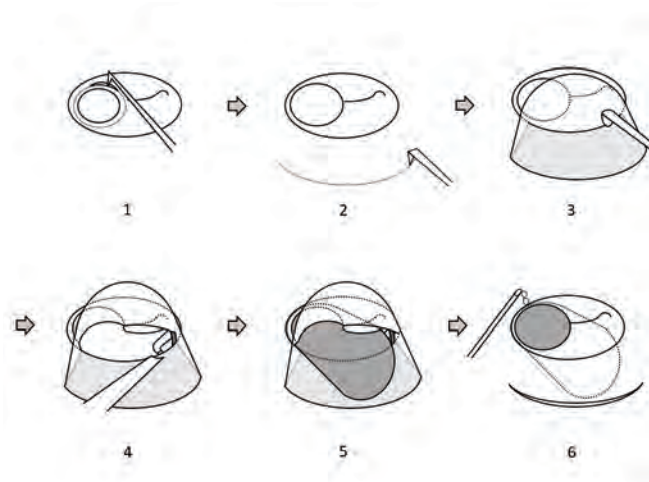


Fig. 2. Scheme of modified procedures. 1. Remove the perforation margin. 2. Cut the external meatal skin. 3. Elevate the tympanomeatal flap. 4. Cut a part of the external meatal bone using a small chisel. 5. Set the graft by underlay technique. 6. Fix the graft by fibrin glue.

---


**References**

1. Sakagami M, Yuasa R, Yuasa Y. Simple underlay myringoplasty. *J Laryngol Otol* 2007;121:840-847.
2. Yuasa Y, Yuasa R. Postoperative results of simple underlay myringoplasty in better hearing ears. *Acta Otolaryngol* 2009;128:139-143.
3. Sakagami M, Mishiro Y, Tsuzuki K, Seo T, Sone M. Bilateral same day surgery for bilateral perforated chronic otitis media. *Auris Nasus Larynx* 2000;27:35-38.





ISBN 978-90-6299-263-8



9 789062 992638 >